

Review

CORRELATION BETWEEN ORAL SURGERY AND MANDIBULAR FRACTURES IN OSTEOPOROSIS PATIENTS

A. Rosa^{1*}, A. Pujia², S. Casella³ and C. Arcuri³

¹Materials for Health, Environment and Energy, Department of Chemical Science and Technologies, Dentistry, University of Tor Vergata, Rome, Italy;

²Department of Biomedicine and Prevention, University of Rome Tor Vergata, Rome, Italy;

³Department of Clinical Sciences and Translational Medicine, University of Rome Tor Vergata, Rome, Italy

*Corresponding author

Alessio Rosa, DDS

Materials for Health Environment and Energy,
Department of Chemical Science and Technologies,
University of Tor Vergata,
Via Montpellier 1,
00133 Rome, Italy
e-mail: alessio.rosa.21@alumni.uniroma2.eu

ABSTRACT

The purpose of this study was to investigate how osteoporosis can adversely affect one of the rarest, but now very common complications of surgery on the posterior jaw: the mandibular fracture. The term "mandibular fracture" refers to a broken jaw (mandible), while fractures of the upper jaw are sometimes called "jaw fractures", but are usually considered facial fractures (maxillofacial fracture). The fracture usually causes pain and swelling in the affected area and a feeling of misalignment of the teeth. Often, there is a narrowing of the opening of the mouth and a lateral displacement when opening or closing. The authors examined the literature to provide the scientific community with an etiological overview underlying this complication. Our analysis shows that although there are few articles in the indexed literature, this complication is quite common and often linked to the operator's inexperience but also to the systemic pathological influence of osteoporosis. For this reason, it would seem appropriate to prevent everything by using surgical protocols that reduce jaw fractures by assessing the risk that the disease may involve.

KEYWORDS: *third molar, mandibular fracture, oral surgery, impacted tooth, angle mandibular*

INTRODUCTION

The mandible is the only movable bone in the skull. It is of the dense and hard type and constitutes the lower third of the facial skeleton. Surgical extraction of the lower third molars is one of the most common procedures in oral surgery (1). This surgical procedure may be accompanied by intra- and post-operative complications such as pain, trismus, bleeding, infection, edema, lesions of the inferior alveolar nerve, displacement of teeth into adjacent spaces and mandibular fractures (Fig. 1).

Received: 18 February 2023
Accepted: 25 March 2023

Copyright © by LAB srl 2023 ISSN 2975-1276

This publication and/or article is for individual use only and may not be further reproduced without written permission from the copyright holder. Unauthorized reproduction may result in financial and other penalties. Disclosure: All authors report no conflicts of interest relevant to this article.

The signs and symptoms of a mandibular fracture
Trismus
Bleeding from lacerated gingival or mucosal tissue
Echymosis/hematoma (at the fracture site or the sublingual space)
Loose, fractured, or displaced teeth
Palpable or visible "step" in the dental arch
Inability to chew or subjective (or obvious) altered bite
Paresthesia of the lip/chin
Lack of motion of the mandibular condyles with palpation through the external auditory canal
<i>From Viozzi CF. Maxillofacial and mandibular fractures in sports. Clin Sports Med 2017;36(2):355-68.</i>

Fig. 1. The signs and symptoms of mandibular fracture.

Osteoporosis is a widespread metabolic disease affecting bone and is characterized by bone density collapse along with microarchitectural failure, leading to bone fragility and exposure to fracture risk. It affects one in three women and one in five men over 50. The female gender demonstrates declining bone loss as early as menopause, predominantly in trabecular bone, followed by slower trabecular and cortical bone loss. The mandible has some weak areas that are less resistant to fractures, such as the mandibular angle, the condyle, the mandibular symphysis, the body, and the coronoid process. The bony anatomy of the gonial angle, with its location between the ascending ramus and the mandibular body, as well as its association with the impaction of the lower third molar, makes it one of the most frequent fracture sites (40%). It is the most frequently fractured bone in the maxillofacial skeleton due to its prominence (2, 3). The jaw commonly fractures in the angle, condyle, and chin region.(4). The horizontal fracture of the mandible (Fig. 2) is very rare, and only a few cases have been reported in the literature (5).

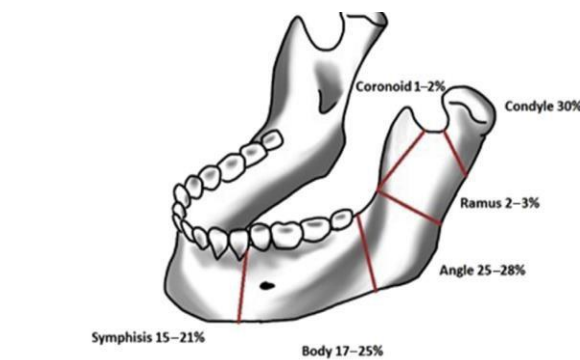


Fig. 2. Distribution of mandibular fractures (Mooney S, Gulati RD, Yusupov S, Butts SC. Mandibular Condylar fractures. *Facial Plast Surg Clin North Am.* 2022 Feb;30(1):85-98. doi: 10.1016/j.fsc.2021.08.007. PMID: 34809889).

The estimated incidence of mandibular fracture is 11.5 cases per 10,000 individuals (6). The mandibular angle is a frequent fracture site, accounting for 25-33% of all mandibular fractures.

In the literature, several variables influence the fracture: for example, the anatomical bone component, the masticatory forces, and the different dental occlusal loads.

A not very recent but quite simplistic study by Joshi et al. (7) reports that mandibular fractures are more frequent in regions where teeth are present rather than in the edentulous areas of the mandible. Bones often fracture at stress and tensile stress sites because their resistance to compressive forces is greater. Furthermore, Bodner et al. showed that the isolated mandible is subjected to non-equivalent tensile stress diffusion patterns when perpendicular forces are exerted on it (8).

MATERIALS AND METHODS

This study followed the PRISMA (Preferred Reporting Items for Systematic Reviews and Meta-Analyses) statement (Fig. 3). The main research question was captured in the PICO (Population, Intervention, Comparison, Outcomes) format: "Can a less invasive operation during oral surgery in the jaw reduce the risk of fractures?"

The search strategy involved searching electronic databases: the PubMed (National Library of Medicine), Google Scholar, Scopus, Embase, Medline, and Cochrane Library databases were searched without time or language restriction to find articles describing the basic principles of HRW and its applications in dental practice (Fig. 3).

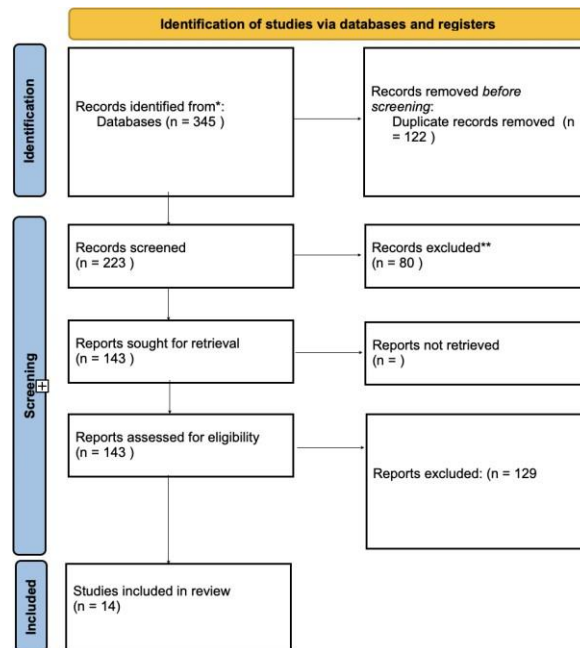


Fig. 3. Search strategy flow chart.

All studies reviewed were published between January 1, 2000, and December 30, 2022. The search strategy used a combination of different MESH terms and keywords on the six databases: “mandibular surgery”, “mandibular fractures”, “impacted tooth”, “bone fracture”, “mandibular cyst”, “wisdom tooth”, “osteoporosis”, “treatment” and “dysodontiasis”; the additional filter “Language: English” was used. The eligibility criteria for the following review include observational studies on patients after dental and cystic-type oral surgery in the mandible, iatrogenic fractures, traumatic fractures, all LeFort types, reviews, systematic reviews with or without meta-analysis, retrospective studies, RCTs, and case reports.

Studies on animal models, 3D models, and letters were excluded. The search strategy identified 345 references published between 2000 and 2022; 143 references were selected for eligibility, and only 14 were included in this review because they met the eligibility criteria.

RESULTS

Mandibular fracture and wisdom teeth surgery

In this review, the risk of mandibular fracture during the surgical procedure of extraction of the included eighth was analyzed, sometimes, although rare, as a post-operative complication. It is strictly necessary to include this complication in the pre-surgical informed consent to be submitted to patients by clearly explaining this eventuality. A study by Libersa et al. showed that intraoperative or post-operative mandible fracture incidence was reported to be 0.0049% (9). Osborn et al. unveiled in a major retrospective study the rate of intraoperative mandibular fracture is 1 in 30,583 patients, while the post-operative rate is 1 in 23,714 (10). Kunkel et al., along with other colleagues, showed in a review that mandibular fracture has an incidence of 1 in 29,000 cases (11).

Possible predisposing conditions were traced in this review: certainly advanced age of the patient, the presence of mandibular atrophic conditions, and patient-dependent systemic problems such as stages of medium to severe osteoporosis. The mandibular region is also significant in the risk of fracture during extraction of included or semi-erupted eighths. For example, the retromolar region is an area of lower resistance to fracture because it is thin in cross-section. In that area, the presence of an included and mesioverted tooth occupies a relatively significant space within the bone. All the more reason if we were faced with an osteoporotic bone with extractive surgical need that would involve removal of the surrounding bone to mobilize it. All this weakens this area mechanically. Studies by Hino et al. (12) retrospectively evaluated the clinical and radiographic data of 12 patients with 13 mandibular fractures after wisdom teeth removal. It

was observed that patients older than 30-40 years with tooth roots overlapping the lower alveolar canal or adjacent to the canal had a high risk of mandibular fracture. There were few intraoperative fractures, while slightly more late fractures, which occurred on average 6.6 days after surgery exclusively during chewing. Libersa et al. (9) evaluated 37 fractures in 750,000 extractions in a retrospective study and identified 17 intraoperative fractures and 10 late fractures. Of the 10 late fractures, 8 occurred in men and 6 occurred during mastication. Most of the late fractures occurred between 13 and 21 days after surgery, possibly caused by increased masticatory function and occlusal forces exceeding bone healing.

Differently, Krimmel and Reinert (13) retrospectively analyzed six patients who suffered a mandibular fracture following removal of a third molar. They showed that fractures occurred from 5 to 28 days (with an average of 14 days) after tooth removal. The patients ranged in age from 42 to 50 years and all had complete dentition. The authors of that study concluded that the main risk factor for mandibular fracture appears to have been the patient's advanced age in combination with a full dentition present in the arch.

Regardless of the mechanism, it was found that mandibular fractures occurring during or immediately after extraction of a mandibular third molar are not displaced. They generally radiate from an extraction site toward the weakest point.

In addition, the above review showed that the side of the fracture is less discussed as a risk factor. Wagner et al. (14) noted that fractures on the left side accounted for 70 percent of cases because right-handed surgeons have a better view of the right surgical field, which results in a less extensive osteotomy. Regarding angulation, the dystangular position is generally considered the most difficult (15). This is probably because mesioangular and vertical angulations are generally more common in patients.

In terms of the position of the impacted tooth, they were found to have higher incidences of mandibular fracture than the upper jaw. This is probably related to a higher degree of difficulty in extraction and more extensive bone removal (16). This review found a higher incidence of mandibular fracture for fully impacted teeth (64.8%) than for partially impacted teeth. This is because when the tooth is fully included in the bone you require more osteotomy access and bone removal for extraction. Post-operatively, this results in less cortical bone remaining and thus a more fragile mandibular angle, which can be an important causative factor for late fracture.

Another retrospective study found a relationship between pericoronitis cases on semi-included eighths (68.3%) and the incidence of late mandibular fracture (17). Recurrent infections may contribute to decalcification and thus to an increased likelihood of late fracture. Although the results are confounding enough to make a connection with mandibular fractures, clearer retrospective data would be needed. This review also observed how mandibular bone quality and density may affect fracture risk.

Pires et al. (18) showed that the period of greatest risk is the second and third post-operative weeks; what happens is that the newly formed granulation tissue in the postextraction socket is replaced by connective tissue and the strength of mandibular bone decreases during this period.

According to Bodner et al. (8), a delay in bone maturation during the regeneration period predisposes to weakening because two-thirds of the socket is not filled with osteoid material. Thus causing a decrease in mandibular bone strength.

Osteoporosis in elderly patients may be another highly predisposing reason. A major study (19) showed that elderly patients had thinning of the periodontal ligament and thus dental ankylosis, increasing the degree of extraction difficulty. All this leads to a significant need for osteotomies that facilitate the likelihood of a possible fracture.

Mandibular fracture and osteoporosis

Osteoporosis is a widespread metabolic disease affecting bone, is characterized by bone density collapse along with microarchitectural failure leading to bone fragility and exposure to fracture risk (20). It affects one in three women and one in five men over the age of 50. The female sex demonstrates declining bone loss as early as menopause, predominantly in trabecular bone, which is then followed by slower loss of trabecular and cortical bone (21).

Because osteoporotic fractures represent a worldwide health burden, it is important to prevent them. Recently, the literature has focused on the morphology of the inner part of the mandibular cortex below the mental foramen. Since then, and to date, several studies have demonstrated the usefulness of the mandibular cortical index as a predictive indication of osteoporosis (22).

Taguchi et al. suggested that bone findings of mandibular morphology would be useful in screening patients with osteoporosis in postmenopausal women (23). On the other hand, Yamada et al. reported in a study of 1021 Japanese men and women found that the mandibular cortical index was useful in identifying dental patients with osteoporosis, but not those with osteoporotic fractures (20).

According to Perry and Goldberg (24), the risk of mandibular fracture during lower third molar extraction in patients with osteoporosis is due to the creation of a bone area with a weakened structure that makes this type of complication more likely to occur. These changes may cause significant weakening of bone, particularly in the mandibular angle region. Therefore, it can be concluded that there is a relationship between the presence of pathological bone changes and the subsequent occurrence of fractures. Joshi et al. (7) pointed out the possibility that post-operative fractures may be incomplete intraoperative fractures, which may have exceeded stress tolerance limits in the weeks following extraction, as patients felt better and pain symptoms had almost disappeared by the end of the following week.

Recent pilot studies have shown that only alendronate and zoledronate have been shown to be less incident in the risk of jaw fractures (25, 26).

Risedronate has been shown to be more incident in susceptibility to mandibular fractures, McClung et al. shows in a specific study of elderly patients with osteoporosis diagnosed on the basis of bone mineral density rather than risk factors (27).

Some studies indicate that cranio-maxillofacial trauma in elderly women with osteoporosis is associated with falls. A recent systemic analysis showed that the number of maxillofacial fractures sustained in a series of 59 subjects older than 60 years was significantly related to the severity of osteoporosis as determined by a radiographic index of vertebral bone density. This association held for low-energy falls and motor vehicle accidents, observations taken as evidence of maxillofacial bone fragility in osteoporotic subjects (28). An analysis of 355 postmenopausal women showed that osteoporosis per se is associated with cranio-mandibular dysfunction (29). Some information is available on the risks of surgical failure in TMJ patients. A study of outcomes in a series of subjects undergoing arthroplasty or discectomy indicated that osteoporosis was the most significant risk factor for technical failure (30). Although mechanisms were neither indicated nor suggested by this study, it is clear that systemic factors must be considered in surgical planning. Although osteoporosis is a very common condition with a sometimes silent sometimes aggressive course, to date the literature does not present crisp guidelines to be followed to prevent this complication. More studies in this regard would be needed to have more scientific evidence

Treatment of mandibular fractures

The vast majority of mandibular fractures require surgical stabilization in order to obtain healing and correct occlusion which is lost after the trauma. In cases of a non-displaced fracture without obvious mobility on manual physical examination, a soft diet for 4 to 6 weeks is generally recommended (31). Displaced fractures or fractures that demonstrate mobility on physical examination are different. In this case, in fact, immobilization of the mandible is expected. Although mandibular fractures with good dentition on both sides of the fracture line can in some cases be treated with a period of intermaxillary fixation, most surgeons and patients prefer open reduction and internal fixation, which allows for a much quicker return to full pre-injury function and mobility (32). Patient demographics, comorbidities, dentition, and fracture characterization influence the treating surgeon's choice of fixation. Internal fixation for mandibular fracture can be divided into two categories: weight-bearing fixation and weight-bearing fixation denote a structure capable of withstanding all the load generated by the mandibular function (33). Typically, this requires the application of a large reconstructive plate to the lower margin of the mandible (Fig. 4).

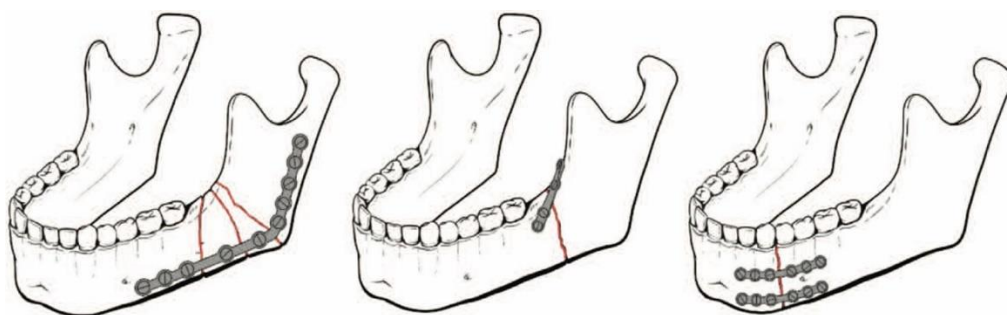


Fig. 4. *Different types of mandibular fixation (Rzewuska A, Kijak E, Halczy-Kowalik L. Rehabilitation in the treatment of mandibular condyle fractures. Dent Med Probl. 2021 Jan-Mar;58(1):89-96. doi: 10.17219/dmp/128092. PMID: 33847468).*

Other studies have demonstrated that load-sharing fixation characterizes a fixation scheme in which the functional load is shared between the base of fixation and the long fracture margin (34). Load-sharing fixation can be divided into rigid and non-rigid (functionally stable). In the past, surgeons often referred to plates by the size of the outer diameter of the screw used in the plate (e.g., 2.0 mm plate, 2.4 mm plate). Today, new reviews have highlighted the importance of more complex but more predictable plate systems (35, 36).

Ellis et al., in a randomized study, demonstrated that the vast majority of unilateral mandibular fractures with good occlusion can be treated in a closed manner (35).

Differently, the situation is not so clear for bilateral fractures (37). This review considered the management of atrophic jaw fractures and how the literature expresses itself on the matter. Today, the most common form with the best results is the application of plates and lathes, so blocked systems are the first option. In the atrophic mandible, factors are considered that decrease the possibilities of consolidation of the low contact surface, poor vascular port, and patient morbidity (38).

DISCUSSION

The results obtained from this review lead to the rationale that the risk of post-extraction mandibular fracture is mainly linked to excessive osteotomy and/or local alterations. Patients at risk must be carefully informed about the importance of food choices in the post-operative period. Finally, the nonsurgical treatment plan appears to be the most suitable approach to nondisplaced fractures for cooperative patients. Technique comparisons addressed general aspects of surgical procedures for mandibular third molars, including the type of raised surgical flap, use of retractors, bone removal techniques, wound irrigation, wound closure, wound drainage, and complete/incomplete tooth removal. All studies analyzed by this review report evidence for each of these comparisons; however, due to the limited number of studies and patients and the high risk of bias, the evidence to make changes to surgical practice is therefore limited. However, this review helps describe the state of research evidence to support practice so that surgeons can make an informed choice in adopting new or continuing with established techniques.

Although today, the use of the mandibular cortical index appears to be quite predictive in evaluating total bone density in patients with bone demineralization, this study did not find great scientific evidence regarding the correlation between iatrogenic mandibular fractures and systemic bone conditions.

Furthermore, this review clarifies the need to carry out new clinical studies, such as randomized or prospective studies with longitudinal follow-up, since most of the available data comes from case series and retrospective studies. However, with the case evaluation of this review, it was possible to clearly identify no late post-operative fractures in patients younger than 20 years. This fact should be shared with third-party payers, who deny authorization to remove asymmetric third molars that will never function.

CONCLUSIONS

The data from this review also show that the patients at greatest risk for late post-third molar extraction fractures of the mandible are men aged 25 years or older, who have had a pre-operative or post-operative infection or menopausal woman suffering from osteomyelitis or taking some types of bisphosphonates. This group should be identified and educated before the intervention and receive unequivocal post-operative instructions that must be strictly respected to avoid late fractures.

REFERENCES

1. Pickrell BB, Hollier LH, Jr. Evidence-Based Medicine: Mandible Fractures. *Plast Reconstr Surg*. 2017;140(1):192e-200e. doi:<https://doi.org/10.1097/PRS.0000000000003469>
2. Oji C. Jaw fractures in Enugu, Nigeria, 1985-95. *Br J Oral Maxillofac Surg*. 1999;37(2):106-109. doi:<https://doi.org/10.1054/bjom.1997.0083>
3. Olson RA, Fonseca RJ, Zeitler DL, Osbon DB. Fractures of the mandible: a review of 580 cases. *J Oral Maxillofac Surg*. 1982;40(1):23-28. doi:[https://doi.org/10.1016/s0278-2391\(82\)80011-6](https://doi.org/10.1016/s0278-2391(82)80011-6)
4. Garza JR, Papel ID. *Mandibular fractures : Facial plastic and reconstructive surgery*. New York: Thieme Medical Publishers; 2002.
5. Mitsukawa N, Satoh K, Uemura T, Hosaka Y. An unusual traumatic fracture of the mandibular symphysis resembling horizontal osteotomy for genioplasty. *J Craniofac Surg*. 2004;15(2):229-231; discussion 232. doi:<https://doi.org/10.1097/00001665-200403000-00011>

6. Bezerra TP, Studart-Soares EC, Pita-Neto IC, Costa FW, Batista SH. Do third molars weaken the mandibular angle? *Med Oral Patol Oral Cir Bucal*. 2011;16(5):e657-663. doi:<https://doi.org/10.4317/medoral.16970>
7. Joshi A, Goel M, Thorat A. Identifying the risk factors causing iatrogenic mandibular fractures associated with exodontia: a systemic meta-analysis of 200 cases from 1953 to 2015. *Oral Maxillofac Surg*. 2016;20(4):391-396. doi:<https://doi.org/10.1007/s10006-016-0579-9>
8. Bodner L, Brennan PA, McLeod NM. Characteristics of iatrogenic mandibular fractures associated with tooth removal: review and analysis of 189 cases. *Br J Oral Maxillofac Surg*. 2011;49(7):567-572. doi:<https://doi.org/10.1016/j.bjoms.2010.09.007>
9. Libersa P, Roze D, Cachart T, Libersa JC. Immediate and late mandibular fractures after third molar removal. *J Oral Maxillofac Surg*. 2002;60(2):163-165; discussion 165-166. doi:<https://doi.org/10.1053/joms.2002.29811>
10. Osborn TP, Frederickson G, Jr., Small IA, Torgerson TS. A prospective study of complications related to mandibular third molar surgery. *J Oral Maxillofac Surg*. 1985;43(10):767-769. doi:[https://doi.org/10.1016/0278-2391\(85\)90331-3](https://doi.org/10.1016/0278-2391(85)90331-3)
11. Kunkel M, Kleis W, Morbach T, Wagner W. Severe third molar complications including death-lessons from 100 cases requiring hospitalization. *J Oral Maxillofac Surg*. 2007;65(9):1700-1706. doi:<https://doi.org/10.1016/j.joms.2007.04.014>
12. Hino S, Yamada M, Araki R, Kaneko T, Iizuka T, Horie N. What Are Possible Contributors to Associated Dental Injury in Mandibular Fractures? *J Oral Maxillofac Surg*. 2022;80(1):127-136. doi:<https://doi.org/10.1016/j.joms.2021.09.002>
13. Krimmel M, Reinert S. Mandibular fracture after third molar removal. *J Oral Maxillofac Surg*. 2000;58(10):1110-1112. doi:<https://doi.org/10.1053/joms.2000.9566>
14. Wagner KW, Otten JE, Schoen R, Schmelzeisen R. Pathological mandibular fractures following third molar removal. *Int J Oral Maxillofac Surg*. 2005;34(7):722-726. doi:<https://doi.org/10.1016/j.ijom.2005.03.003>
15. Xu JJ, Teng L, Jin XL, Lu JJ, Zhang C. Iatrogenic mandibular fracture associated with third molar removal after mandibular angle osteotomy. *J Craniofac Surg*. 2014;25(3):e263-265. doi:<https://doi.org/10.1097/SCS.0000000000000566>
16. Steinberg JP, Hirsch EM, Olsson AB, Olsson AB. Functionally stable fixation for an infected mandibular angle fracture associated with third molar extraction during pregnancy. *J Craniofac Surg*. 2013;24(3):1050-1051. doi:<https://doi.org/10.1097/SCS.0b013e318280211d>
17. Al-Belasy FA, Tozoglu S, Ertas U. Mastication and late mandibular fracture after surgery of impacted third molars associated with no gross pathology. *J Oral Maxillofac Surg*. 2009;67(4):856-861. doi:<https://doi.org/10.1016/j.joms.2008.09.007>
18. Pires WR, Bonardi JP, Faverani LP, et al. Late mandibular fracture occurring in the post-operative period after third molar removal: systematic review and analysis of 124 cases. *Int J Oral Maxillofac Surg*. 2017;46(1):46-53. doi:<https://doi.org/10.1016/j.ijom.2016.09.003>
19. Woldenberg Y, Gatot I, Bodner L. Iatrogenic mandibular fracture associated with third molar removal. Can it be prevented? *Med Oral Patol Oral Cir Bucal*. 2007;12(1):E70-72.
20. Yamada S, Uchida K, Iwamoto Y, et al. Panoramic radiography measurements, osteoporosis diagnoses and fractures in Japanese men and women. *Oral Dis*. 2015;21(3):335-341. doi:<https://doi.org/10.1111/odi.12282>
21. Cosman F, de Beur SJ, LeBoff MS, et al. Clinician's Guide to Prevention and Treatment of Osteoporosis. *Osteoporos Int*. 2014;25(10):2359-2381. doi:<https://doi.org/10.1007/s00198-014-2794-2>
22. Taguchi A. Triage screening for osteoporosis in dental clinics using panoramic radiographs. *Oral Dis*. 2010;16(4):316-327. doi:<https://doi.org/10.1111/j.1601-0825.2009.01615.x>
23. Taguchi A, Tanaka R, Kakimoto N, et al. Clinical guidelines for the application of panoramic radiographs in screening for osteoporosis. *Oral Radiol*. 2021;37(2):189-208. doi:<https://doi.org/10.1007/s11282-021-00518-6>
24. Perry PA, Goldberg MH. Late mandibular fracture after third molar surgery: a survey of Connecticut oral and maxillofacial surgeons. *J Oral Maxillofac Surg*. 2000;58(8):858-861. doi:<https://doi.org/10.1053/joms.2000.8204>
25. Black DM, Thompson DE, Bauer DC, et al. Fracture risk reduction with alendronate in women with osteoporosis: the Fracture Intervention Trial. FIT Research Group. *J Clin Endocrinol Metab*. 2000;85(11):4118-4124. doi:<https://doi.org/10.1210/jcem.85.11.6953>
26. Black DM, Rosen CJ. Clinical Practice. Postmenopausal Osteoporosis. *N Engl J Med*. 2016;374(3):254-262. doi:<https://doi.org/10.1056/NEJMcp1513724>
27. McClung MR, Geusens P, Miller PD, et al. Effect of risedronate on the risk of hip fracture in elderly women. Hip Intervention Program Study Group. *N Engl J Med*. 2001;344(5):333-340. doi:<https://doi.org/10.1056/NEJM200102013440503>
28. Bischoff-Ferrari HA, Willett WC, Wong JB, Giovannucci E, Dietrich T, Dawson-Hughes B. Fracture prevention with vitamin D supplementation: a meta-analysis of randomized controlled trials. *JAMA*. 2005;293(18):2257-2264. doi:<https://doi.org/10.1001/jama.293.18.2257>
29. Klemetti E, Vainio P, Kroger H. Craniomandibular disorders and skeletal mineral status. *Cranio*. 1995;13(2):89-92. doi:<https://doi.org/10.1080/08869634.1995.11678050>

30. Kirk WS, Jr. Risk factors and initial surgical failures of TMJ arthrotomy and arthroplasty: a four to nine year evaluation of 303 surgical procedures. *Cranio*. 1998;16(3):154-161. doi:<https://doi.org/10.1080/08869634.1998.11746053>
31. Morrow BT, Samson TD, Schubert W, Mackay DR. Evidence-based medicine: Mandible fractures. *Plast Reconstr Surg*. 2014;134(6):1381-1390. doi:<https://doi.org/10.1097/PRS.0000000000000717>
32. Ellis E, 3rd, Miles BA. Fractures of the mandible: a technical perspective. *Plast Reconstr Surg*. 2007;120(7 Suppl 2):76S-89S. doi:<https://doi.org/10.1097/01.prs.0000260721.74357.e7>
33. Agnihotri A, Prabhu S, Thomas S. A comparative analysis of the efficacy of cortical screws as lag screws and miniplates for internal fixation of mandibular symphyseal region fractures: a randomized prospective study. *Int J Oral Maxillofac Surg*. 2014;43(1):22-28. doi:<https://doi.org/10.1016/j.ijom.2013.07.001>
34. Stacey DH, Doyle JF, Mount DL, Snyder MC, Gutowski KA. Management of mandible fractures. *Plast Reconstr Surg*. 2006;117(3):48e-60e. doi:<https://doi.org/10.1097/01.prs.0000209392.85221.0b>
35. Ellis E, 3rd, Kellman RM, Vural E. Subcondylar fractures. *Facial Plast Surg Clin North Am*. 2012;20(3):365-382. doi:<https://doi.org/10.1016/j.fsc.2012.05.002>
36. Kushner GM, Tiwana PS. Fractures of the growing mandible. *Atlas Oral Maxillofac Surg Clin North Am*. 2009;17(1):81-91. doi:<https://doi.org/10.1016/j.cxom.2008.11.001>
37. Luhr HG, Reidick T, Merten HA. Results of treatment of fractures of the atrophic edentulous mandible by compression plating: a retrospective evaluation of 84 consecutive cases. *J Oral Maxillofac Surg*. 1996;54(3):250-255. doi:10.1016/s0278-2391(96)90733-8
38. Liu FC, Halsey JN, Oleck NC, Lee ES, Granick MS. Facial Fractures as a Result of Falls in the Elderly: Concomitant Injuries and Management Strategies. *Craniomaxillofac Trauma Reconstr*. 2019;12(1):45-53. doi:<https://doi.org/10.1055/s-0038-1642034>