

Case Report

SURGICAL EXCISION OF A FIBROMATOUS EPULIS AND A PERIPHERAL GIANT CELL GRANULOMA: TWO CASE REPORTS

I. Cammarota¹, C. Lorenzi¹, A. Rosa¹, A.M. Pujia¹

¹Department of Chemical Science and Technologies, University of Rome Tor Vergata, Rome, Italy

Correspondence to:

Alberto Maria Pujia, DDS

Department of Chemical Science and Technologies,

University of Rome Tor Vergata,

Rome, Italy

e-mail: albpujia@gmail.com

ABSTRACT

“Epulis” is an umbrella term clinicians use to describe any localized subepithelial enlargement of the gingiva or alveolar mucosa. Under this generic definition, several types of lesions have peculiar macro- and microscopic characteristics. Hence, traditionally, epulides are categorized into different subtypes, but currently, the literature has identified three primary forms: granulomatous, fibrous, and giant-cell epulis. The purpose of this article is to present two cases of epulides: the first one is fibromatous (or fibrous) epulis, and the second one is giant cell epulis, also known as Peripheral Giant Cell Granuloma (PGCG). The treatment choice for these neoformations was surgical excision, performed in the Clinic of Odontostomatology of San Sebastiano Hospital, Frascati (Rome). The first lesion was removed in one appointment; the second one was removed in two surgical sessions due to its dimensions.

KEYWORDS: *gingiva, epilus, hypertrophy, mass*

INTRODUCTION

According to Slootweg’s “*Dental and Oral Pathology*,” an epulis is a collective term for oral mucosa lesions having an intimate relation with the periodontal membrane or the periosteum of the jaw. In practice, it is used for localized swellings of the gingiva (1).

The word “epulis,” from the Greek ἐπουλίς “over the gingiva,” indicates any localized, slow-growing, and asymptomatic gingival mass (2).

Three primary categories of epulides have been identified, differentiated based on their tissue origin: granulomatous epulis (also known as epulis haemangiomas), fibrous (or fibroid) epulis, and giant cell (or myeloid) epulis. However, numerous other conditions have been documented in the literature, including congenital epulis, epulis fissuratum, pregnancy tumor (3), pyogenic granuloma, fibrous hyperplasia, peripheral fibroma with calcification, and lympho-plasma-cellular variety (4, 5).

The aim of this report is to present two cases of epulides, specifically fibrous epulis and peripheral giant cell granuloma, with relative surgical excisions.

Received: 2 September 2023

Accepted: 12 October 2023

Copyright © by LAB srl 2023 ISSN 2975-1276

This publication and/or article is for individual use only and may not be further reproduced without written permission from the copyright holder. Unauthorized reproduction may result in financial and other penalties. Disclosure: All authors report no conflicts of interest relevant to this article.

CASE DESCRIPTIONS

First case – Fibromatous epulis

A 45-year-old man with no relevant medical history presented in the Clinic of Odontostomatology of San Sebastiano Hospital, Frascati (Rome), with a gingival swelling between the upper central incisors. The patient reported that the lump had been present for a few months and gradually increased in size, causing difficulties and discomfort in chewing.

The clinical examination revealed an asymptomatic gingival mass that was firm, sessile, and pink without any signs of inflammation, erosion, or ulceration (Fig. 1).

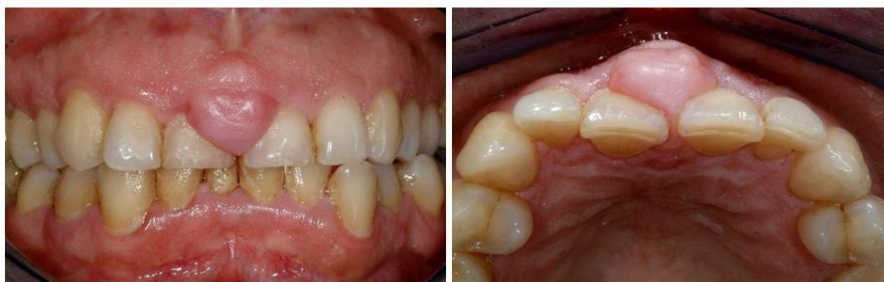

Fig. 1. *The macroscopical aspect of the lesion.*

It was prevalent on the buccal surface but extended on the palatal side. The general oral hygiene condition of the patient was not optimal. On the radiographic examination, it was possible to observe no erosion of underlying bone (Fig. 2).

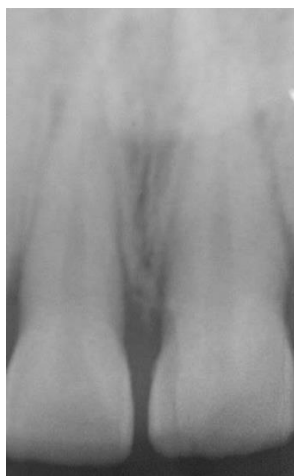

Fig. 2. *Radiographically, it is possible to observe that the interdental bone pick was intact.*

The therapeutic plan included a first appointment of professional oral hygiene and a second one in which the lesion was surgically removed. The patient took 2 g of amoxicillin with clavulanic acid 1 hour before surgery.

After a local anesthesia infiltration, the complete excision of the epulis was performed using a scalpel until the entire tissue of the epulis was separated from the surrounding healthy tissue (Fig. 3).

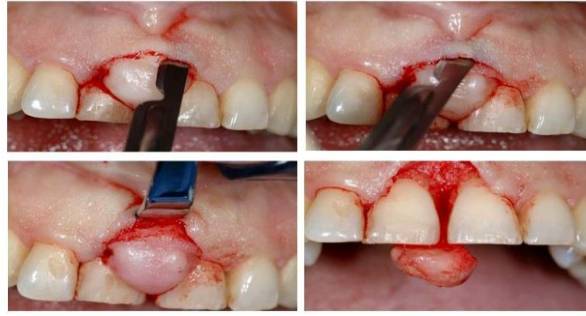

Fig. 3. *Surgical incision and removal of the lesion.*

Therefore, the surgical wound was irrigated with saline water and sutured with 4-0 silk. The extraoral aspect of this fibrous epulis showed a main rounded body of the lesion and a palatal peduncle (Fig. 4).

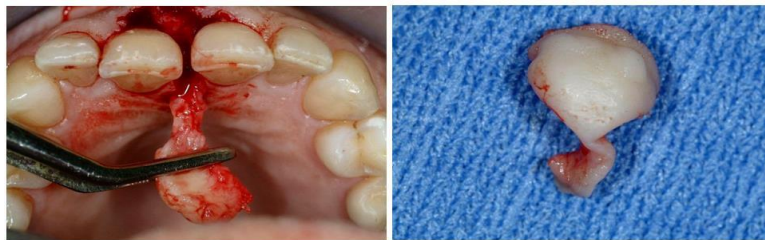


Fig. 4. *Removed lesion.*

Thus, the tissue was put inside 10% of formalin and sent to pathology. Post-surgical instructions were given, such as not chewing on the surgical area and not drinking or eating anything hot for the first 24 hours. Pharmacologic management consisted of amoxicillin with clavulanic acid at a dose of 1 mg every twelve hours for six days. The patient was also instructed to come back a week after surgery for the removal of the suture and after two weeks for control of the healing process (Fig. 5).

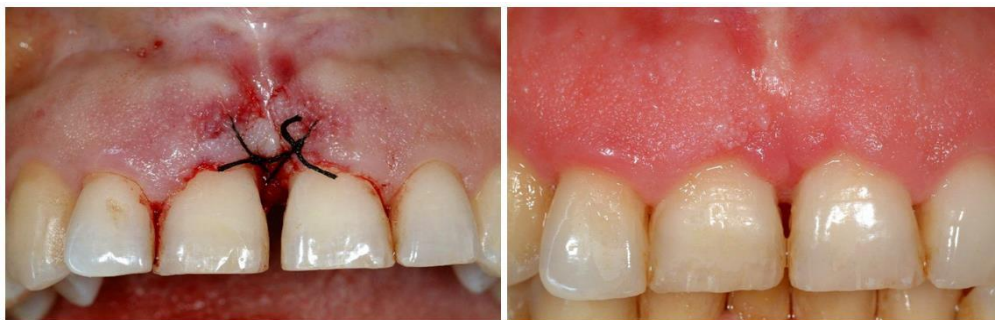

Fig. 5. *The healing of the surgical site.*

Second case - Peripheral Giant Cell Granuloma (PGCG)

A 58-year-old man with controlled hypertension presented in the Clinic of Odontostomatology of San Sebastiano Hospital, Frascati (Rome), with a dark red-colored mass on the anterior region of the upper maxilla. During the last year, the patient experienced little or no pain but felt persistent discomfort during chewing and speaking. The clinical examination showed a dark red swelling on the edentulous space (Fig. 6).

From a frontal point of view, the lesion appeared sessile. On the distal side, however, it seemed to have a large peduncle (Fig. 7). The radiograph examination shows focal resorption of the underlying alveolar bone (Fig. 8). The patient took 2 g of amoxicillin with clavulanic acid 1 hour before surgery.

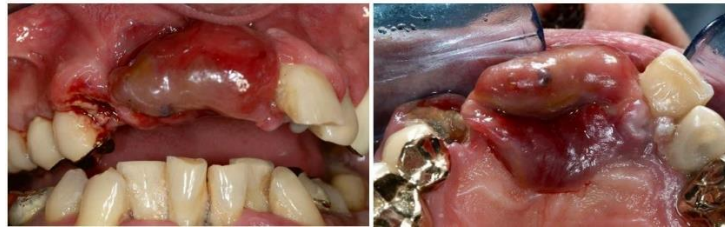

Fig. 6. *The macroscopical aspect of the lesion.*

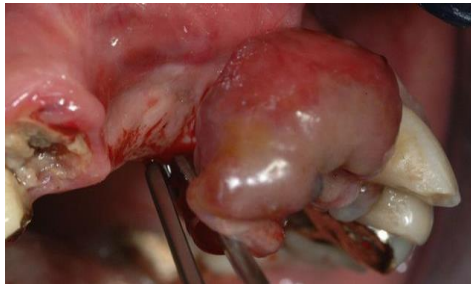

Fig. 7. *The base of the mass was between the sessile and the pedunculated.*

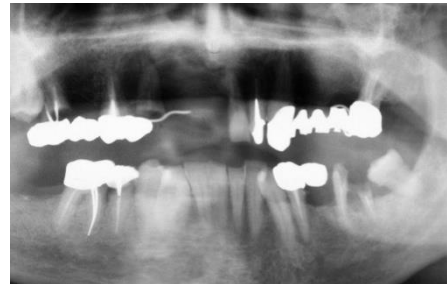


Fig. 8. *On the radiograph, the lesion is lightly radiopaque.*

Under local anesthesia, surgical excision was conducted using a No. 15 scalpel blade to completely remove the mass, along with further curettage of the cortical bone surface. After removing the lesion, the wound was primarily closed using a 4-0 suture with an interrupted vertical mattress suture and an interrupted single suture (Fig. 9).

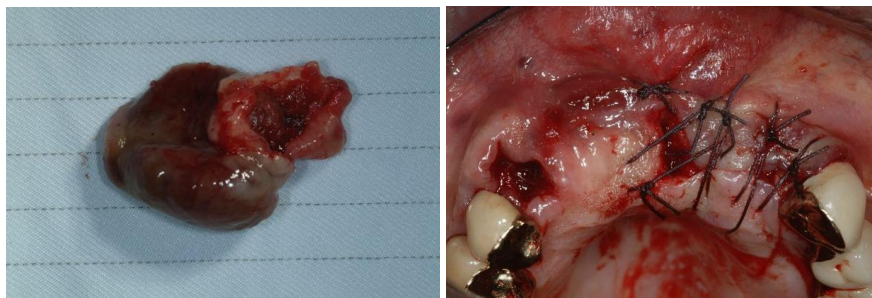


Fig. 9. *The first surgical removal of PGCG.*

Post-surgical instructions were given, such as not chewing on the surgical area and not drinking or eating anything hot for the first 24 hours. Pharmacologic management consisted of amoxicillin with clavulanic acid at a dose of 1 mg every twelve hours for six days. The patient was also instructed to come back a week after surgery for the removal of the suture.

At the 2-month follow-up, the surgical wound appeared to have healed perfectly; however, a residual lesion was observed on the mucogingival junction (Fig. 10).

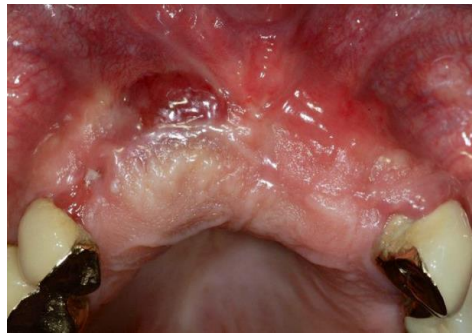

Fig. 10. *A part of the lesion residual.*

Then, it was decided to perform a second surgical removal. In this second surgical access, it was observed that the lesion, had eroded the underlying alveolar bone (Fig. 11-12).

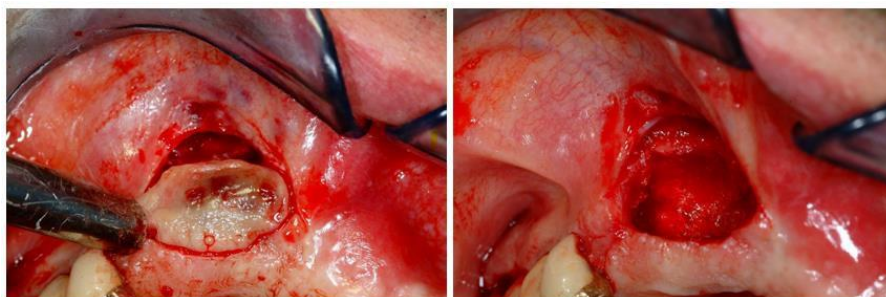


Fig. 11. *The second surgical access.*

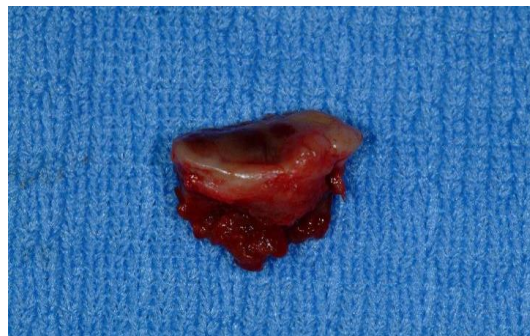

Fig. 12. *The residual lesion removed.*

After enucleating the lesion, curettage was performed on the underlying bone. The wound was primarily closed using a 4-0 suture with an interrupted single suture. The exact postoperative instructions for the first surgery were given during this appointment.

At the follow-up at 2 months, the surgical wound appeared to have healed without further residual lesions (Fig. 13).

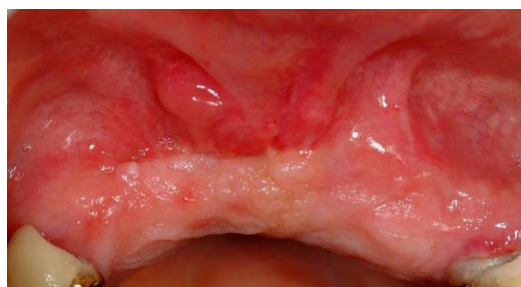

Fig. 13. *The healing of the surgical wound.*

DISCUSSION

“Epulis” is a nonspecific term used for tumors and tumorlike masses of the gingiva with mixed cell origin arising from periodontal squamous cell residues (5). The factors that influence their formation, rate of growth, and likelihood of recurrence remain unclear. However, various possibilities have been explored, including the type of injury or inflammation, oral hygiene, diet, alcohol consumption, smoking, medication, hormonal balance, and immune function (5, 6).

Fibrous epulis is a benign tumor of the gingiva that most often occurs in the interdental papilla area due to local irritation (inadequate restorative fillings, carious teeth, subgingival deposits, or the combination of them) (7). In other words, it is essentially a reactive fibrous hyperplasia (8). In the first case presented in this paper, the possible etiology of the lesion is unknown because there were no significant predisposing factors other than non-optimal oral hygiene. The surface texture and presentation reflect the previous history of the lesion, e.g., hyperkeratosis or occasional ulceration (8). This lesion represents the archetype and most common epulides with a female bias and predominantly adult distribution (8). This lesion is frequently represented as a firm, pink, un-inflamed mass. Most often, the lesion is painless. Pain may be associated with secondary trauma via brushing, flossing, or chewing. The swelling is sessile initially and then becomes pedunculated (9). All these clinical features can be found in the fibromatous epulis presented in this article. There is no erosion of underlying bone and no interdental spread unless there is a pre-existing diastema or pre-existing interdental bone loss due to chronic periodontitis. They may slowly increase in size, and some can reach impressive proportions and compromise the outcome of surgical removal, but this is an uncommon finding (8). The treatment of these lesions focuses specifically on understanding the derivation from the periodontal tissues, so a superficial gingivectomy-type procedure will frequently result in recurrence. Mucoperiosteal flaps are best raised so the lesion can be excised entirely, suprabony connective tissue curetted, and the adjacent tooth and root surfaces debrided of plaque and calculus or plaque-retaining factors to minimize recurrence. The cosmetic result depends on the site of the lesion, the periodontal bone support present, and the amount of attached gingiva (8). The first case presented reached a satisfactory aesthetic result due to the bone peak preservation and adequate availability of attached soft tissue.

Peripheral giant cell granuloma, or “giant cell epulis,” is the most common oral giant cell lesion. The peripheral giant cell granuloma accounts for approximately 10% of epulides (10, 11). They occur over a wide age range with a lower age peak incidence for males than females and a female predilection. These lesions can occur in any part of the gingiva in dentate patients or on the alveolar ridge in edentulous patients, such as the second case presented. Still, most occur anterior to the molar region and are slightly more common in the mandible (10, 12). It typically appears as a purplish-red nodule in soft tissue comprising multinucleated giant cells within a backdrop of mononuclear stromal cells and leaked red blood cells. This condition likely isn't an actual tumor but is more likely a reactive response, thought to be triggered by local irritation or injury, although the exact cause remains uncertain (13). As in the second clinical case presented in this paper, PGCGs typically appear as deep red or purple sessile growths that can grow significantly in size. They might extend between teeth, resembling a dumbbell shape (10). Sometimes, the initial excision is not thorough, and the pathologist preparing the report should acknowledge this. To ensure a comprehensive evaluation, it is essential to comment on the necessity for additional investigations, such as radiological examinations (10, 14).

CONCLUSIONS

This case report presents two peculiar oral epulides with different clinical and histological characteristics. The surgical removal was the treatment of choice of both neoformations, with various results depending on the size and complexity of the two epulides: in the fibromatous type, only one intervention was needed to complete the resolution of the lesion, whereas, in the giant cell type, a second surgical access was required to achieve total healing.

REFERENCES

1. van der Wal JE. Epulis. In: *Dental and Oral Pathology*,. Edited by Sloomweg PJ: Springer International Publishing; 2016. 159–161.
2. Costa P, Peditto M, Marcianò A, Barresi A, Oteri G. The ‘Epulis’ Dilemma. Considerations from Provisional to Final Diagnosis. A Systematic Review. *ORAL and Implantology*. 2021;1(3):224–235.
3. Daley TD, Nartey NO, Wysocki GP. Pregnancy tumor: An analysis. *Oral Surgery, Oral Med. Oral Pathol.* 1991;72(2):196–199.
4. Margiotta V, Franco V, Giuliana G. [Epulides: the histopathological and epidemiological aspects]. *Minerva Stomatol.* 1991;40(1-2):51-55.

5. Zheng JW, Zhou Q, Yang XJ, et al. Intralesional injection of Pingyangmycin may be an effective treatment for epulis. *Med Hypotheses*. 2009;72(4):453-454. doi:<https://doi.org/10.1016/j.mehy.2008.10.022>
6. Niedzielska I. [Epuli--the inflammatory or neoplastic tumor]. *Pol Merkur Lekarski*. 2008;24(140):149-150.
7. Radanović M, Tomić S, Ivanović T, et al. Fibrous epulis - case report. *Биомедицинска Истраживања*. 2022;13(1):79–84.
8. Savage NW, Daly CG. Gingival enlargements and localized gingival overgrowths. *Aust Dent J*. 2010;55 Suppl 1(55-60). doi:<https://doi.org/10.1111/j.1834-7819.2010.01199.x>
9. Sakr M. *Head and Neck and Endocrine Surgery: From Clinical Presentation to Treatment Success*: Springer International Publishing; 2016.
10. Brierley DJ, Crane H, Hunter KD. Lumps and Bumps of the Gingiva: A Pathological Miscellany. *Head Neck Pathol*. 2019;13(1):103-113. doi:<https://doi.org/10.1007/s12105-019-01000-w>
11. Truschnegg A, Acham S, Kiefer BA, Jakse N, Beham A. Epulis: a study of 92 cases with special emphasis on histopathological diagnosis and associated clinical data. *Clin Oral Investig*. 2016;20(7):1757-1764. doi:<https://doi.org/10.1007/s00784-015-1665-3>
12. Lester SR, Cordell KG, Rosebush MS, Palaiologou AA, Maney P. Peripheral giant cell granulomas: 279 cases. *Oral Surg Oral Med Oral Pathol Oral Radiol*. 2014;118(4):475-482. doi:<https://doi.org/10.1016/j.oooo.2014.06.004>
13. Tandon PN, Gupta SK, Gupta DS, Jurel SK, Saraswat A. Peripheral giant cell granuloma. *Contemp Clin Dent*. 2012;3(Suppl 1):S118-121. doi:<https://doi.org/10.4103/0976-237X.95121>
14. Pinheiro LR, Pinheiro JJ, Junior SA, Guerreiro N, Cavalcanti MG. Clinical and radiological findings of central giant cell lesion and cherubism. *Braz Dent J*. 2013;24(1):74-79. doi:<https://doi.org/10.1590/0103-6440201301861>