

Case Report

SPLIT CREST TECHNIQUE: A 16-YEAR FOLLOW-UP CASE REPORT

G. Ferraro¹, M.V. Paratelli², G. El Haddad² and E. El Haddad²

¹University of Ferrara, Ferrara, Italy

²Private practice, Turin, Italy

Correspondence to:

Elias El Haddad, MD, DDS

Corso Vittorio Emanuele II, 38

10123, Turin, Italy

e-mail: elias.h@tiscali.it

ABSTRACT

In most cases, alveolar atrophy is a result of tooth loss. To rehabilitate those areas, bone volume must be increased before inserting implants. The alveolar bone's width must be adequate to the optimally planned implant diameter. Several methods can be performed for bone augmentation, such as autogenous block or Guided Bone Regeneration (GBR). In addition to these methods, the Split Crest Technique (SCT) is a valid option for increasing bone width in atrophic alveolar crests, and it has several advantages. The present work describes a clinical case using the SCT and reviews the literature until now.

KEYWORDS: *mandible, jaw, split, crest, alveolus, graft*

INTRODUCTION

In long-time edentulous alveolar ridge segments, horizontal and vertical bone resorptions occur. Numerous studies have revealed that once a tooth is lost, the horizontal dimension of the alveolar bone significantly decreases. According to these studies, the alveolar ridge can reduce its width by 50%, corresponding to 5 to 7 mm (1-3). Today, there is general agreement that implant placement requires a minimal amount of 3 mm of surrounding bone. Simple fixture insertion is impossible when there is a mismatch between the alveolar bone's horizontal dimension and the implant's diameter.

Oral rehabilitation in areas with insufficient bone width is complex because dental implant osseointegration is highly predictable only when implants are surrounded by adequate bone (4). To achieve a predictable outcome, the crest's optimal width should allow at least a 1.5 mm bone frame after the implant is placed (5). If the width of the alveolar bone is not adequate to the optimally planned implant diameter, the case requires bone volume augmentation treatments.

Several methods can be performed for bone augmentation, such as autogenous block grafts obtained from intraoral sites or extraoral sites (6-9) or Guided Bone Regeneration (GBR) (10). These two methods present some disadvantages. For example, in the case of GBR, there are increased treatment costs, delay of implant placement, and, in some cases, exposure of the membrane with consequential infection. In the case of bone grafting, it is necessary to have a second surgery site to collect bone, a 6-month delay of implant placement to allow grafting material to heal, and a higher risk of dehiscence.

Received: 4 December 2023

Accepted: 26 January 2024

Copyright © by LAB srl 2024 ISSN 2975-1276

This publication and/or article is for individual use only and may not be further reproduced without written permission from the copyright holder. Unauthorized reproduction may result in financial and other penalties. Disclosure: All authors report no conflicts of interest relevant to this article.

An alternative approach to bone grafting and GBR has been developed to treat narrow alveolar ridges, called Split Crest Technique (SCT). It was first described by Nentwig in 1986 (11) and studied by G.B. Bruschi and A. Scipioni, who described the Edentulous Ridge Expansion technique (ERE) (12). This bone inlay grafting and implant placement technique consists of horizontal and vertical osteotomies to distance cortices (vestibular and palatal/lingual). This procedure allows for implant placement and introduction of biomaterials - such as bovine origin bone covered with collagen membrane. One of the main advantages is the reduction in the number of surgical procedures and the total treatment time for the patients. The closure is indeed by first intent, and this technique does not require a second surgical area to harvest bone grafts. Here, a clinical case is reported, and recent literature is discussed.

CASE REPORT

The patient was a healthy, non-smoking 64-year-old woman. Her dental history included a recent failure of a removable partial denture rehabilitation due to psychological and functional reasons. She complained of chewing difficulty because of a partial mandibular edentulism (missing teeth: 4.5, 4.6, 4.7) (Fig. 1).

The patient asked for functional rehabilitation and agreed to undergo bone regenerative therapy and the placement of a fixed prosthesis using endosteal fixtures.

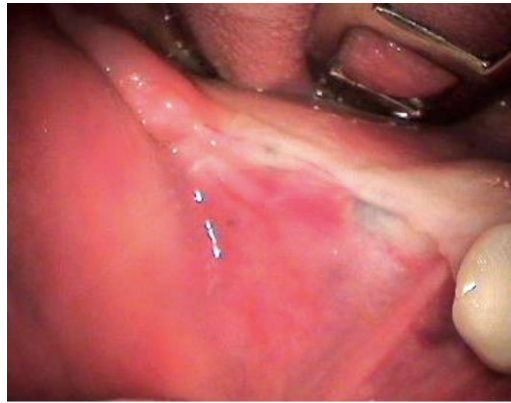

Fig. 1. Pre-op intraoral photography.

The patient was rehabilitated with a bridge at the time of the visit. During clinical examination, a ridge defect with a reduction in the thickness of bone, which appeared to be thin, was diagnosed.

The Cone Beam Computed Tomography (CBCT) scan showed the horizontal defect (Fig. 2): in site 4.5, the thickness of the crest was 1-2 mm; in site 4.6, the same parameter was 1-2 mm, and in site 4.7 it was 2 mm.

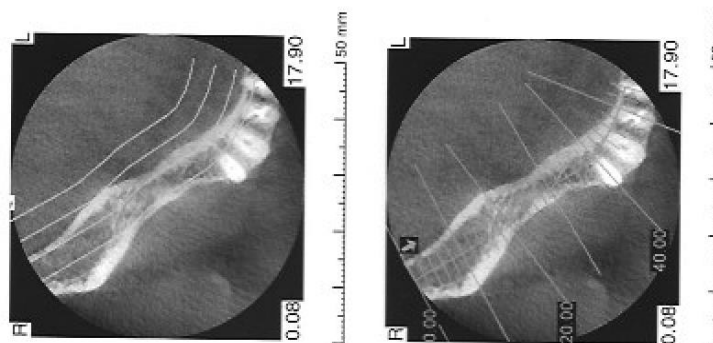


Fig. 2. CT scan shows the horizontal defect.

The panoramic X-ray showed the edentulous sites and a deep alveolar pocket on element 4.8. (Fig. 3).

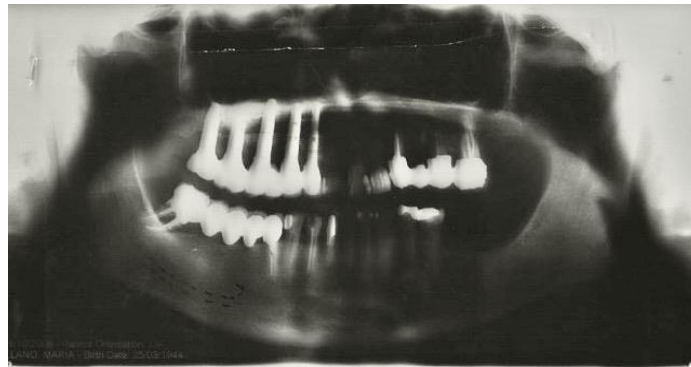


Fig. 3. Panoramic X-ray.

Severe horizontal bone defects in this location can be treated using techniques such as GBR or autogenous block grafts. For this patient, the best option seemed to be the SCT, which used ultrasonic devices and immediate implant placement.

The patient was treated with local anesthetics with adrenaline. A full-thickness mid-crest flap was incised with a vertical distal and mesial releasing incision to mobilize the flap (Fig. 4).

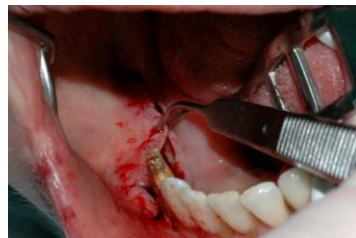

Fig. 4. Mid-crest flap.

The crestal osteotomy was executed using an ultrasonic device to a depth of 10 mm (Fig. 5). The CBCT showed that the mandibular canal was located at 13 mm. Two vertical osteotomies were also executed distally and mesially (Fig. 6). An apical osteotomy was also executed to avoid the fracture of the bone block during its mobilization (Fig. 7).

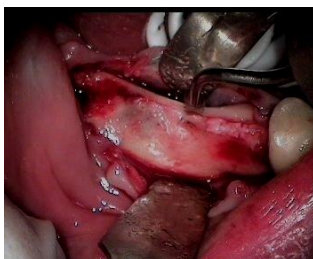

Fig. 5. Horizontal osteotomy.

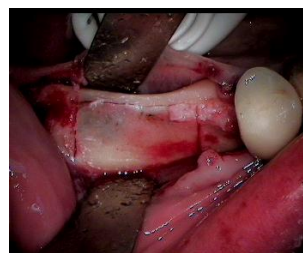

Fig. 6. Vertical osteotomy.

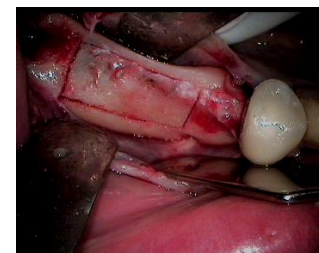


Fig. 7. Apical osteotomy.

Once the bone block was moved horizontally, the implant site was prepared to guarantee primary stability to the implants in their apical portions. In this case, the three implants placed were Replace Tapered (Nobel Biocare ®) conical implants (4,3 × 13 mm) with a Ti Unite surface. These implants were positioned in sites 4.6, 4.7, and 4.8 (previously extracted) (Fig. 8, 9).

The primary stability of the implants was excellent at 20 N. Filling materials between the lingual and vestibular pieces was unnecessary because the bone morphology created was a four-wall type: the clot was sufficient for bone regeneration.

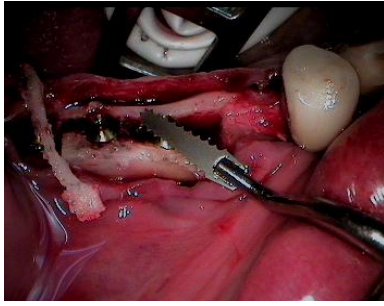


Fig. 8. *Implant placement*

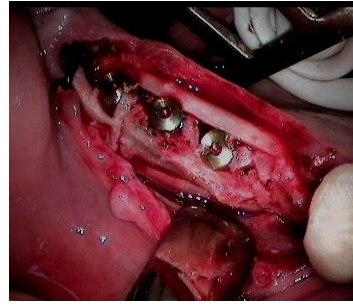


Fig. 9. *Result after implant placement*

To obtain a passive closure with no tension, horizontal incisions of the periosteum were executed. Before this surgical procedure, it was essential to isolate the mental nerve.

The flap was sutured using the Glottlow technique (Fig. 10).

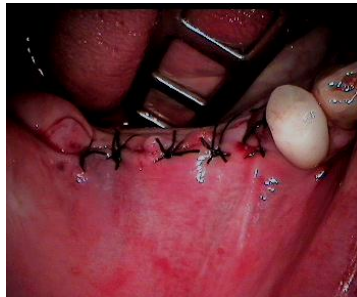

Fig. 10. *Glottlow technique.*

A control X-ray was executed (Fig. 11), and the patient was dismissed.

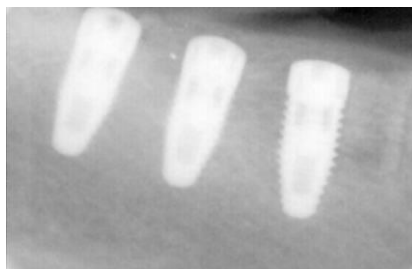

Fig. 11. *Control X-ray.*

The post-operative therapy was done with antibiotics (amoxicillin and clavulanic acid), chlorhexidine mouthwash, and painkillers. Three months later, healing caps were inserted (Fig. 12-14).

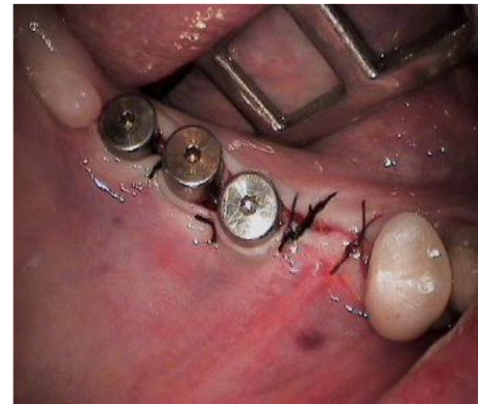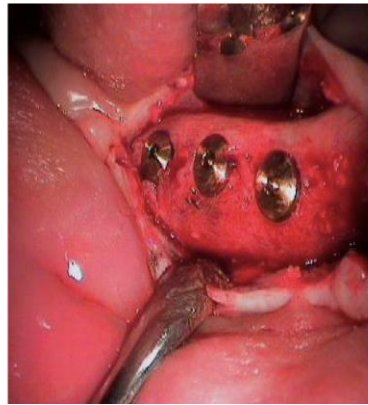
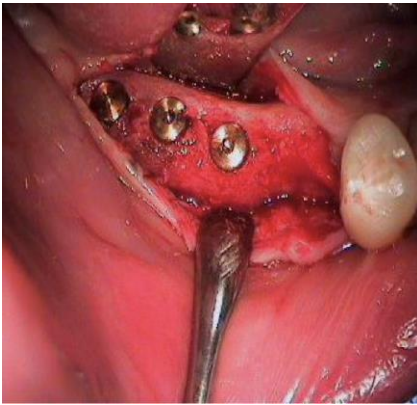


Fig. 12. *Elevation of the flap.*

Fig. 13. *Regenerated alveolar.*

Fig. 14. *Closure with healing caps.*

A metal-ceramic prosthesis with an extension on element 4.5 was delivered (Fig.15). Since a lack of keratinized tissue was observed (Fig. 16), tissue grafting surgery was planned.

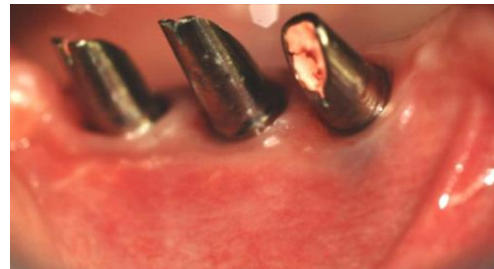
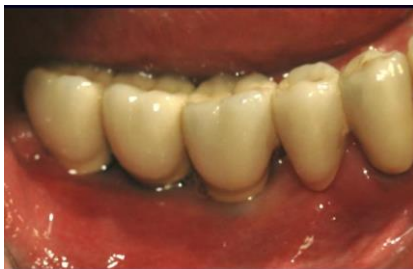

Fig.15. *Metal-ceramic prosthesis.*

Fig. 16. *Lack of keratinized tissue.*

Indeed, soft tissue grafting procedures result in more favorable peri-implant health: (i) for the gain of keratinized mucosa using autogenous grafts with a more significant improvement of bleeding indices and higher marginal bone levels; (ii) for the gain of mucosal thickness using autogenous grafts with significantly less marginal bone loss (13). First, the receiving site was prepared (Fig. 17). The connective graft (Fig. 18) was harvested from the palate (Fig. 19).

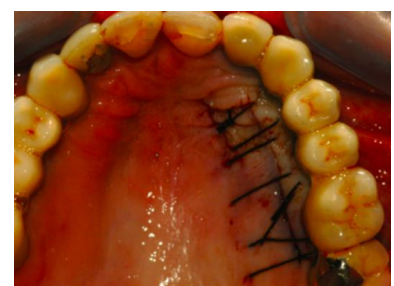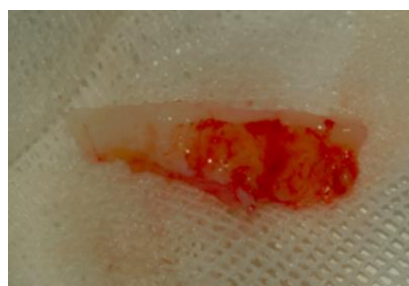

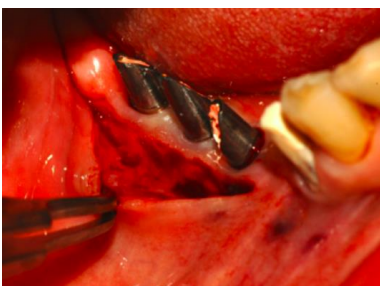
Fig. 17. *Receiving site.*

Fig. 18. *Connective graft.*

Fig. 19. *Palate.*

After placing the connective graft on the receiving site, a suture was performed (Fig. 20). The results one month later are reported in Fig. 21.



Fig. 20. Suture.

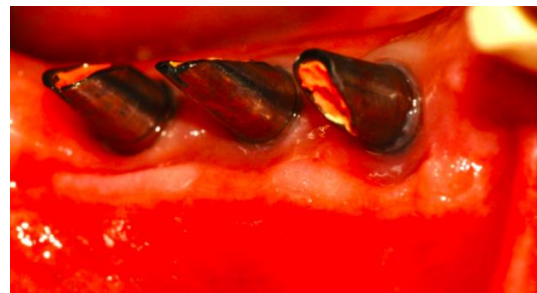

Fig. 21. Results after one month.

A 16-year follow-up demonstrated good results over time (Fig. 22, Fig. 23).

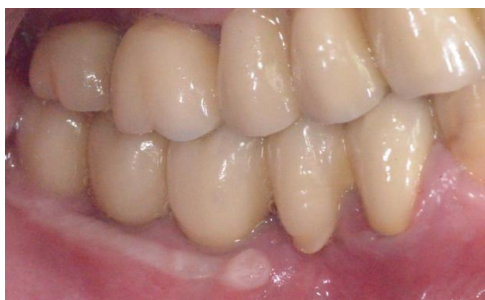

Fig. 22. Intra-oral follow-up.

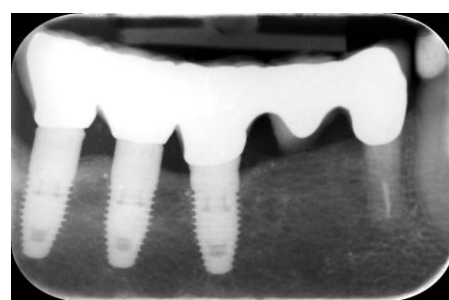


Fig. 23. X-Ray follow-up.

DISCUSSION

Many techniques have been developed in implantology to rehabilitate areas where bone width is insufficient due to bone atrophy. Among these, autogenous grafts are still considered the gold standard. Still, many studies have shown that SCT has numerous advantages, such as lower operating times, no need for a second surgical site, lower overall costs, no need for a second surgical time to insert implants, and lower patient complication risks.

The SCT proved viable and predictable, enabling a significant increase in ridge thickness and a high percentage of implant survival (14). It is recommended to treat width augmentation in areas of bone atrophy where the remnant thickness is around 3.0 mm (in such cases, the bone is easier to expand, and there is a lower fracture risk since it is more pliable).

Studies have also shown that this technique is especially useful for distal segments of the mandible (15). However, the mandible is the most affected area when it comes to unintended fracture of the vestibular segment (16). This can be attributed to the fact that the mandibular cortex is thicker and more brittle, so it is harder to split, resulting in a higher risk of fracture. The bone lacks elasticity when bone quality is reduced because the medullary layer is very thin. This can lead to fractures responsible for the loss of primary stability of implants (17). To prevent fracture, a longitudinal basal notch can be created on the surface of the vestibular bone. Even if a fracture occurred in the SCT, sufficient volume of the alveolar bone could be obtained without any rigid fixation of a free bone segment, and the dental implants placed within the fracture area showed a good prognosis (16). In addition, studies have shown that SCT with inlay bone block grafts promotes both the augmentation of hard tissues and the augmentation of soft tissues.

A low keratinized mucosa exposes a high risk of gingival recession and crestal bone loss. On the other hand, a correct amount of keratinized mucosa guarantees the maintenance of long-term stability, the aesthetic results of the implant, and an optimal blood supply. The correct blood supply is essential for wound healing without infections, and proper wound healing means keratinized mucosa gain (18).

According to the literature, the survival rate of implants installed in sites where the SCT was conducted varies from 93% to 100% (12).

SCT can be performed with many different instruments. One of the most advantageous is piezoelectric surgery. Its benefits are reduced bone consumption (≤ 0.5 mm) and selective cuts (i.e. bone can be cut, whereas soft tissues,

including blood vessels, nerves, and mucosal tissues, remain unharmed) (19). In addition, the cavitation effect of piezoelectric devices increases visibility, and the vibrating tip can penetrate up to 12 mm of bone without risk of bone overheating (when gentle coming and going movements are performed) (20). A case report published in 2008 demonstrated that piezoelectric surgery used to perform SCT allowed a 4.8 mm ridge augmentation and contextual insertion of 3 implants with a safe and comfortable procedure (17). In 2005, an article that analyzed 230 clinical sites was published, demonstrating that the SCT with ultrasonic devices was highly predictable as 99.1% of the planned implants were successfully placed (20). In 2016, a systematic review (21) demonstrated that SCT effectively increases bone thickness; the average bone gain is 3.8 mm, independent of the surgical instruments used to cut bone.

The results of this case report agree with the literature, as the SCT performed using an ultrasonic device was successful, and the follow-up 16 years after the implants were placed shows that they are still stable.

REFERENCES

1. Johnson K. A study of the dimensional changes occurring in the maxilla following tooth extraction. *Aust Dent J*. 1969;14(4):241-244. doi:<https://doi.org/10.1111/j.1834-7819.1969.tb06001.x>
2. Pietrokovski J, Massler M. Alveolar ridge resorption following tooth extraction. *J Prosthet Dent*. 1967;17(1):21-27. doi:[https://doi.org/10.1016/0022-3913\(67\)90046-7](https://doi.org/10.1016/0022-3913(67)90046-7)
3. Schropp L, Wenzel A, Kostopoulos L, Karring T. Bone healing and soft tissue contour changes following single-tooth extraction: a clinical and radiographic 12-month prospective study. *Int J Periodontics Restorative Dent*. 2003;23(4):313-323.
4. Branemark PI, Adell R, Breine U, Hansson BO, Lindstrom J, Ohlsson A. Intra-osseous anchorage of dental prostheses. I. Experimental studies. *Scand J Plast Reconstr Surg*. 1969;3(2):81-100. doi:<https://doi.org/10.3109/02844316909036699>
5. Nedir R, Bischof M, Briaux JM, Beyer S, Szmukler-Moncler S, Bernard JP. A 7-year life table analysis from a prospective study on ITI implants with special emphasis on using short implants. Results from private practice. *Clin Oral Implants Res*. 2004;15(2):150-157. doi:<https://doi.org/10.1111/j.1600-0501.2004.00978.x>
6. Felice P, Pistilli R, Lizio G, Pellegrino G, Nisii A, Marchetti C. Inlay versus onlay iliac bone grafting in atrophic posterior mandible: a prospective controlled clinical trial for comparing two techniques. *Clin Implant Dent Relat Res*. 2009;11 Suppl 1(e69-82. doi:<https://doi.org/10.1111/j.1708-8208.2009.00212.x>
7. Misch CM. Comparison of intraoral donor sites for onlay grafting prior to implant placement. *Int J Oral Maxillofac Implants*. 1997;12(6):767-776.
8. Pikos MA. Block autografts for localized ridge augmentation: Part I. The posterior maxilla. *Implant Dent*. 1999;8(3):279-285. doi:<https://doi.org/10.1097/00008505-199903000-00009>
9. Pikos MA. Block autografts for localized ridge augmentation: Part II. The posterior mandible. *Implant Dent*. 2000;9(1):67-75. doi:<https://doi.org/10.1097/00008505-200009010-00012>
10. Melcher AH. On the repair potential of periodontal tissues. *J Periodontol*. 1976;47(5):256-260. doi:<https://doi.org/10.1902/jop.1976.47.5.256>
11. Nentwig GH. [Technic of bone splitting for alveolar recession in anterior maxillary region]. *Quintessenz*. 1986;37(11):1825-1834.
12. Scipioni A, Bruschi GB, Calesini G, Bruschi E, De Martino C. Bone regeneration in the edentulous ridge expansion technique: histologic and ultrastructural study of 20 clinical cases. *Int J Periodontics Restorative Dent*. 1999;19(3):269-277.
13. Thoma DS, Naenni N, Figuero E, et al. Effects of soft tissue augmentation procedures on peri-implant health or disease: A systematic review and meta-analysis. *Clin Oral Implants Res*. 2018;29 Suppl 15(32-49. doi:<https://doi.org/10.1111/clr.13114>
14. de Souza CSV, de Sa BCM, Goulart D, Guillen GA, Macedo FGC, Noia CF. Split Crest Technique with Immediate Implant to Treat Horizontal Defects of the Alveolar Ridge: Analysis of Increased Thickness and Implant Survival. *J Maxillofac Oral Surg*. 2020;19(4):498-505. doi:<https://doi.org/10.1007/s12663-020-01332-z>
15. Agabiti I, Botticelli D. Two-Stage Ridge Split at Narrow Alveolar Mandibular Bone Ridges. *J Oral Maxillofac Surg*. 2017;75(10):2115 e2111-2115 e2112. doi:<https://doi.org/10.1016/j.joms.2017.05.015>
16. Shibuya Y, Yabase A, Ishida S, Kobayashi M, Komori T. Outcomes and treatments of mal fractures caused by the split-crest technique in the mandible. *Kobe J Med Sci*. 2014;60(2):E37-42.
17. Belleggia F, Pozzi A, Rocci M, Barlattani A, Gargari M. Piezoelectric surgery in mandibular split crest technique with immediate implant placement: a case report. *Oral Implantol (Rome)*. 2008;1(3-4):116-123.
18. Guo Z, Chen L, Ning Y, et al. Split-crest technique with inlay bone block grafts for narrow posterior mandibles: a retrospective clinical study with a 3-year follow-up. *Am J Transl Res*. 2020;12(8):4628-4638.
19. Stubinger S, Robertson A, Zimmerer KS, Leiggenger C, Sader R, Kunz C. Piezoelectric harvesting of an autogenous bone graft from the zygomaticomaxillary region: case report. *Int J Periodontics Restorative Dent*. 2006;26(5):453-457.

20. Blus C, Szmukler-Moncler S. Split-crest and immediate implant placement with ultra-sonic bone surgery: a 3-year life-table analysis with 230 treated sites. *Clin Oral Implants Res.* 2006;17(6):700-707. doi:<https://doi.org/10.1111/j.1600-0501.2006.01206.x>
21. Waechter J, Leite FR, Nascimento GG, Carmo Filho LC, Faot F. The split crest technique and dental implants: a systematic review and meta-analysis. *Int J Oral Maxillofac Surg.* 2017;46(1):116-128. doi:<https://doi.org/10.1016/j.ijom.2016.08.017>