

QUAD ZYGOMATIC IMPLANTS: CASE SERIES

L. Tomaselli

Correspondence to:

Luigi Tomaselli, DDS, MS

Private practice,

Via Azzurra 26,

40138 Bologna, Italy

e-mail: gigitomaselli@gmail.com

ABSTRACT

Zygomatic implants (ZI) represent a groundbreaking advancement in the field of dental implantology. These specialized implants offer a viable solution for individuals with severe maxillary atrophy, where conventional implants may not be feasible. ZI are typically longer than conventional dental implants, ranging from 30 to 55 mm. They are anchored in the zygomatic bone, a dense and sturdy structure in the upper jaw. We reported a case series and discussed the literature.

KEYWORDS: *dental implants, maxillary atrophy, surgical technique, survival rate, zygomatic implants*

INTRODUCTION

Zygomatic implants (ZI) are indicated for patients with severe maxillary atrophy, eliminating the need for bone grafting (1-5). Understanding the intricate anatomy of the maxillary region is crucial for successful ZI placement. Variations in bone density, sinus morphology, and facial anatomy influence the feasibility and success of ZI procedures. The zygomatic bone plays a pivotal role in zygomatic implantology. Its robust structure provides a stable foundation for implant placement.

Variations in zygomatic bone anatomy must be considered during the planning and execution of ZI surgeries. ZI are longer than conventional dental implants, typically ranging from 30 to 60 mm. The surgical procedure involves precise placement in the zygomatic bone, avoiding critical structures such as the maxillary sinus and neurovascular bundles. Surgical techniques, including the sinus lift and intraoral approaches, demand a comprehensive understanding of maxillary anatomy.

Anatomical variations in the maxilla, such as pneumatization of the maxillary sinus and the presence of bony septa, can complicate ZI placement. Preoperative imaging is essential for assessing individual anatomical variations and tailoring the surgical approach accordingly.

Recent systematic reviews have defined the advantages of ZI. Wang et al. (2) assessed the predictability of ZI in regard to implant survival, technical and biological complications, and quality of life. ZI survival rate was 96.7%. Only a limited number of surgical complications were reported, with orbital perforation the most significant. Similar results were obtained for prosthetic complications (few occurrences). Additionally, patient satisfaction levels were high, approaching that of the general population. The authors concluded that maxillary rehabilitation by four ZI with no anterior support is a reliable approach.

Aboul-Hosn Centenero et al. (3) reviewed and compared the survival rates (SRs) of oral rehabilitations performed with 2 ZI combined with regular implants (RIs) versus 4 ZI. ZIs SR was 98.0%. For the control group (2 ZIs + 2 RIs) and the test group (4 ZIs), the implant SR was 98.6% and 97.4%, respectively. No statistically significant

differences in terms of SRs were obtained between both groups. The results showed no statistical differences in using one or another treatment in terms of survival and failure rates. Reducing treatment time and morbidity related to regenerative approaches may be its main advantage. In conclusion, the zygoma quad seems to be the treatment of choice for the rehabilitation of the severely atrophic maxilla.

Gracher et al. (4) presented the treatment outcomes with ZI in rehabilitating the atrophic upper jaw. The survival rate of ZI was 98.22%. Different surgical techniques were used to place ZIs; however, the intrasinus technique was the most used, and post-surgical sinusitis was the most common complication reported in the studies.

Solà Pérez et al. (5) performed a systematic review on ZI. The cumulative success rate of ZI for the treatment of severe maxillary atrophy was 98.5% at less than one year, 97.5% between 1 and 3 years, 96.8% between 3 and 5 years, and 96.1% after more than 5 years. The most commonly reported complications were soft tissue dehiscence, rhinosinusitis, and prosthetic failures. The treatment of severe lack of bone in the upper maxilla with ZI is a safe procedure, reaching a cumulative success rate of 96.1% after more than 5 years.

ZI offers several advantages, including reduced treatment time, avoidance of bone grafting procedures, and immediate loading capabilities. Immediate loading of ZI is a viable option in select cases. The biomechanics of ZI are influenced by their unique placement in the zygomatic bone, contributing to enhanced stability and long-term success. While ZI exhibits high success rates, clinicians must be vigilant regarding potential complications. Complications may include sinus-related issues, nerve damage, and implant failure. Long-term success studies provide insights into the durability and stability of zygomatic implant-supported prostheses (2-5). These studies track patient outcomes, implant survival rates, and potential complications over extended periods, contributing to the evidence base supporting the efficacy of ZI.

Regarding surgical procedures, one of the common techniques for zygomatic implant placement is the classical sinus lift approach. This involves accessing the zygomatic bone through a lateral window created in the maxillary sinus. Careful elevation of the sinus membrane allows for the insertion of the zygomatic implant. The intraoral approach is an alternative method involving access through the alveolar crest. This approach minimizes the need for external incisions and provides a more direct path to the zygomatic bone.

Advances in minimally invasive techniques have further refined the intraoral approach. In some instances, extra-maxillary techniques may be employed, allowing for zygomatic implant placement without entering the maxillary sinus. These techniques, such as the zygomatic tubercle approach, offer alternative paths to the zygomatic bone, reducing the risk of sinus-related complications. Here, we report a case series and review the literature.

CASE REPORT

Case 1

G.C., a 74-year-old nonsmoker female, came to our Clinic complaining about her smile. She had a far-advanced periodontal disease (Fig. 1-10). After careful examination, a full arch rehabilitation using zygomatic implants was performed. The prosthesis was delivered immediately after the intervention, and the patient was uneventful after 18 months.

After locoregional anesthesia and extraoral zygoma anesthesia, a full-thickness flap is elevated with vertical

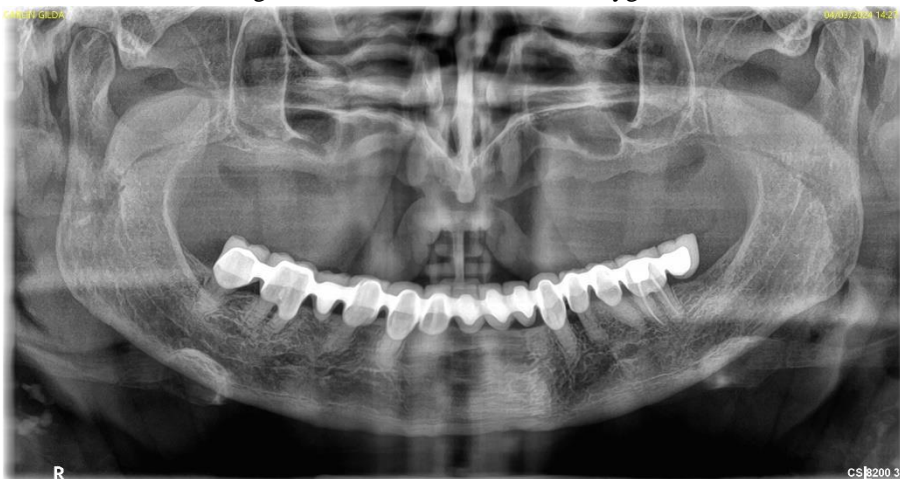

Fig. 1. Pre X-ray.

release incisions in the nasal spine and distal to the zygomatic pillar.

The approach is one emi-maxilla at a time; skeletonization reaches the piriform opening, the infra-orbit nerve proceeds to the inferior orbital border and continues through the zygomatic plate until the zygomatic arch, where the superficial fibers of the masseter muscles are cut to increase the possibility of view in the orbit border and the distal part of the zygomatic surface.

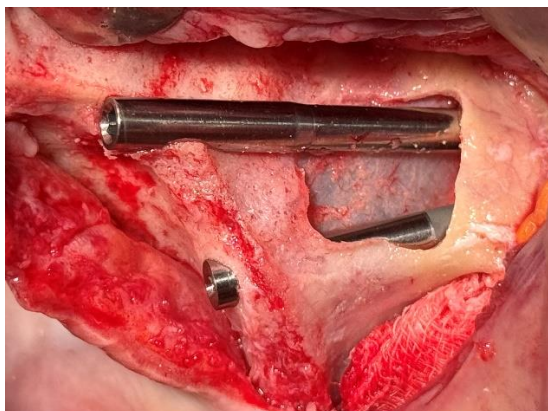


Fig. 2. *Sparing of the left sinus wall.*

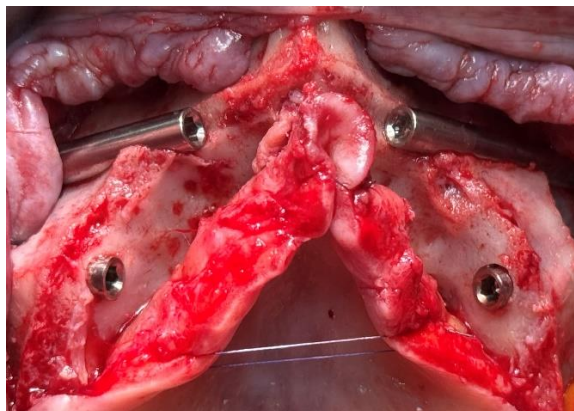


Fig. 3. *Positioning of zygomatic implant*

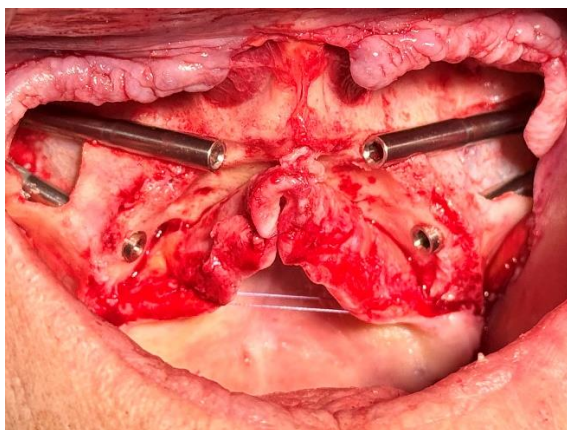


Fig. 4. *Frontal view*

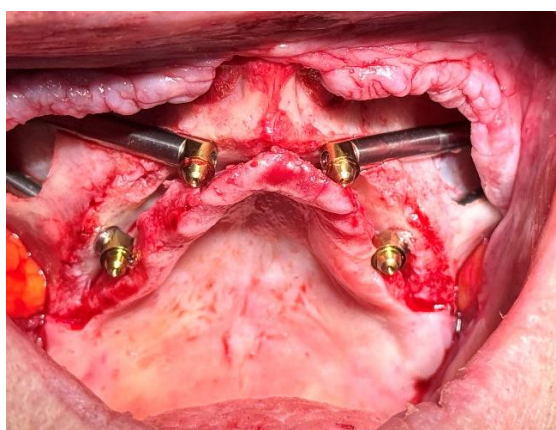


Fig. 5. *MUA tightening*

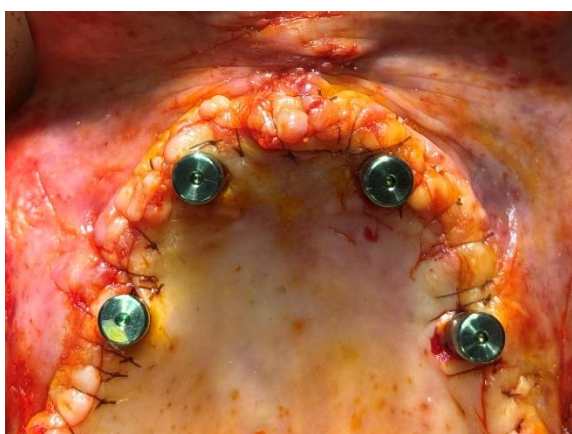

Fig. 6. *Soft tissue management*

The antrostomy is done in the upper part of the sinus close to the plateau of the zygomatic bone surrounding the sinus roof, and the Schneiderian membrane is carefully detached. Choosing the exit of our zygomatic implant in the alveolar ridge according to the ideal line, which is that the implant should not have invaded the orbit border or the infra-orbital nerve, is a key point. The slots are then prepared, creating a precise accommodation in the bone for the implant. The zygomatic bone is then approached with the burs, having care of working in and out so as not to overheat the bone and not to change the axis because the implant does not have to bend when placed.

Finally, implants are tightened, reaching torques close to 80Ncm easily. The other hemimaxilla is mirrored.

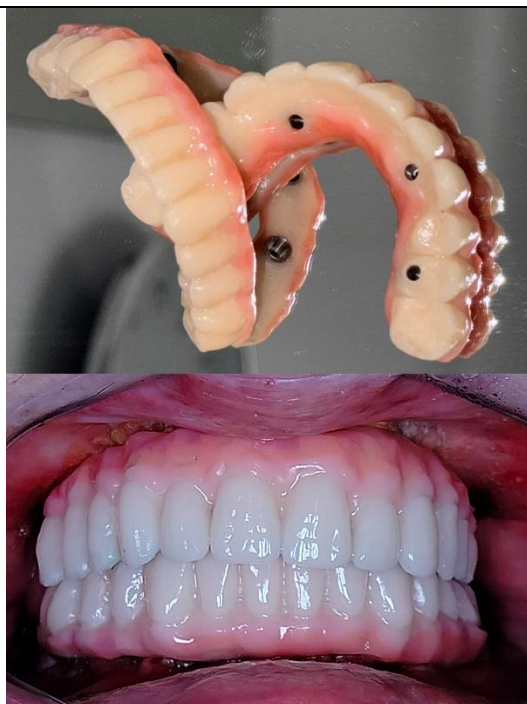


Fig. 7. *Prosthesis.*

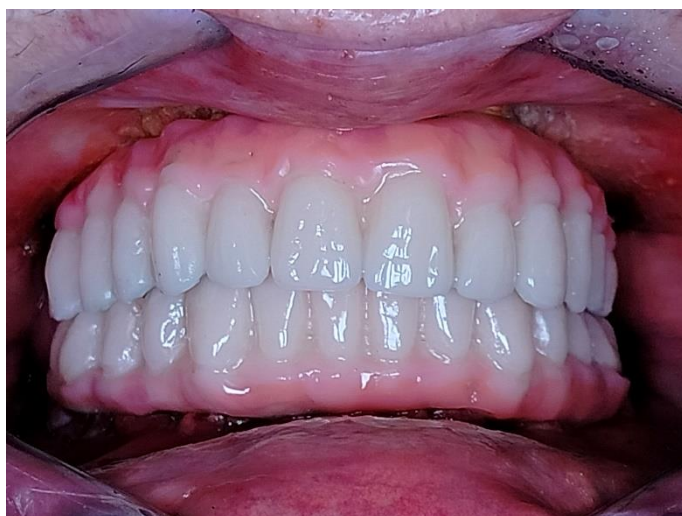

Fig. 8. *Delivery of the full arches.*

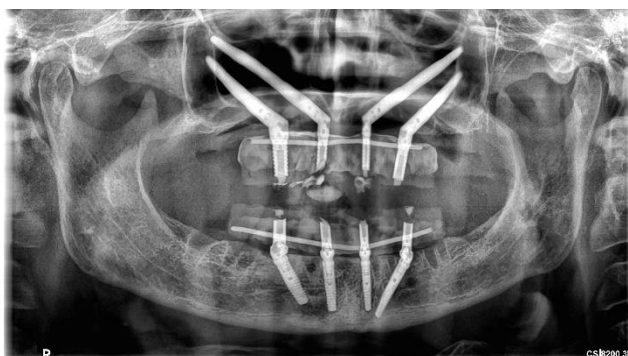


Fig. 9. *X-ray at 12-month follow-up.*

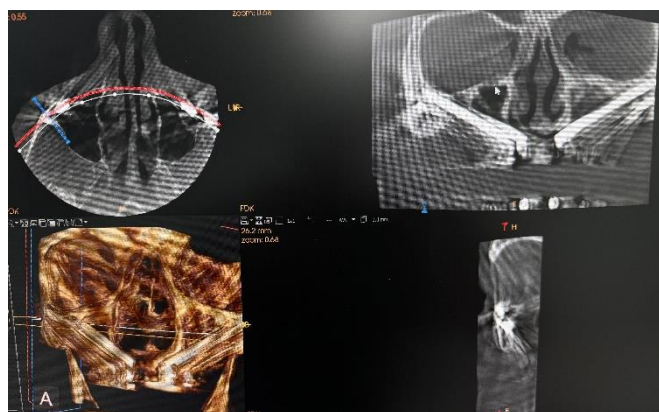


Fig. 10. *CBCT at 12-month follow-up.*

Case 2

P.S., a 69-year-old non-smoker female came to our Clinic complaining about her smile. She was almost without teeth (Fig. 11-18). After careful examination, a full arch rehabilitation using zygomatic implants was performed. The prosthesis was delivered immediately after the intervention, and post-delivery was uneventful.

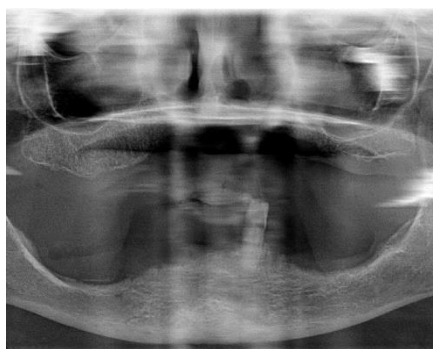

Fig. 11. *Pre X-ray.*

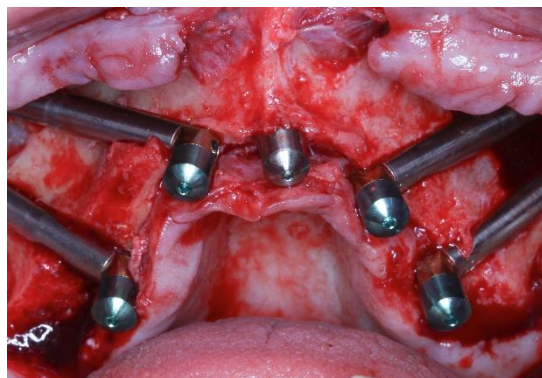


Fig. 12. Zygomatic implants frontal view.

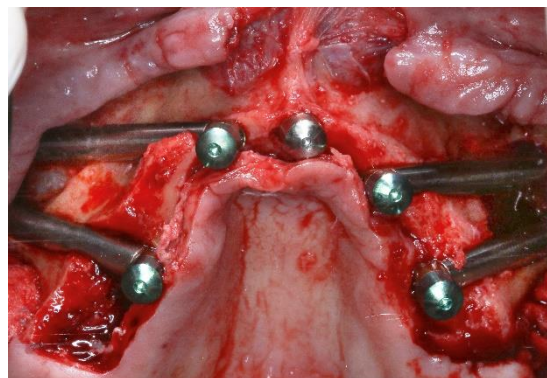


Fig. 13. Zygomatic implant occlusal view.

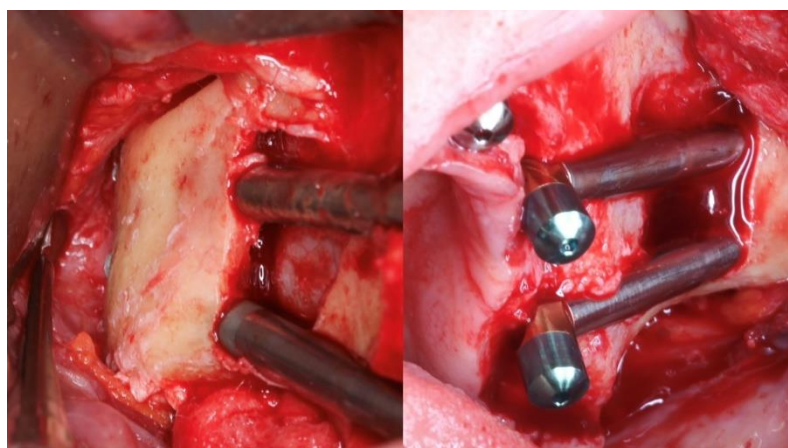


Fig. 14. Details of bicortical zygomatic bone.

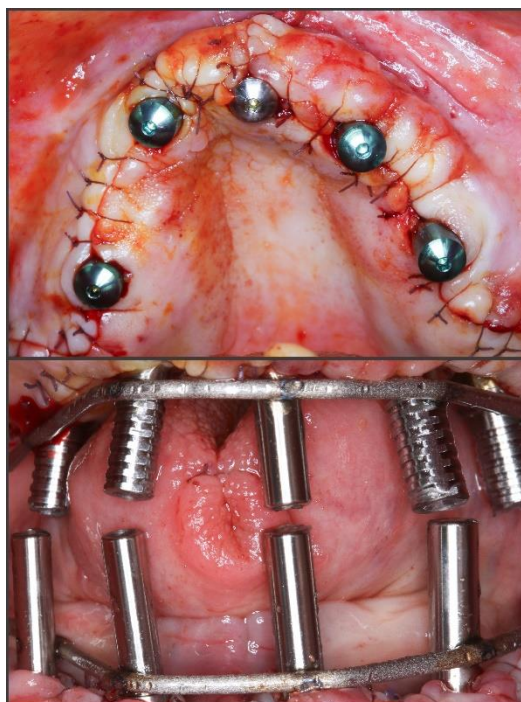


Fig. 15. Soft tissue management and intraoral welding.

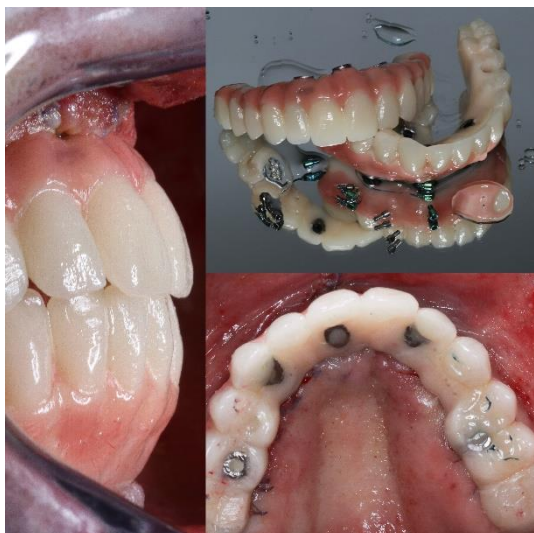

Fig. 16. *Durable prosthesis.*

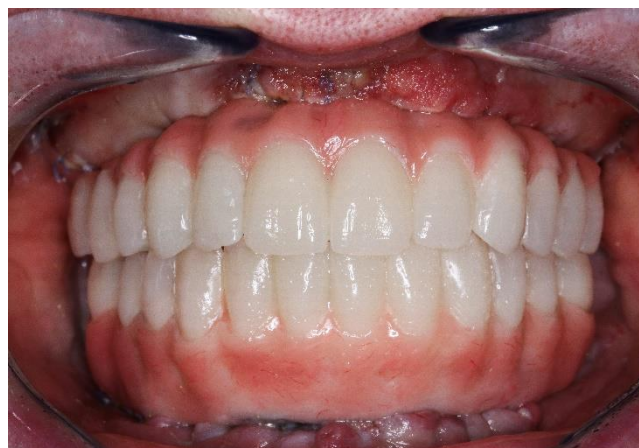

Fig. 17. *Delivery of prosthetic full arches.*

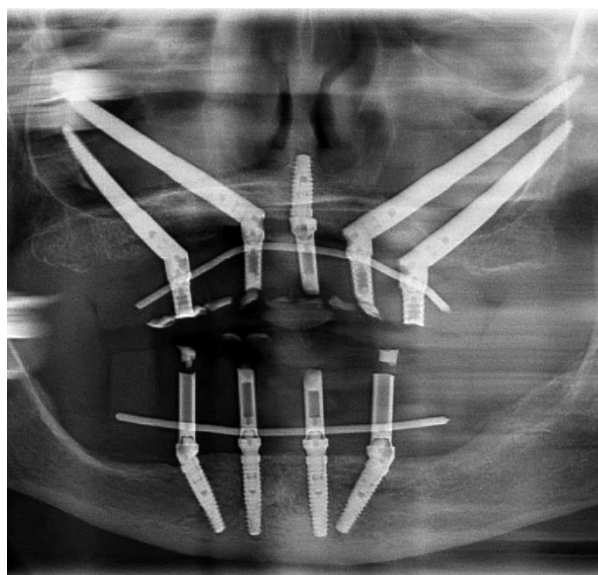


Fig. 18. *Twelve-month RX follow-up.*

Finally, a prosthesis was delivered. Then the MUA are positioned, and intraoral welding is performed after a 1st intention sutures around healing pillars; the impression is taken for the prosthesis, and the prosthetic durable device is delivered by the afternoon. In addition, a Toronto Bridge on 4 implants was performed in lower jaw.

Case 3

M.M., a 58-year-old female patient who is a smoker, came to our Clinic complaining about her smile. She was edentulous (Fig. 19-30). After careful examination, a full arch rehabilitation using zygomatic implants was performed, and a Toronto Bridge on 4 implants was carried out in the mandible. The prosthesis was delivered immediately after the intervention, and post-delivery was uneventful.

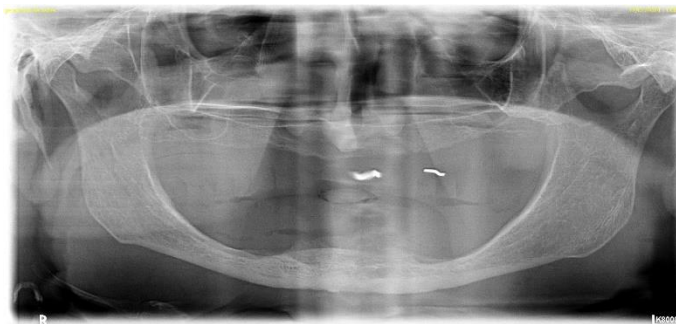

Fig. 19. *Pre X-ray.*

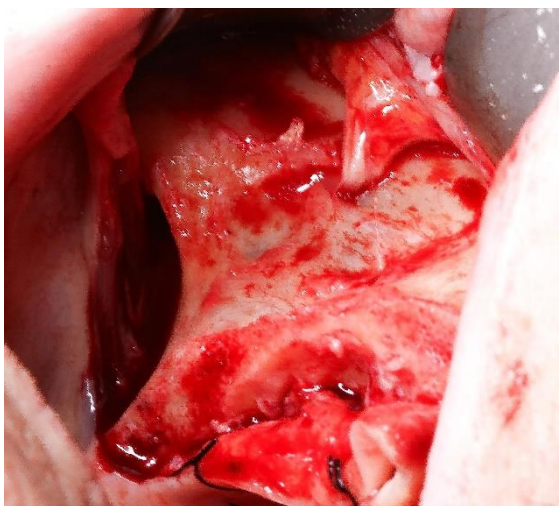


Fig. 20. *Right zygomatic bone exposed.*

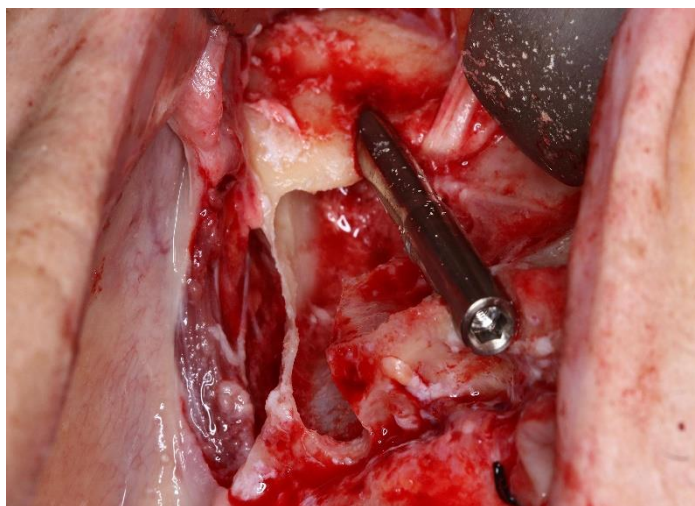


Fig. 21. *Right medial zygomatic implant inserted.*

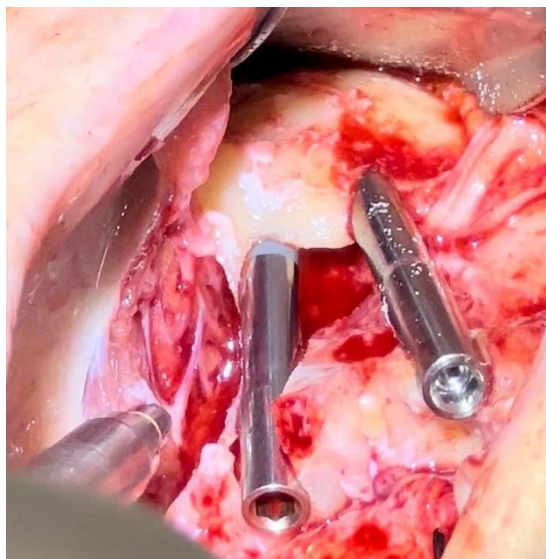


Fig. 22. *Right hemimaxilla with 2 Zis.*

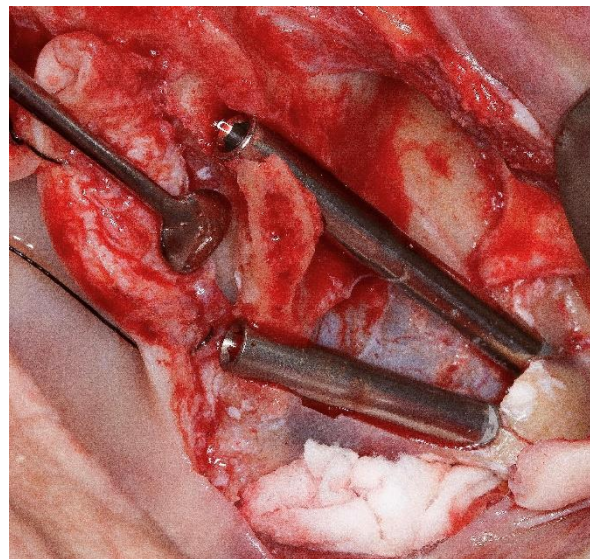


Fig. 23. *Left hemimaxilla with 2 ZIs.*

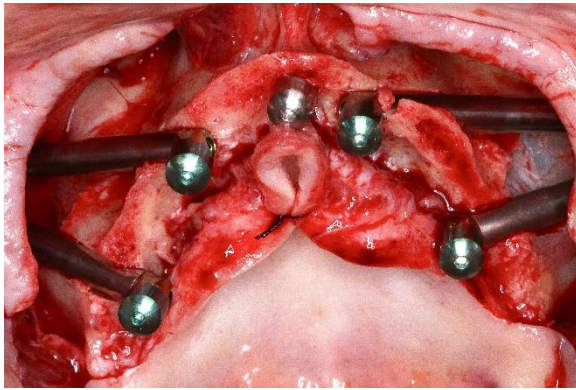


Fig. 24. *Implants of 4 ZIs positioned plus 1 standard implant in Medline under anterior nasal spine.*

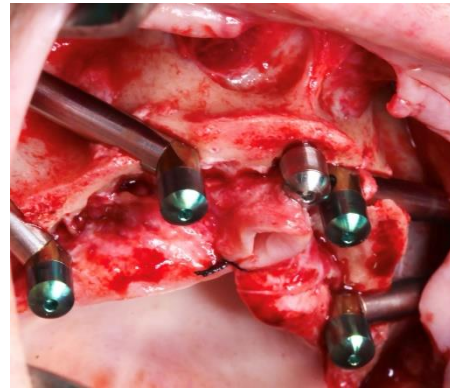


Fig. 25. *Lateral view.*

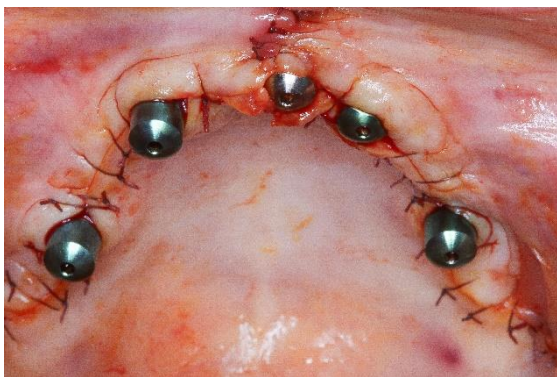


Fig. 26. *Suture.*

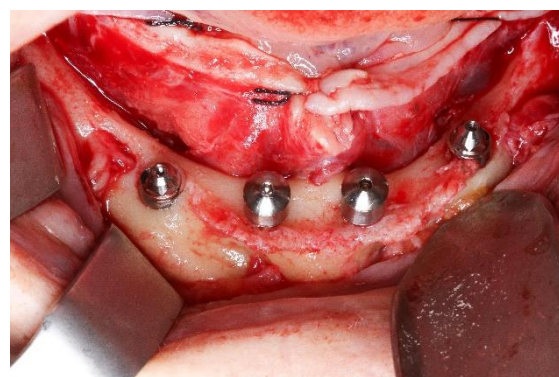


Fig. 27. *Lower jaw with 4 implants inserted.*

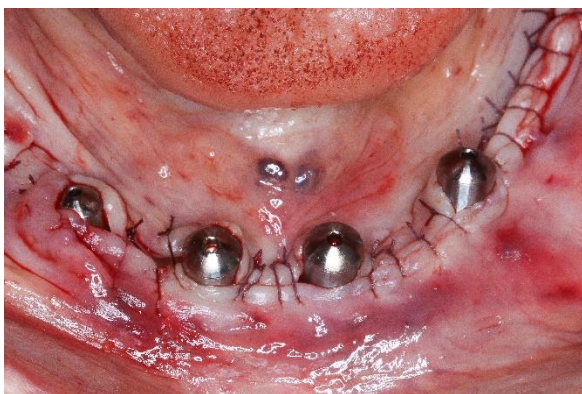

Fig. 28. *Lower jaw suture with mucosa sutured.*

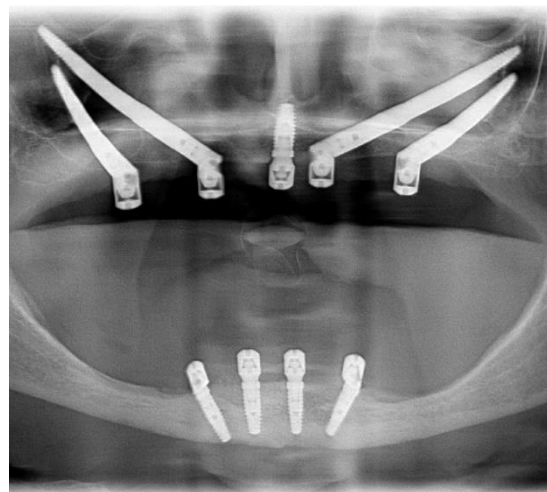


Fig. 29. *Post-operative X-ray.*

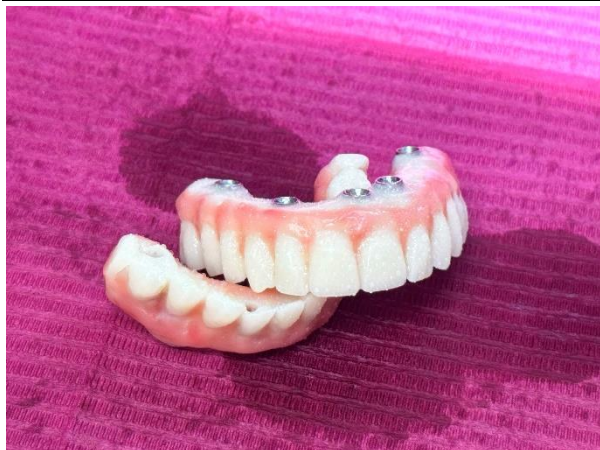

FIG. 30. *Prosthesis.*

DISCUSSION

The placement of ZI has emerged as a transformative solution for individuals with severe maxillary atrophy. Severe maxillary atrophy, characterized by extensive bone resorption in the upper jaw, is a primary indication of ZI. The assessment of atrophy severity through imaging techniques, such as cone-beam computed tomography (CBCT), guides clinicians in determining the appropriateness of ZI for a given patient. Patients with insufficient bone volume for traditional implant placement due to atrophy are ideal candidates for ZI. These implants bypass the need for bone grafting, providing a more efficient solution.

Computer-planned implant insertion is a procedure well established. Advancements in guided surgery and virtual planning tools enhance precision in patient selection. Virtual simulations allow for meticulous preoperative assessment, contributing to improved outcomes. Varghese et al. (6) reviewed prosthetic and zygomatic implant success of treating severe maxillary resorption with prostheses supported by 4 ZI. All prostheses were immediately loaded with acrylic resin interim prostheses replaced by a definitive prosthesis, which consisted of overdentures retained by bar splinting (n=2), metal bar-reinforced prostheses (n=2), fixed screw-retained acrylic resin prostheses (n=34), and screw-retained titanium prostheses with ceramic or acrylic resin teeth (n=75).

Technical complications of ZI included mobility associated with a machined surface and fracture of the abutment screw. The most common prosthetic complications reported were fracture of the definitive prosthesis and loss of the interim prosthesis subsequent to the failure of at least one ZI. The results showed that prostheses supported by quad ZIs displayed an overall success of 100%, whereas ZI showed a survival rate of 98% with minimal implant failures and few complications.

Fan et al. (7) investigated the accuracy of ZI placement using dynamic computer-aided surgery (d-CAIS), static computer-aided surgery (s-CAIS), and a free-hand approach in patients with severe atrophic edentulous maxilla and/or deficient maxilla. There was strong evidence of differences in the average entry, apex, and angular deviation between the navigation, surgical guide, and free-hand groups (the last being the worst). Using d-CAIS and modified s-CAIS for ZI surgery has shown clinically acceptable outcomes regarding average entry, apex, and angular deviations. The maximal deviation values were predominantly observed in the conventional s-CAIS. Surgeons should be mindful of potential deviations and complications, using different guide approaches, regardless of the decision-making process.

Ramezanzade et al. (8) reviewed the accuracy and complications (including failure) of dynamic navigation in placing ZI. The authors concluded that the application of dynamic navigation systems is a reliable technology for ZI placement, especially in difficult cases with a history of maxillary deficiency.

One notable advantage of ZI is the ability to provide immediate and efficient rehabilitation for patients with severe maxillary atrophy. Unlike traditional implant procedures that may require extensive bone grafting and prolonged healing periods, ZI offers a streamlined approach. Avoiding grafting procedures significantly reduces treatment time, allowing for the immediate placement of prostheses and rapid restoration of oral function and aesthetics. The avoidance of bone grafting and the ability to perform immediate loading contributes to a reduction in overall treatment complexity. ZI simplifies the rehabilitation process for patients with severe maxillary atrophy, making it a more accessible and efficient option. This reduction in treatment complexity is particularly beneficial for individuals who may be hesitant about undergoing extensive surgical procedures.

Polido et al. (9) investigated the indications for placement of ZI to rehabilitate edentulous maxillae. ZI indications were extreme bone atrophy or deficiency secondary to different factors. The quad zygoma concept (two ZI bilaterally placed and splinted) was applied to 107 patients, the classic zygoma concept (one zygomatic implant bilaterally placed and splinted to standard anterior implants) was used in 88 patients, and the unilateral concept (one zygomatic implant on one side, splinted with one or more conventional implants) was employed in 14 patients. The authors concluded that the main indication for using ZI was extreme maxillary bone atrophy, resulting from many factors. The definition of "extreme bone atrophy" is not uniquely defined in each paper.

Tuminelli et al. (10) systematically reviewed the outcome of immediately loaded ZI. They found that immediately loading ZI to restore the severely atrophic maxilla presents a viable alternative for the treatment of the

atrophic maxilla. Lorusso et al. (11) evaluated the survival rate of ZI in conjunction with regular fixtures for maxillary rehabilitation. There was a similar implant survival rate between zygomatic and premaxilla regular implants.

Sáez-Alcaide et al. (12) assessed the effect of rehabilitation with ZI on patient's quality of life. General findings of this systematic review showed substantial increases in oral health-related quality of life among patients restored with ZI and high scores in terms of general satisfaction, especially in chewing ability and esthetics. Brennan Roper et al. (13) performed a systematic review on the long-term survival rates of ZI. ZI success, prostheses survival and success, sinus pathology, and patient-reported outcomes were also investigated. They found a mean follow-up period of 75.4 months. The mean survival of ZIs was 96.2% at 6 years. Mean survival for delayed loading was 95% and 98.1% for immediate loading. The mean ZI success was 95.7%. Mean prosthesis survival was 94%. Sinusitis prevalence was 14.2% at 5 years. Consequently, the Authors concluded that ZIs have long-term survival comparable to conventional implants. Immediate loading showed a statistically significant increase in survival over delayed loading. Prosthesis survival was similar to prostheses supported by conventional implants, but with similar complications. Sinusitis was the most frequently encountered biological complication.

ZI has revolutionized oral rehabilitation, particularly in cases of severe maxillary atrophy. However, like any surgical procedure, zygomatic implant placement is not without potential complications. One notable concern in zygomatic implant surgery involves potential sinus-related complications. These can range from sinus membrane perforation during implant placement to postoperative issues such as sinusitis.

Chrcanovic et al. (14) investigated the most common complications related to ZI surgery. They analyzed thirty-seven studies. Postoperative complications reported were as follows: 70 cases of sinusitis, 48 of soft tissue infection, 15 of paresthesia, and 17 cases of oroantral fistulas. However, this number may be underestimated since most of the studies did not mention the presence or absence of these complications. Most ZI failures were detected at the abutment connection phase (6 months after implant placement surgery) or before. The cumulative survival rate over 12 years was 96.7 %.

Chrcanovic et al. (15) assessed the survival rate of ZI and the prevalence of complications based on previously published studies. Sixty-eight studies comprised 4,556 ZIs in 2,161 patients with 103 failures. The 12-year cumulative survival rate was 95.21%. Most failures were detected within the 6-month postsurgical period. Studies that exclusively evaluated immediate loading showed a statistically lower ZI failure rate than studies evaluating delayed loading protocols. The probability of presenting postoperative complications with ZIs was as follows: sinusitis, 2.4%; soft tissue infection, 2.0%; paresthesia, 1.0%; and oroantral fistulas, 0.4%. However, these numbers might be underestimated because many studies failed to mention the prevalence of these complications.

Molinero-Mourelle et al. (16) analyzed the most frequent surgical complications associated with the use of ZI. Of the most frequent surgical complications, sinusitis (3,9%) and failure in osseointegration (2.44%) are highlighted. Lan K et al. (17) investigated the postoperative complications and outcome (implant survival) of quad ZI inserted in patients with edentulism and severely atrophic maxillae. The incidence rates of complications were as follows: sinusitis 12%, malposition and surgical guiding failure 11%, local infection/injury 10%, and prosthetic complications 5%. The implant survival rate ranged between 95.8% and 100%. Quad ZI inserted in patients with severely atrophic edentulous maxillae have a high implant survival rate, but the incidence of complications should not be underestimated.

Tavelli et al. (18) evaluated the survival and complication rate of ZI, assessing factors (such as surgical technique, surgical/restorative plan, population, study design, and characteristics, etc.) associated with these outcomes. The mean survival rate among studies was about 98%. The survival rate was neither associated with the surgical technique nor the surgical/restorative plan. Forty-eight articles reported data on complications related to ZI, with labial laceration, orbital cavity penetration, hematoma, epistaxis, maxillary sinusitis, infection, and oro-antral communication being among the most common adverse events. A lower incidence of maxillary sinusitis was observed for ZI placed using the extra sinus approach compared to the other surgical techniques. The incidence of maxillary sinusitis and oro-antral communications were less likely in "recent" vs "less recent" studies.

Gabriele et al. (19) investigated the probability of postoperative complications at both the implant and patient level for each of the four surgical techniques for zygomatic implant (ZI) placement: Brånemark, sinus slot, extra sinus, and extra maxillary. They concluded that ZI placement was demonstrated to be a reliable technique for the rehabilitation of severely atrophic maxillae, irrespective of the surgical technique evaluated. Accurate case and surgical protocol selection is paramount to reducing technique-related postoperative complications.

Kämmerer et al. (20) assessed the outcome of ZI and complications of the original surgical technique (OST) and an Anatomy-Guided approach (AGA) in the placement of ZI in patients with severely atrophic maxillae. They verified that placing ZI in severely atrophic edentulous maxillae rehabilitation with the OST and AGA is associated with a high implant survival rate and surgical complications within a minimum of 6 months follow-up. Complications, including sinusitis and soft tissue infection around the implant, are the most common. The utilization of immediate loading protocol

is more observed in AGA than in OST. ZI can be installed inside the maxillary sinus, called intrasinus zygomatic implant (IZI), or outside the maxillary sinus (EZI), depending on the surgery technique. Moraschini et al. (21) observed no statistically significant between ZI and CI in prospective studies. The biological complications most related to ZI was sinusitis, followed by infection and oroantral communication. The authors concluded that ZI has a high long-term survival rate (96.5% with a mean of 91.5 months of follow-up), showing no significant difference compared to conventional implants. The most prevalent biological complication is sinusitis, commonly in the IZI technique.

Rigorous preoperative assessment of maxillary sinus anatomy, aided by advanced imaging modalities like cone-beam computed tomography (CBCT), is crucial. Additionally, employing careful surgical techniques, such as the use of proper instruments and grafting materials in the presence of sinus perforation, can mitigate these complications. The proximity of ZI to critical neurovascular structures raises the risk of nerve damage during surgery. The infraorbital nerve and other branches in the maxillary region must be carefully considered to prevent sensory disturbances or paresthesia.

Meticulous surgical planning, guided surgery technologies, and intraoperative monitoring contribute to minimizing the risk of nerve-related complications. Close collaboration between oral surgeons and neurosensory specialists is essential in addressing and managing postoperative sensory issues. While ZI generally exhibits high success rates, various factors can contribute to implant failure. Inadequate primary stability, poor bone-implant contact, and biomechanical challenges may compromise the long-term success of ZI. Thorough preoperative planning, including precise bone quality and quantity assessment, is crucial. Postoperative care, regular follow-ups, and patient compliance with oral hygiene protocols contribute to identifying and addressing potential issues early on. Infection and peri-implantitis are potential complications that can compromise the success of ZI. Maintaining meticulous oral hygiene, both preoperatively and postoperatively, is crucial in preventing bacterial colonization. Regular professional cleanings and patient education on oral care practices contribute to reducing the risk of infection. In cases where peri-implantitis occurs, prompt diagnosis and intervention, including debridement and antibiotic therapy, are essential for implant preservation.

CONCLUSIONS

The advantages of ZI make them a compelling solution for individuals facing the challenges of severe maxillary atrophy and complex oral rehabilitation scenarios. The streamlined treatment process, elimination of bone grafting, increased stability, and versatility in addressing diverse clinical situations collectively position ZI as a transformative option in implant dentistry. The surgical procedures of ZI involve a meticulous and multidisciplinary approach, and a thorough understanding of potential complications and considerations is paramount. The meticulous assessment of anatomical factors, careful surgical planning, and ongoing postoperative care contribute to the success of ZI procedures. Studies consistently report high implant survival rates for ZI.

The robust anchorage in the zygomatic bone contributes to the stability of these implants. Research spanning a decade indicates survival rates well above 90%, showcasing the durability of zygomatic implant-supported prostheses. Long-term follow-up studies focus on implant survival and the functionality and performance of zygomatic implant-supported prostheses. Patients often experience restored oral function, including improved masticatory efficiency and speech. The longevity of prosthetic rehabilitation contributes significantly to the overall success and satisfaction of ZIs. The aesthetic outcomes of zygomatic implant-supported prostheses are integral to patient satisfaction.

Long-term studies assess the stability of soft tissues, including gingival contours and lip support, to ensure that the aesthetic benefits achieved immediately after surgery are maintained over time. Complications are possible, but precise technical procedures, postoperative monitoring, and long-term follow-up of patients with timing re-calls reduce risks related to ZI procedures.

REFERENCES

1. Sharma A, Rahul GR. Zygomatic implants/fixture: a systematic review. *J Oral Implantol*. 2013;39(2):215-24. doi: 10.1563/AAID-JOI-D-11-00055.
2. Wang F, Monje A, Lin GH, Wu Y, Monje F, Wang HL, Davó R. Reliability of four zygomatic implant-supported prostheses for the rehabilitation of the atrophic maxilla: a systematic review. *Int J Oral Maxillofac Implants*. 2015;30(2):293-8. doi: 10.11607/jomi.3691.
3. Aboul-Hosn Centenero S, Lázaro A, Giralt-Hernando M, Hernández-Alfaro F. Zygoma Quad Compared With 2 Zygomatic Implants: A Systematic Review and Meta-analysis. *Implant Dent*. 2018;27(2):246-253. doi: 10.1097/ID.0000000000000726.

4. Gracher AHP, de Moura MB, da Silva Peres P, Thomé G, Padovan LEM, Trojan LC. Full arch rehabilitation in patients with atrophic upper jaws with zygomatic implants: a systematic review. *Int J Implant Dent.* 2021;7(1):17. doi: 10.1186/s40729-021-00297-z.
5. Solà Pérez A, Pastorino D, Aparicio C, Pegueroles Neyra M, Khan RS, Wright S, Ucer C. Success Rates of Zygomatic Implants for the Rehabilitation of Severely Atrophic Maxilla: A Systematic Review. *Dent J (Basel).* 2022;10(8):151. doi: 10.3390/dj10080151.
6. Varghese KG, Gandhi N, Kurian N, Daniel AY, Dhawan K, Joseph M, Varghese MG. Rehabilitation of the severely resorbed maxilla by using quad zygomatic implant-supported prostheses: a systematic review and meta-analysis. *J Prosthet Dent.* 2023;130(4):543-552.
7. Fan S, Sáenz-Ravello G, Diaz L, Wu Y, Davó R, Wang F, Magic M, Al-Nawas B, Kämmerer PW. The Accuracy of Zygomatic Implant Placement Assisted by Dynamic Computer-Aided Surgery: A Systematic Review and Meta-Analysis. *J Clin Med.* 2023;12(16):5418.
8. Ramezanzade S, Keyhan SO, Tuminelli FJ, Fallahi HR, Yousefi P, Lopez-Lopez J. Dynamic-Assisted Navigational System in Zygomatic Implant Surgery: A Qualitative and Quantitative Systematic Review of Current Clinical and Cadaver Studies. *J Oral Maxillofac Surg.* 2021;79(4):799-812. doi: 10.1016/j.joms.2020.10.009.
9. Polido WD, Machado-Fernandez A, Lin WS, Aghaloo T. Indications for zygomatic implants: a systematic review. *Int J Implant Dent.* 2023;9(1):17.
10. Tuminelli FJ, Walter LR, Neugarten J, Bedrossian E. Immediate loading of zygomatic implants: A systematic review of implant survival, prosthesis survival and potential complications. *Eur J Oral Implantol.* 2017;10 Suppl 1:79-87.
11. Lorusso F, Conte R, Inchingolo F, Festa F, Scarano A. Survival Rate of Zygomatic Implants for Fixed Oral Maxillary Rehabilitations: A Systematic Review and Meta-Analysis Comparing Outcomes between Zygomatic and Regular Implants. *Dent J (Basel).* 2021;9(4):38.
12. Sáez-Alcaide LM, Cortés-Bretón-Brinkmann J, Sánchez-Labrador L, Pérez-González F, Forteza-López A, Molinero-Mourelle P, López-Quiles J. Patient-reported outcomes in patients with severe maxillary bone atrophy restored with zygomatic implant-supported complete dental prostheses: a systematic review. *Acta Odontol Scand.* 2022;80(5):363-373.
13. Brennand Roper M, Vissink A, Dudding T, Pollard A, Gareb B, Malevez C, Balshi T, Brecht L, Kumar V, Wu Y, Jung R. Long-term treatment outcomes with zygomatic implants: a systematic review and meta-analysis. *Int J Implant Dent.* 2023;9(1):21. doi: 10.1186/s40729-023-00479-x.
14. Chrcanovic BR, Abreu MH. Survival and complications of zygomatic implants: a systematic review. *Oral Maxillofac Surg.* 2013;17(2):81-93. doi: 10.1007/s10006-012-0331-z.
15. Chrcanovic BR, Albrektsson T, Wennerberg A. Survival and Complications of Zygomatic Implants: An Updated Systematic Review. *J Oral Maxillofac Surg.* 2016;74(10):1949-64.
16. Molinero-Mourelle P, Baca-Gonzalez L, Gao B, Saez-Alcaide LM, Helm A, Lopez-Quiles J. Surgical complications in zygomatic implants: A systematic review. *Med Oral Patol Oral Cir Bucal.* 2016;21(6):e751-e757. doi: 10.4317/medoral.21357.
17. Lan K, Wang F, Huang W, Davó R, Wu Y. Quad Zygomatic Implants: A Systematic Review and Meta-analysis on Survival and Complications. *Int J Oral Maxillofac Implants.* 2021;36(1):21-29.
18. Tavelli C, Tedesco A. Survival and complication rate of zygomatic implants: a systematic review. *J Oral Implantol.* doi:10.1563/aaid-joi-D-22-00008. Online ahead of print.
19. Gabriele G, Chisci G, Cascino F, Ricci NM, Marruganti C, Ferrari M. Technique-Related Survival Rate and Complications of Zygomatic Implant Placement: A Systematic Review and Meta-Analysis. *Int J Oral Maxillofac Implants.* 2023;38(5):855-875. doi: 10.11607/jomi.10330.
20. Kämmerer PW, Fan S, Aparicio C, Bedrossian E, Davó R, Morton D, Raghoobar GM, Zarrine S, Al-Nawas B. Evaluation of surgical techniques in survival rate and complications of zygomatic implants for the rehabilitation of the atrophic edentulous maxilla: a systematic review. *Int J Implant Dent.* 2023;9(1):11. doi: 10.1186/s40729-023-00478-y.
21. Moraschini V, de Queiroz TR, Sartoretto SC, de Almeida DCF, Calasans-Maia MD, Louro RS. Survival and complications of zygomatic implants compared to conventional implants reported in longitudinal studies with a follow-up period of at least 5 years: A systematic review and meta-analysis. *Clin Implant Dent Relat Res.* 2023;25(1):177-189. doi: 10.1111/cid.13153.