

Case series

IMPLANT TIP INSERTION IN THE MEDIAL WALL OF THE MAXILLARY SINUS TO OBTAIN FIXTURE PRIMARY STABILITY DURING SINUS LIFT PROCEDURE BY LATERAL WINDOW TECHNIQUE

L. Tomaselli

Private Practice, Bologna, Italy

Correspondence to:

Luigi Tomaselli, DDS, MS

Private practice

Via Azzurra, 26

40138 Bologna, Italy

Email: gigitomasellimail.com

ABSTRACT

Maxillary sinus lift (MSL), a cornerstone in implant dentistry, requires a deep understanding of various surgical techniques to address bone deficiencies in the posterior maxilla. MSL by lateral approach is the elective procedure in case of extreme bone atrophies of the sinus floor. When the residual bone thickness is less than 3 mm, MSL by lateral approach is possible but not immediate implant insertion due to lack of fixture primary stability. In these cases, primary fixture stability can be obtained by bi-cortical stabilization. After Scheniderian membrane elevation, the implant is inserted through the alveolar crest and fixed to the maxillary sinus mesial (nasal) wall, leading to an implant's primary stability. Here, a case series is reported.

KEYWORDS: *maxilla, jaw, sinus, lift, implant, fixture*

INTRODUCTION

Insufficient bone volume is a common problem encountered in rehabilitating the edentulous posterior maxillae with implant-supported prostheses. Bone volume is limited by the presence of the maxillary sinus, together with loss of alveolar bone height. The maxillary sinus lift (MSL), a transformative surgical procedure in implant dentistry, has evolved significantly over the years, reshaping the landscape of treatment options for patients with insufficient bone in the posterior maxilla (1-17). The early days of implantology saw limited solutions for posterior maxillary edentulism due to anatomical challenges posed by the maxillary sinus. Pursuing innovative techniques to overcome these challenges has led to the development of the MSL as a cornerstone in addressing bone deficiencies. In this light, advancements in technology and materials have significantly influenced the landscape of maxillary sinus lift procedures. Two are the main techniques to approach the maxillary sinus: the lateral window technique involves creating a window in the lateral wall of the maxillary sinus, providing direct access for graft placement, while the crestal approach accesses the sinus through the alveolar crest, eliminating the need for a lateral window.

Received: 31 July 2023

Accepted: 30 August 2023

Copyright © by LAB srl 2023 ISSN 2975-1276

This publication and/or article is for individual use only and may not be further reproduced without written permission from the copyright holder. Unauthorized reproduction may result in financial and other penalties. Disclosure: All authors report no conflicts of interest relevant to this article.

Several systematic reviews have focused on MSL techniques. Esposito et al. (1) reviewed the literature to test whether and when augmentation of the maxillary sinus is necessary and which are the most effective augmentation techniques for rehabilitating patients with implant-supported prostheses. They found that short implants (5 mm long) can be successfully loaded in maxillary bone with a residual height of 4 to 6 mm. Elevating the sinus lining in the presence of 1 to 5 mm of residual bone height without adding a bone graft is sufficient to regenerate new bone to allow rehabilitation with implant-supported prostheses. Bone substitutes are successfully used as replacements for autogenous bone. If the residual alveolar bone height is 3 to 6 mm, a crestal approach to lifting the sinus lining and placing 8 mm implants leads to fewer complications than a lateral window approach and placing implants at least 10 mm long. Romero-Millán et al. (2) compared implant survival, marginal bone loss, and complications in dental implants placed in the posterior maxilla in native bone or after grafting using the open sinus lift technique. The authors concluded that implant placement after sinus lift affords results in terms of implant survival, marginal bone loss, and peri-implant clinical parameters like those obtained with conventional implant placement in native bone. Parra et al. (3) studied the survival rate of dental implants installed in the posterior region of the maxilla after a graft-less maxillary sinus lift via the lateral window approach to identify the factors involved in the results. Juzikis et al. (4) reviewed all the possible uses for maxillary sinus lateral wall bony windows in an open maxillary sinus lift procedure to evaluate the influence of each method on the rate of sinus membrane perforations. Authors found 4 distinct uses for bony windows: bony window is elevated into the sinus cavity under the membrane, removed and discarded, repositioned to its original position after the surgery, and used as a graft material for a sinus lift. They discovered a statistically significant difference in sinus membrane perforations between different uses of the lateral bony window of an open sinus lift procedure. Schiavon et al. (5) performed a meta-analysis that provided moderate evidence that the repositioned bone lid favored the formation of new bone to a greater extent as compared to resorbable membranes.

In the case of extreme atrophies of the maxilla, residual bone can be thinner than 3 mm. MSL by lateral approach is possible but not an immediate implant insertion due to lack of fixture primary stability. In these cases, primary fixture stability can be obtained by bi-cortical stabilization. After Schneiderian membrane elevation, the implant is inserted through the alveolar crest and fixed to the maxillary sinus mesial (nasal) wall, leading to implant primary stability. Here, a case series is reported.

CASE REPORT

Case 1

The patient presented to our clinic with complaints about her smile in 2020. She was 38 years old and was a nonsmoker. At clinical and radiological evaluation, she has a far-advanced periodontal disease (Fig. 1). A rehabilitation of the upper left and lower right implant rehabilitation was planned.

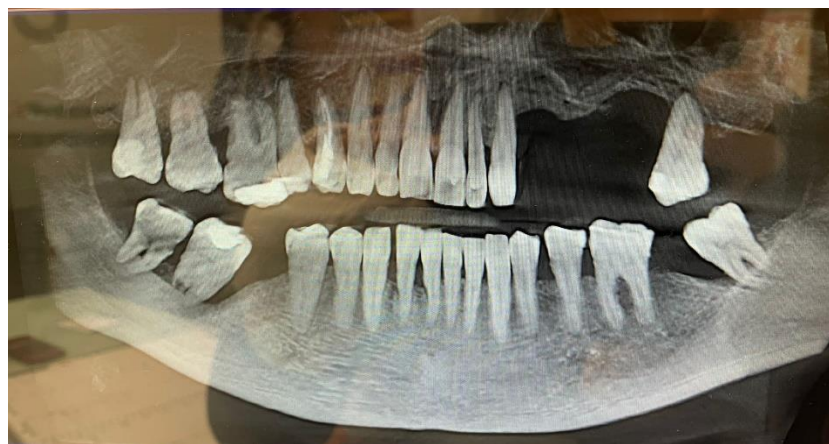

Fig. 1. Pre-operative X-ray.

Surgically, after locoregional anesthesia and infraorbital nerve block a full-thickness flap is elevated. The lateral wall of the maxilla was exposed and an anrostomy was performed to find the Schneiderian membrane. Sinus lift was then performed with a full exposition of the medial wall of the sinus which was the target of the drill during implant osteotomy and insertion.

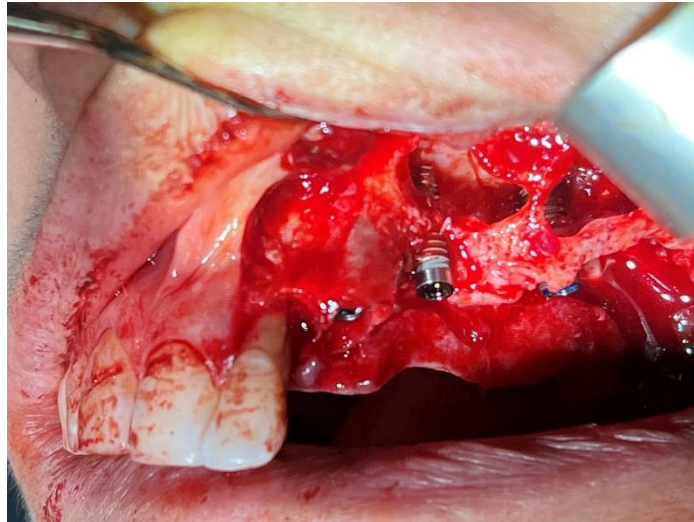


Fig. 2. Bone defect and inserted implant.

Implants were positioned and secured to the medial wall of the sinus, which allowed to reach a considerable torque of primary stability even in such a poor residual bone crest (Fig. 2). Autogenous bone chips were harvested from the tuberosity and the zygomatic process. Sub-sinus space was filled with heterologous bone, as well as peri-implant space. A mix of 50/50 autogenous/heterologous bone was then used in the superficial part of the grafting site. The titanium mesh was secured firstly palatal with 4 screws 4 mm long and then buccally with 3 screws. Mesh compacted bone chips (Fig. 3). Flap release was performed cutting periosteum, and a suture was performed with horizontal mattress and single stitches (Fig. 4).

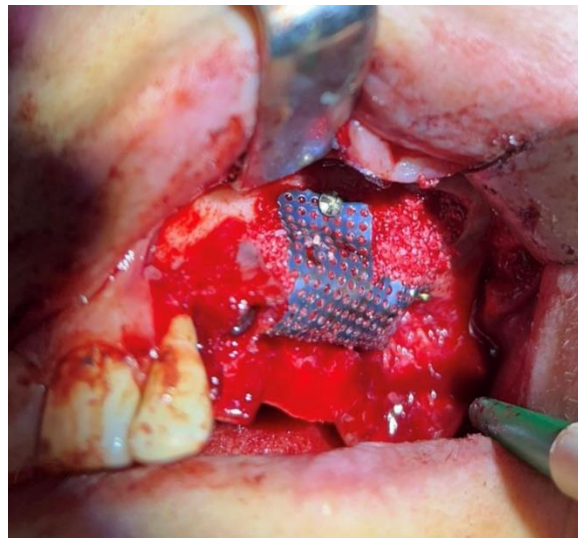


Fig. 3. Ti-mesh fixed.

Radiographic control performed 2 weeks after surgery demonstrated the sinus lifting and the bi-cortical placement of the implant (Fig. 5, 6) with anchorage in the medial wall without perforation of the nasal membrane. After 6 months, the titanium mesh was removed, and the healing abutment was placed. Standard procedures of prosthetic rehabilitation were then done, as well as a final panorex. After 24 months, the patient had no complications.

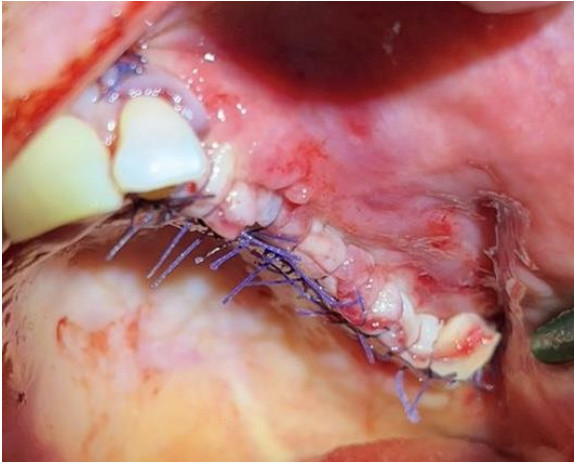


Fig. 4. Suture

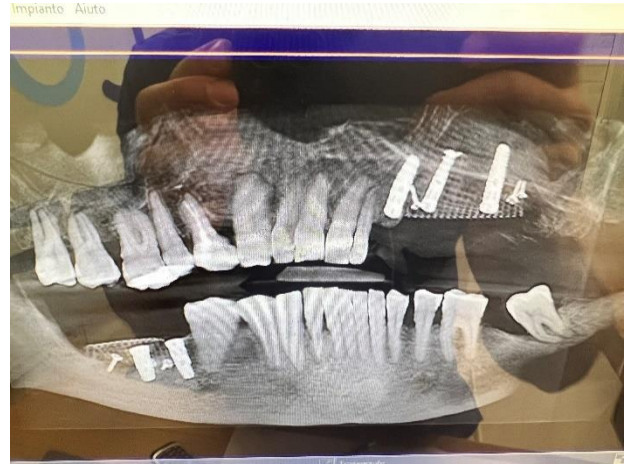

Fig. 5. Post-operative X-ray.

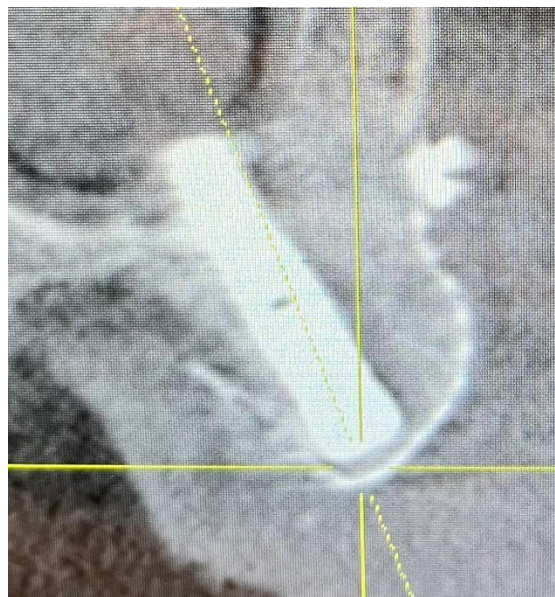


Fig. 6. CBCT check bicortical at 6 months

Case 2

The patient presented to our clinic complaining for her chewing in 2019. She was 42 years old and was a light smoker. At the clinical and radiological evaluation, she had a far-advanced periodontal disease (Fig. 7). A bi-maxillary Toronto rehabilitation was planned.

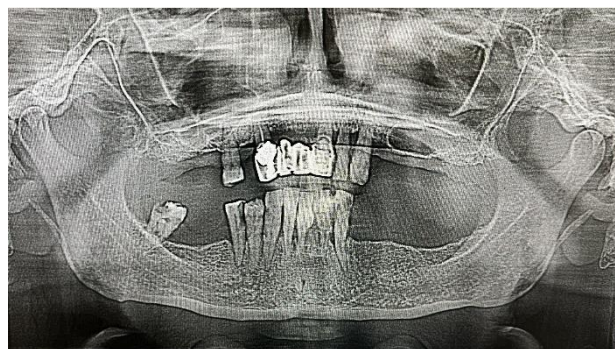


Fig. 7. Pre-operative X-ray.

Surgically, after loco-regional anesthesia a full thickness full arch flap was performed. Maxilla was skeletonized and bilateral antrostomy was carried out with mobilization of the Schneiderian membrane. The medial wall of the maxillary sinus was exposed and targeted with implant osteotomy (Fig. 8).

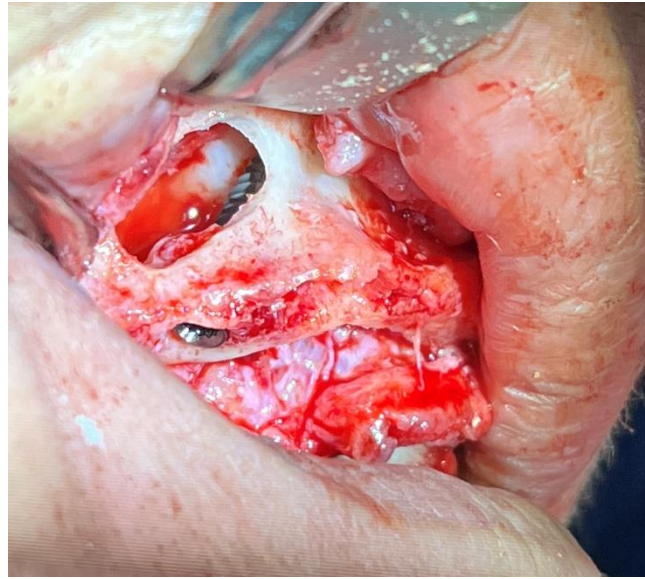

Fig. 8. *Right medial wall anchorage.*

Trans sinusal implants were tilted to reach a major anteroposterior spread in a transversal contracted maxilla. Poor residual bone crest would not allow sufficient primary stability to perform immediate loading but with the medial wall anchorage 60 N of torque was reached. Two additional implants were screwed in the pre-maxilla and multi-unit abutment screwed (Fig. 9).

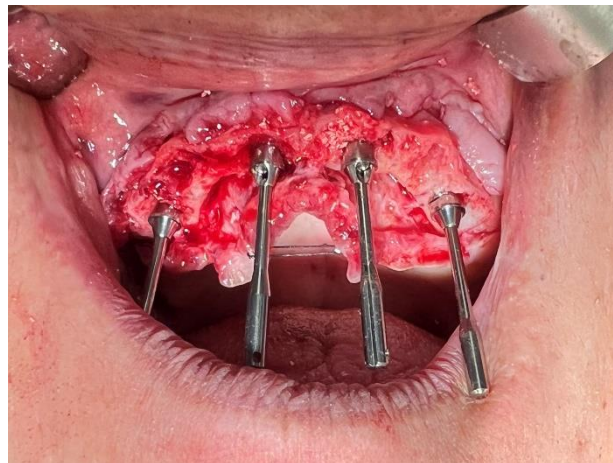


Fig. 9. *Endo-oral photo showing implant orientation.*

Sub-sinus space was fulfilled with heterologous graft and antrostomy covered with a resorbable membrane. An accurate suture was done, managing the soft keratinized tissue around the healing abutment. Immediate temporary prosthesis was secured to the patient. The subsequent month the patient was operated on the mandible for placing an all-on-4 restoration. After 4 months both restorations were removed, and a final prosthetic rehabilitation was delivered as well as final X-ray control was performed. After 36 months, the patient had no complications (Fig. 10-13).

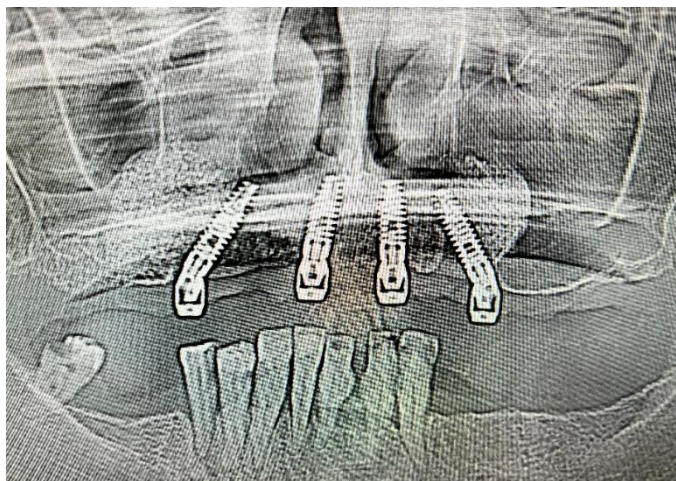


Fig. 10. *Post-operative X-ray.*

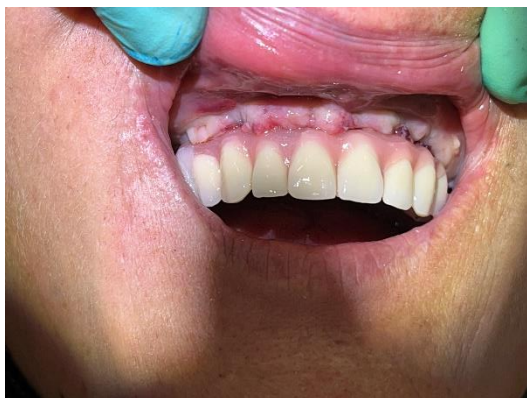

Fig. 11. *Immediate temporary rehabilitation*

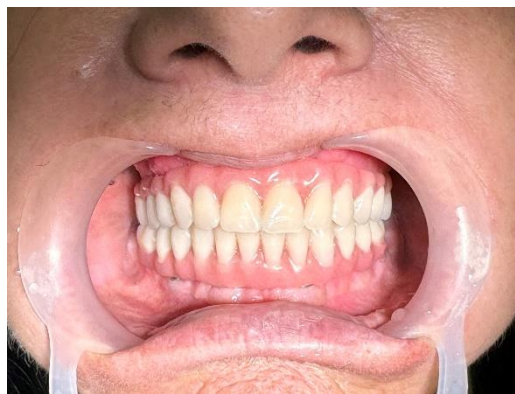

Fig. 12. *Smile.*

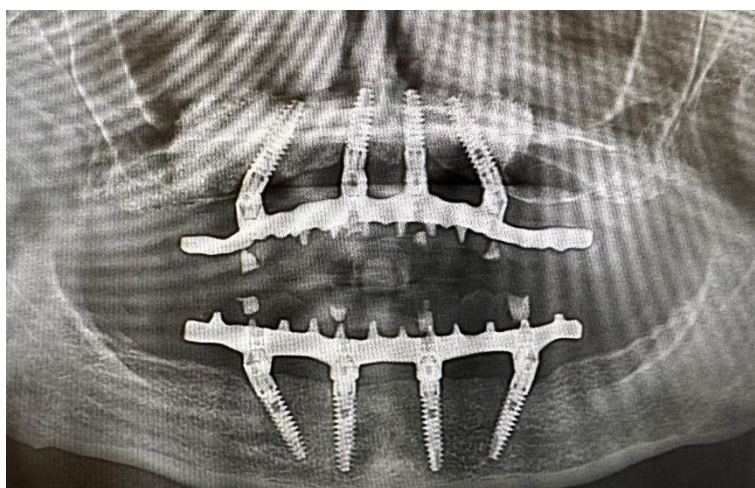


Fig. 13. *Final X-ray.*

DISCUSSION

The maxillary sinus lateral window technique, a pivotal procedure in implant dentistry, addresses bone deficiencies in the posterior maxilla, enabling successful implant placement (1-5). Additional solutions are also available in case of reduced bone high in maxillary floor (6-10). Potdukhe et al. (6) detected no difference in primary implant stability and increase in bone height in indirect sinus lift using osseodensification and the osteotome technique, both performed through alveolar crest. Asawa et al. (7) focused on the use of an alternative procedure in which two posterior implants are placed at an angle and two anterior implants are placed axially thereby eliminating the need for sinus lift or bone augmentation procedures.

Also, short implants are a reliable alternative to MSL (8-11). Cruz et al. (8) compared the survival rate of dental implants and rates of complications (biological and prosthetic) between short implants and long implants placed after maxillary sinus augmentation. No significant difference was observed in the survival rate or in the amount of marginal bone loss. However, higher rates of biological complications for long implants associated with maxillary sinus augmentation were observed, whereas a higher prosthetic complication rate for short implants was noted. Short implant placement is an effective alternative because of fewer biological complications and similar survival and marginal bone loss than long implant placement with maxillary sinus augmentation. The risk of mechanical complications associated with the prostheses fitted on short implants should be considered. Mokcheh et al. (9) performed a meta-analysis to investigate what would be the best choice in terms of survival rate and complications: the use of short implants or performing sinus lift and the establishment of standard implants. The results did not show a statistically significant difference in the survival rate of the two procedures over the short, medium and long term. However, the study of complications shows that in the short and medium term, the results are in favor of short implants. Consequently, compared to standard implants associated with sinus lift, short implants have the advantage of being a solution with a high survival rate, it is less expensive, requiring less surgical time, presenting fewer complications compared to advanced surgery of sinus lift and thus obtaining more patient satisfaction. Carosi et al. (10) evaluated the survival rate of short dental implants placed in the posterior area of the maxilla. Based on the evidence of the included studies, short implants (≤ 6 mm) reported high survival rates over short to medium follow-up in the posterior maxilla with respect to standard-length implants plus augmentation procedures.

Another critical variable in MSL is graft material (11-16). Rickert et al. (11) performed a systematic review comparing trials where sinus floor elevations with autogenous bone (controls) were compared with autogenous bone combined with growth factors or bone substitutes, or solely with bone substitutes (test groups) were identified. They reported that bone substitutes combined with autogenous bone provide a reliable alternative for autogenous bone as sole grafting material to reconstruct maxillary sinus bony deficiencies, for supporting dental implants. Adding growth factors (platelet-rich plasma) to grafting material and the sole use of β -tricalcium-phosphate did not promote bone formation. Pérez-Martínez et al. (12) focused on indirect sinus lift without the use of bone graft material. They found that placement of implants with sinus lift without bone graft material is a valid surgical technique to gain residual crestal height and placed implants in an atrophic posterior maxillary with a crestal height from 5 to 9 mm. Silva et al. (13) investigated a comparative analysis of the use or not of graft material in maxillary sinus lift surgery. The implant survival rate was 96% for surgeries performed without graft material and 99% for those in which biomaterial was used, within a follow-up period of 48 to 60 months. Correia et al. (14) showed that only a few studies have demonstrated the potential of regenerative medicine in sinus lift. Lie et al. (15) evaluated the existing clinical evidence on the efficacy of graft-less maxillary sinus membrane elevation for implantation in the atrophic posterior maxilla. Results showed a high overall implant survival rate in both the graft-less and bone-grafted sinus lift groups. The graft-less sinus lift group showed a significantly lower vertical bone height gain, and a significantly lower bone density. Otero et al. (16) analyzed sinus lifting procedures to compare the efficiency of this treatment associated with platelet-rich fibrin (PRF). They found that a higher risk for implant failure after a sinus elevation might be seen in patients with residual bone ≤ 4 mm and PRF application was effective, suggesting reducing the time needed for new bone formation.

In case of extreme atrophies of the maxilla, residual bone can be thinner than 3 mm. In these cases, MSL by lateral approach is the only option instead of crestal approach (6) or angulated (7) and short (8-16) implants. When the maxillary sinus floor is thinner than 3 mm MSL by lateral approach is possible but not immediate implant insertion due to lack of fixture primary stability. In these cases, primary fixture stability can be obtained by bi-cortical stabilization. After Schneiderian membrane elevation, an implant is inserted through the alveolar crest and fixed to the maxillary sinus mesial (nasal) wall leading to the implant's primary stability. The reported case series shows the feasibility of this surgical technique.

Finally, particular attention should be paid to avoiding sinus membrane perforation, although suturing and doubling the Schneiderian membrane with an allograft membrane can preserve it from additional complications. In a

recent meta-analysis, Al-Moraissi et al. (17) investigated whether intraoperative Schneiderian membrane perforation in the maxillary sinus lift causes an increase in the risk of implant failure especially in terms of implant loss following the maxillary sinus lift. They found that an intraoperative Schneiderian membrane perforation could increase the risk of implant failure after sinus lift surgery.

CONCLUSIONS

The clinical significance of maxillary sinus lifts extends beyond the technical aspects of the procedure. Implant dentistry has witnessed a paradigm shift, enabling clinicians to offer viable solutions for patients with posterior maxillary atrophy. The maxillary sinus lift, as a preparatory step for dental implant placement, holds the promise of restoring not only the patient's oral function but also their aesthetic and psychological well-being. MSL by lateral approach is the elective procedure in case of extreme bone atrophies of the sinus floor. When the residual bone is less than 3 mm thin, MSL by lateral approach is possible but not immediate implant insertion due to lack of fixture primary stability. In these cases, primary fixture stability can be obtained by bi-cortical stabilization. After Schneiderian membrane elevation, an implant is inserted through the alveolar crest and fixed to the maxillary sinus mesial (nasal) wall leading to an implant primary stability. Here a case series is reported showing the feasibility of the procedure. Additional reports with longer follow-ups have to be reported to firmly establish the advantages and disadvantages of this surgical procedure.

REFERENCES

- Esposito M, Maria Gabriella Grusovin, Rees J, et al. Effectiveness of sinus lift procedures for dental implant rehabilitation: a Cochrane systematic review. *European Journal of Oral Implantology*. 2010;3(1):7-26.
- Romero-Millán J, Aizcorbe-Vicente J, Peñarrocha-Diago M, Galindo-Moreno P, Canullo L, Peñarrocha-Oltra D. Implants in the Posterior Maxilla: Open Sinus Lift Versus Conventional Implant Placement. A Systematic Review. *The International Journal of Oral & Maxillofacial Implants*. 2019;34(4):e65-e76. doi:https://doi.org/10.11607/jomi.7274
- Parra M, Atala-Acevedo C, Fariña R, Haidar ZS, Zaror C, Olate S. Graftless Maxillary Sinus Lift Using Lateral Window Approach. *Implant Dentistry*. 2018;27(1):111-118. doi:https://doi.org/10.1097/id.0000000000000695
- Elvinas Juzikis, Algimantas Gaubys, Henrikas Rusilas. Uses of maxillary sinus lateral wall bony window in an open window sinus lift procedure: literature review. *PubMed*. 2018;20(1):14-21.
- Lucia S, Alessandro P, Giulia B, et al. The bone lid technique in lateral sinus lift: a systematic review and meta-analysis. *International Journal of Implant Dentistry*. 2022;8(1). doi:https://doi.org/10.1186/s40729-022-00433-3
- Potdukhe SS, Iyer JM, Nadgere JB. Evaluation of implant stability and increase in bone height in indirect sinus lift done with the osseodensification and osteotome technique: A systematic review and meta-analysis. *The Journal of Prosthetic Dentistry*. doi:https://doi.org/10.1016/j.prosdent.2023.04.021
- Asawa N. Angulated Implants: An Alternative to Bone Augmentation and Sinus Lift Procedure: Systematic Review. *Journal of clinical and diagnostic research*. 2015;9(3). doi:https://doi.org/10.7860/jcdr/2015/11368.5655
- Cruz RS, Lemos CA De A, Batista VE de S, et al. Short implants versus longer implants with maxillary sinus lift. A systematic review and meta-analysis. *Brazilian Oral Research*. 2018;32(0). doi:https://doi.org/10.1590/1807-3107bor-2018.vol32.0086
- Mokcheh A, Jegham H, Turki S. Short implants as an alternative to sinus lift for the rehabilitation of posterior maxillary atrophies: Systematic review and meta-analysis. *Journal of Stomatology, Oral and Maxillofacial Surgery*. 2019;120(1):28-37. doi:https://doi.org/10.1016/j.jormas.2018.11.006
- Carosi P, Lorenzi C, Lio F, Laureti M, Ferrigno N, Arcuri C. Short implants (≤ 6 mm) as an alternative treatment option to maxillary sinus lift. *International Journal of Oral and Maxillofacial Surgery*. 2021;50(11):1502-1510. doi:https://doi.org/10.1016/j.ijom.2021.02.014
- Rickert D, Slater JJRHuddleston, Meijer HJA, Vissink A, Raghoobar GM. Maxillary sinus lift with solely autogenous bone compared to a combination of autogenous bone and growth factors or (solely) bone substitutes. A systematic review. *International Journal of Oral and Maxillofacial Surgery*. 2012;41(2):160-167. doi:https://doi.org/10.1016/j.ijom.2011.10.001
- Perez-Martinez S, Martorell-Calatayud L, Penarrocha-Oltra D, Garcia-Mira B, Penarrocha-Diago M. Indirect sinus lift without bone graft material: Systematic review and meta-analysis. *Journal of Clinical and Experimental Dentistry*. 2015;7(2):e316-e319. doi:https://doi.org/10.4317/jced.51716
- Silva L deF, de Lima VN, Faverani LP, de Mendonça MR, Okamoto R, Pellizzer EP. Maxillary sinus lift surgery-with or without graft material? A systematic review. *International Journal of Oral and Maxillofacial Surgery*. 2016;45(12):1570-1576. doi:https://doi.org/10.1016/j.ijom.2016.09.023
- Correia F, Pozza DH, Gouveia S, Felino A, Faria e Almeida R. The applications of regenerative medicine in sinus lift procedures: A systematic review. *Clinical Implant Dentistry and Related Research*. 2017;20(2):229-242. doi:https://doi.org/10.1111/cid.12561
- Lie SAN, Claessen RMMA, Leung CAW, Merten HA., Kessler PAWH. Non-grafted versus grafted sinus lift procedures for implantation in the atrophic maxilla: a systematic review and meta-analysis of randomized controlled trials. *International*

- Journal of Oral and Maxillofacial Surgery*. 2022;51(1):122-132. doi:<https://doi.org/10.1016/j.ijom.2021.03.016>
16. Otero AIP, Fernandes JCH, Borges T, Nassani L, Castilho R de M, Fernandes GV de O. Sinus Lift Associated with Leucocyte-Platelet-Rich Fibrin (Second Generation) for Bone Gain: A Systematic Review. *Journal of Clinical Medicine*. 2022;11(7):1888. doi:<https://doi.org/10.3390/jcm11071888>
 17. Al-Moraisi E, Elsharkawy A, Abotaleb B, Alkebsi K, Al-Motwakel H. Does intraoperative perforation of Schneiderian membrane during sinus lift surgery causes an increased the risk of implants failure?: A systematic review and meta regression analysis. *Clinical Implant Dentistry and Related Research*. 2018;20(5):882-889. doi:<https://doi.org/10.1111/cid.12660>