

---

## Editorial

In the last decade, a significant increase in scientific publications has been detected in literature, with over 479,000 articles on the Scopus index with “dentistry” as the subject area, representing an increase of about 55% compared to the previous period from 2012 to 2002. The scientific production inflation is reflected in a total of 157 scientific journals classified with the “dentistry, oral surgery & medicine” category on Journal Citation Report (Clarivate) with a median impact factor of 2.6 on Science Citation Index Expanded (SCIE database) and 0.8 on Emerging Sources Citation Index (ESCI).

The *Annals of Stomatology* is an innovative international peer-reviewed journal focused on publishing significant research across various domains of dentistry, maxillofacial diseases, and translational and regenerative medicine. The critical importance of these fields has been increasingly recognized by global health authorities, who have underscored the role of oral health in overall healthcare systems and societal well-being. By early 2021, it was estimated that billions of individuals worldwide were affected by oral diseases, including tooth loss, illustrating the global burden of these conditions.

In response to this growing concern, several significant strategic initiatives were undertaken. A comprehensive action plan was developed to address oral health globally, prioritizing key areas such as governance, oral health promotion and prevention, workforce training and development, access to oral healthcare services, the enhancement of information systems, and the expansion of research. These initiatives highlighted the essential role of oral health in not just maintaining individual aesthetics and functionality but also in fostering social connections and self-esteem throughout the human lifespan. Furthermore, these strategic decisions reflected a commitment to integrating oral health more deeply into the broader healthcare and welfare systems, recognizing its importance as a fundamental component of overall health. The recent insights in regenerative dentistry and biomedicine are emerging promising advances in implant device surfaces, bioactive materials, and tissue engineering that can improve biological responses and oral tissue healing.

Novel targets have been determined by identifying new-generation materials promoting bone tissue response and rehabilitation predictability. In this way, dental implant rehabilitation represents a highly debated topic in line with the bibliometric spread of the dentistry area concerning innovative

medical devices, clinical protocols, predictability, long-term outcomes, and complications. The importance of this field is immediately clarified by the dimension of the worldwide dental implant market valued at 4.15 billion USD in 2020.

On the other hand, the journal's purpose will be to produce a significant translational impact on the scientific knowledge in dental clinical practice. The interdisciplinarity will be a consistent component of the editorial line, especially with the dental innovations and emerging issues in this field with high evidence. The different topic areas will be addressed considering innovative, original research, including full papers, clinical case reports, systematic reviews, randomised clinical trials, cohort and pilot studies, and editorials through a high-quality peer review by a qualified, respectable expert.

An Editorial Board will define the journal's scientific line and orientation with a respectable international membership, and the Editor-in-Chief will preliminarily evaluate the manuscript's suitability for publication. The peer review will be conducted through at least two double-blind expert reviewers with full respect to the journal's ethical transparency policy.

The journal's goal will be to maintain a rapid correspondence with authors, reducing any delay of the review processing no more than one month from the submission process in full respect to the quality content expectation of the scientific products. Particular attention will be given to the ethical and methodological aspects of the study proposal, the adherence to the Good Clinical Practice Guidelines and the data availability of the experiments. Also, any conflict of interest will be managed and declared in the publications to maintain the journal policy's high transparency.

The Editorial Board plays a pivotal role in shaping the content and direction of the *Annals of Stomatology*; a journal focused on staying at the forefront of the ever-evolving medical field. Their responsibility includes keeping abreast of current trends and emerging global issues within the healthcare system, all while adhering to the principles of evidence-based medicine and evidence-based dentistry.

Their dedication to these principles and the dynamic nature of medical science instill confidence in the potential for rapid success and widespread recognition of the *Annals of Stomatology*.

We extend our best wishes to the journal and its Editorial Board, hoping for continued achievements and valuable contributions to the field of stomatology.

Deputy Editor  
Federico Gelpi

Comparative Study

## OSTEOBLAST ADHESION ON ACID-ETCHED AND MACHINED SURFACES

S.R. Tari<sup>1†</sup>, F. Tricca<sup>1</sup>, F. Postiglione<sup>1</sup>, C. Bugea<sup>1</sup>, S.A. Gehrke<sup>2,3†</sup> and A. Scarano<sup>1\*</sup>

<sup>1</sup>Department of Innovative Technologies in Medicine and Dentistry, University of Chieti-Pescara, 66100 Chieti, Italy;

<sup>2</sup>Department of Research, Bioface/PgO/UCAM, Montevideo, Uruguay;

<sup>3</sup>Department of Biotechnology. Universidad Católica de Murcia (UCAM), Murcia, Spain

<sup>†</sup>These authors contributed equally to this work as co-first authors

\*Correspondence to:

Antonio Scarano, DDS, MD

Department of Innovative Technology in Medicine and Dentistry,

University of Chieti-Pescara,

Via Dei Vestini 31,

66100 Chieti Italy

e-mail: ascarano@unich.it

### ABSTRACT

Implants with surface chemical or biomechanical qualities that should encourage bone formation have been developed over the last 30 years. Few systematic investigations have been conducted on surface topography despite the widespread recognition that it is a significant factor influencing bone-implant contact. Four white New Zealand mature rabbits were used in the present investigation. Each rabbit received 2 implants, specially made with 2 surfaces on it (one sandblasted and acid etched and one machined) into each tibia. A total of 16 implants were inserted. All animals were killed 21 days after implant placement. Osteoblast in contact with the implant surface was statistically evaluated. The sandblasted and acid-etched surfaces showed a greater osteoblast contact than the machined, which was statistically significant. The sandblasted and acid-etched surface improves osteoblast adhesion on the implant surface.

**KEYWORDS:** *bone contact, machined implants, acid etched, osteoblast, bone healing, dental implants*

### INTRODUCTION

Dental prostheses have been successfully fixed using osseointegrated dental implants (1). Surface modification research aims to raise the percentage of bone-implant contact (BIC). Implants with surface chemical or biomechanical qualities that should encourage bone formation have been developed over the last 30 years. Few systematic investigations have been conducted on surface topography despite the widespread recognition that it is a significant factor influencing bone-implant contact (2). For this reason, a rough, textured, porous surface is incorporated into the design of many dental implants. This is because studies have demonstrated that roughened implant surfaces improve osseointegration. Such designs provide a larger surface area, which increases the possibility of cell attachment.

Tissue ingrowth into the implant is anticipated to stabilize the device mechanically by carefully gliding the rounded, fire-polished end of a glass rod across the tissue culture polystyrene. Fibroblasts avoided these uneven surfaces and gathered on the tissue culture dish's smooth areas. In contrast, macrophages preferred the rough surfaces to the smooth ones, a behavior described as "rugophilia" (3, 4). A comparable pattern of behavior has been reported for implants *in vivo*; it has been reported that macrophages preferred abraded Teflon implants(5). Interesting questions are raised by the

Received: 02 September 2021

Accepted: 06 October 2021

Copyright © by LAB srl 2021 ISSN 2975-1276

This publication and/or article is for individual use only and may not be further reproduced without written permission from the copyright holder. Unauthorized reproduction may result in financial and other penalties. Disclosure: All authors report no conflicts of interest relevant to this article.

roughened surfaces' propensity to draw monocytic series cells. For instance, since it is known that cells coming from the monocyte lineage generate osteoclasts, it is advantageous for implants in contact with bone to have surfaces that attract cells of the monocytic series (6).

Cell function and structure can be directly impacted by the surfaces on which cells can cling. In smooth substrata, cells produced on grooved substrata are more spherical (7, 8). Cell shape influences several cellular features, such as growth (9), secretion of proteinases (10), and gene expression (7). An implant's surface texture may selectively target particular cell populations and modify their activities. Detailed research is still needed to determine how implant surfaces impact the cells they come into touch with. This study used a split implant design to compare the osteoblast in contact with machined and those that were sandblasted acid etched.

## MATERIALS AND METHODS

Threaded machined and acid-etched pure titanium screw-shaped implants have been used in this study. The fixtures were placed into the tibia of 4 white New Zealand mature male rabbits according to a previously described technique (11). Each rabbit received 2 implants 4x8 mm, specially made with 2 surfaces on it (one sandblasted and acid etched and one machined) (Isomed System, Due Carrare, Padova, Italy) for each tibia. A total of 16 implants were inserted. The animals were anesthetized with intramuscular injection of fluanisone (0.7 mg/kg) and diazepam (1.5 mg/kg), and local anesthesia was given using 1 ml of 2% lidocaine/adrenalin solution. A skin incision with a periosteal flap was used to expose the tibial plate.

The preparation of the surgical sites was done with a series of burs under copious saline irrigation. Implant placement was performed according to a previously described protocol (11). The periosteum and fascia were sutured with absorbable sutures, whereas the skin was sutured with non-resorbable sutures. No postoperative complications or deaths occurred. The animals were killed 21 days after implant placement. An overdose of anesthesia was given, an incision was made on the tibia, and a block section was taken. All 16 implants were retrieved. The specimens were immediately stored in 10% buffered formalin and processed to obtain thin ground sections with a cutting-grinding machine. The specimens were dehydrated in an ascending series of alcohol rinses and embedded in a glycolmethacrylate resin. After polymerization, the specimens were sectioned longitudinally along the central axis of the implant with a high-precision diamond disc at about 150 microns and ground down to about 70 microns. One slide was obtained for each implant and stained with basic fuchsin and toluidine blue. Osteoblast in contact with the implant was done under a light microscope using a dedicated computer.

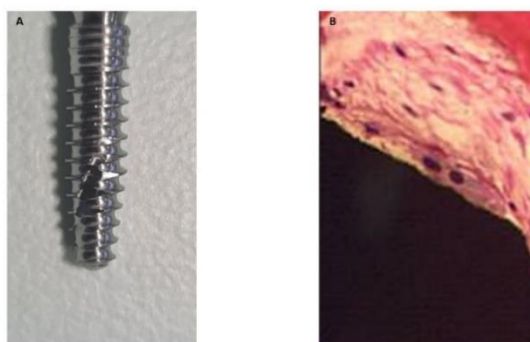
### *Data analysis*

The differences in the number of osteoblasts in contact between test (sandblasted and acid-etched) and control (machined) implants were evaluated. The RMANOVA analyzed the differences between the surface and the treatment groups, and the significance was assessed using the multi-comparison Tukey Test at  $p \leq 0.05$ . Three mm areas were examined for each sample.

## RESULTS

### *Machined surface*

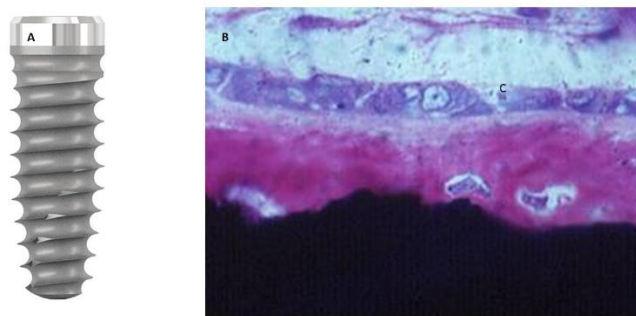
The number of osteoblasts near the implant surface was  $15 \pm 3$  (Fig. 1).



**Fig. 1. A):** Implant with machined surface; **B):** Four osteoblasts are recorded near the implant surface.

### *Sandblasted and acid-etched surface*

The number of osteoblasts in contact with the implant surface was  $22 \pm 4$  (Fig. 2).



**Fig. 2.** A): Implant with sandblasted and acid-etched surface; B): Nine osteoblasts are observed in contact with the implant surface.

### *Statistical evaluation*

The difference in mean values among the treatment groups was evaluated using RMANOVA. The test result shows a statistically significant difference ( $p = 0.001$ ).

## **DISCUSSION**

This research shows greater osteoblast adhesion on the sandblasted and acid-etched implant surface than on the machined surface. For patients who are totally or partially edentulous, using osseointegrated dental implants implanted in the jaws with direct bone-implant contact has evolved over the past 30 years into a dependable and popular treatment option (1). Several factors that affect the apposition of bone on implant surfaces have been studied in recent years to improve the bone anchoring of dental implants. The surface is the one that significantly influences the implant's integration (12). A favorable association has been demonstrated between the roughness values of five evaluated titanium surfaces and the percentage of bone-implant contact (13).

The best outcomes were obtained with 52% and 58% bone contact on the sandblasted and acid-etched surfaces. In tissue culture, the surfaces exhibit more alkaline phosphatase activity in osteoblast-like cells than smooth surfaces (14, 15). These data imply that the bone cells in touch with an etched surface may be more differentiated since alkaline phosphatase activity is a marker of bone cell maturation.

The results of Kaluđerović et al. (16) indicating that titanium disks with a microporous TPS surface demonstrated significantly faster bone-implant contact compared to those with smooth titanium surfaces could also be explained by these findings, which demonstrated a significant advantage for the etched surface during the early healing period. Torque removal forces have been employed biomechanically to disrupt the anchoring of osseointegration. Klokkevold et al. (17) examined rabbit femur resistance to removal forces. They employed machined and acid-etched surfaces. Following a two-month healing period, it was discovered that four times more force was required to remove the acid-etched implants than the machined implants. Based on the reverse torque rotation, they concluded that chemical etching of the titanium implant surface improves osseointegration.

Another author examined the removal torque values of titanium implants in the small pigs' maxillae. They contrasted implants that were machined, acid-etched, sandblasted, and sandblasted and acid-etched (SLA). Removal torque values for SLA implants were 75% higher than those of acid-etched implants following a 12-week healing period. Cordioli et al. (18) also performed a histomorphometric examination in the rabbit's tibia and determined the removal torque value. Four surface types were compared: machined, sprayed, acid-etched, and grit-blasted.

Histomorphometric analysis and removal torque values showed a considerable increase for the acid-etched implants after a 5-week healing period compared to the machined, blasted, and sprayed surfaces (4). The findings showed that compared to machined surfaces, a microrough titanium surface produced by acid etching techniques produced a larger percentage of bone-implant contact. In eight weeks, the bunnies were put to death. Around the implants, cortical bone development was more developed than cancellous bone. After six weeks, three months, and six months, the removal torque for screw-shaped pure titanium implants placed in the femoral portion of the knee joint and the rabbit tibia (19) was compared to the tissue response to these implants, as measured by light microscopic morphometry on ground sections.

Whereas cortical bone developed around the tibial implants, most of the bone around the femoral intra-articular implants was cancellous. Over time, the torque required to remove the intra-articular implants rose, but not the torque required to remove the tibial implants. These results suggest that the amount of compact bone surrounding a titanium implant affects the resistance to unscrewing.

In a rabbit tibial metaphysis research, threaded hydroxyapatite-coated implants made of commercially pure (CP) titanium were used (20). The controls were uncoated titanium screw implants made by CP that were placed in the opposing leg. Histomorphometric analysis was performed on the semi-loaded implants 6 weeks and 1 year after placement. At six weeks of follow-up, there was increased direct bone contact with the hydroxyapatite-coated implants, though not significantly more. With the uncoated CP titanium controls, there was notably greater direct bone-to-implant contact one year after placement. Three distinct surface topographies (21) were explored for the surfaces, and screw-shaped implants were made with two blasted surfaces with varying surface roughness levels and one surface that was left as machined or turned. The bone reaction to the rotated implants and the response to the two blasted implant surfaces were compared after a year in rabbit bone. The two blasted surfaces showed statistically significant increases in removal torque and percentage of bone-to-metal contact, indicating firmer bone fixation.

Wennerberg examined the bone response to titanium screws that were sold commercially and had two distinct levels of surface roughness (22). After the surface roughness of the implants was assessed, they were implanted in rabbit tibiae and blasted with 25- and 250- $\mu\text{m}$  particles of aluminum oxide. Implants blasted with 25- $\mu\text{m}$  particles showed a considerably higher bone-to-metal contact after 4 weeks than implants blasted with 250- $\mu\text{m}$  particles. This study suggests a short-term disadvantage for bone tissue when surface roughness is greatly enhanced as opposed to moderately increased. A comparison was made (23) between the resistance to removal torque forces for two distinct surface textures of commercially pure titanium implants that were screw-shaped. After six weeks of implantation in rabbits, it was discovered that the removal torque for implants with rough surfaces was much higher than that of implants with smooth surfaces. Because thick sections are produced by the most commonly used histology techniques, it is challenging to collect quantitative and comprehensive information on the orientation and morphology of cells adhering to implants (24). Cell shape has not been ascertained using the laborious method of taking serial sections and creating a three-dimensional reconstruction. These kinds of studies are necessary because they would show how cells migrate and adhere to implant surfaces and how they should function once they are there.

## CONCLUSIONS

The results of our study showed that the sandblasted and acid-etched surfaces have greater osteoblast activity than the machined ones, which is statistically significant only during the later phases of healing. The sandblasted acid-etched surfaces promote, within the limits of this study, an increase in the number of osteoblasts in contact with the implant surface.

## REFERENCES

1. Adell R. Tissue integrated prostheses in clinical dentistry. *International dental journal*. 1985;35(4):259-265.
2. Brunette DM. The effects of implant surface topography on the behavior of cells. *Int J Oral Maxillofac Implants*. 1988;3(4):231-246.
3. Rich A, Harris AK. Anomalous preferences of cultured macrophages for hydrophobic and roughened substrate. *Journal of Cell Science*. 1981;50:1-7. doi:https://doi.org/10.1242/jcs.50.1.1
4. Zamira Kalemaj, Scarano A, Luca Valbonetti, Rapone B, Felice Roberto Grassi. Bone Response to Four Dental Implants with Different Surface Topographies: A Histologic and Histometric Study in Minipigs. *The International journal of periodontics & restorative dentistry*. 2016;36(5):745-754. doi:https://doi.org/10.11607/prd.2719
5. Salthouse TN. Some aspects of macrophage behavior at the implant interface. *Journal of Biomedical Materials Research*. 1984;18(4):395-401. doi:https://doi.org/10.1002/jbm.820180407
6. Göthlin G, Ericsson JL. On the histogenesis of the cells in fracture callus. Electron microscopic autoradiographic observations in parabiotic rats and studies on labeled monocytes. *Virchows Archiv B, Cell Pathology*. 1973;12(4):318-329.
7. ROVENSKY Y, SLAVNAJA I, VASILIEV J. Behaviour of fibroblast-like cells on grooved surfaces. *Experimental Cell Research*. 1971;65(1):193-201. doi:https://doi.org/10.1016/s0014-4827(71)80066-6
8. Hong HL, Brunette DM. Effect of cell shape on proteinase secretion by epithelial cells. *Journal of Cell Science*. 1987;87 (Pt 2):259-267. doi:https://doi.org/10.1242/jcs.87.2.259
9. Folkman J, Moscona A. Role of cell shape in growth control. *Nature*. 1978;273(5661):345-349. doi:https://doi.org/10.1038/273345a0
10. BenZe'ev A. Cell Shape, the Complex Cellular Networks, and Gene Expression. In: Shay JW, ed. *Cell and Muscle Motility*.

- Springer US; 1985:23-53. doi:[https://doi.org/10.1007/9781475747232\\_2](https://doi.org/10.1007/9781475747232_2)
11. A Piattelli, M Piattelli, Romasco N, P Trisi. Histochemical and laser scanning microscopy characterization of the hydroxyapatite-bone interface: an experimental study in rabbits. *PubMed*. 1994;9(2):163-168.
  12. Thomas KA, Cook SD. An evaluation of variables influencing implant fixation by direct bone apposition. *Journal of Biomedical Materials Research*. 1985;19(8):875-901. doi:<https://doi.org/10.1002/jbm.820190802>
  13. Buser D, Schenk RK, Steinemann S, Fiorellini JP, Fox CH, Stich H. Influence of surface characteristics on bone integration of titanium implants. A histomorphometric study in miniature pigs. *Journal of Biomedical Materials Research*. 1991;25(7):889-902. doi:<https://doi.org/10.1002/jbm.820250708>
  14. Martin JY, Schwartz Z, Hummert TW, et al. Effect of titanium surface roughness on proliferation, differentiation, and protein synthesis of human osteoblast-like cells (MG63). *Journal of Biomedical Materials Research*. 1995;29(3):389-401. doi:<https://doi.org/10.1002/jbm.820290314>
  15. Piattelli A, Scarano A, Piattelli M. Detection of alkaline and acid phosphatases around titanium implants: a light microscopical and histochemical study in rabbits. *Biomaterials*. 1995;16(17):1333-1338. doi:[https://doi.org/10.1016/0142-9612\(95\)91049-5](https://doi.org/10.1016/0142-9612(95)91049-5)
  16. Kalđerović MR, Schreckenbach JP, Graf HL. Titanium dental implant surfaces obtained by anodic spark deposition – From the past to the future. *Materials Science and Engineering: C*. 2016;69:1429-1441. doi:<https://doi.org/10.1016/j.msec.2016.07.068>
  17. Klokkevold PR, Nishimura RD, Adachi M, Caputo A. Osseointegration enhanced by chemical etching of the titanium surface. A torque removal study in the rabbit. *Clinical Oral Implants Research*. 1997;8(6):442-447. doi:<https://doi.org/10.1034/j.1600-0501.1997.080601.x>
  18. Cordioli G, Majzoub Z, Piattelli A, Scarano A. Removal torque and histomorphometric investigation of 4 different titanium surfaces: an experimental study in the rabbit tibia. *Int J Oral Maxillofac Implants*. 2000;15(5):668-674.
  19. Bozoglan A, Dundar S, Yildirim TT, et al. Effects of Different Levels of Restraint Stress on Bone–Implant Contact. *Journal of Craniofacial Surgery*. 2019;30(4):1294-1297. doi:<https://doi.org/10.1097/scs.00000000000005104>
  20. Scarano A, Perrotti V, Artese L, et al. Blood vessels are concentrated within the implant surface concavities: a histologic study in rabbit tibia. *Odontology*. 2013;102(2):259-266. doi:<https://doi.org/10.1007/s10266-013-0116-3>
  21. Wennerberg A, A Ektessabi, T Albrektsson, Johansson C, Andersson B. A 1-year follow-up of implants of differing surface roughness placed in rabbit bone. *Int J Oral Maxillofac Implants*. 1997;12(4):486-494.
  22. Wennerberg A, T Albrektsson, Andersson B. Bone tissue response to commercially pure titanium implants blasted with fine and coarse aluminum oxide particles. *PubMed*. 1996;11(1):38-45.
  23. Carlsson L, T Röstlund, B Albrektsson, T Albrektsson. Removal torques for polished and rough titanium implants. *Int J Oral Maxillofac Implants*. 1988;3(1):21-24.
  24. Brunette DM, Ratkay J, B. Chehroudi. 16. Behaviour of Osteoblasts on Micromachined Surfaces. *University of Toronto Press eBooks*. Published online January 31, 1991. doi:<https://doi.org/10.3138/9781442671508-020>

# SURGICAL TRANSPOSITION OF THE MANDIBULAR ALVEOLAR NERVE: A CASE REPORT

L. Tomaselli

*Correspondence to:*

Luigi Tomaselli, DDS, MS

Private practice,

Via Azzurra 26,

40138 Bologna, Italy

e-mail: gigitomaselli@gmail.com

## ABSTRACT

Dental implant placement offers a predictable and long-term solution for tooth loss. However, severe bone resorption in the posterior mandible can pose a challenge due to the proximity of the inferior alveolar nerve. Surgical transposition of the mandibular alveolar nerve emerges as a viable technique to facilitate implant placement in such cases. This paper describes a case report of surgical transposition of the mandibular alveolar nerve, exploring the rationale, surgical technique, and outcomes for implant rehabilitation.

**KEYWORDS:** *alveolar bone atrophy, dental implants, nerve, injury, jaw surgery, paresthesia*

## INTRODUCTION

Dental implants have become a cornerstone of modern dentistry, offering superior functionality and aesthetics compared to traditional dentures. However, anatomical limitations can make placing implants in the posterior mandible challenging. The inferior alveolar nerve, responsible for sensation in the lower lip, chin, and teeth, traverses the mandible within the mandibular canal. In cases of severe bone resorption, particularly following tooth loss and subsequent alveolar ridge atrophy, the available bone height above the mandibular alveolar nerve might be insufficient for safe and stable implant placement. Repositioning can be classified into nerve lateralization and surgical transposition of the inferior alveolar nerve (STIN). Nerve lateralization involves shifting the inferior laterally to the implant site posterior to the mental foramen without a corticectomy around the mental foramen or lateral movement of the mental nerve (1, 2). STIN results in slight posterior displacement of the mental nerve, which may lead to retraction of the incisive nerve.

Surgical transposition of the inferior alveolar nerve offers a solution by carefully repositioning the nerve within the mandible, creating space for implant placement (3,4). STIN can significantly improve implant-based rehabilitation's predictability and success rates in patients with compromised bone anatomy.

When the residual alveolar bone height above the inferior alveolar nerve is less than ideal (typically less than 3-4mm), placing implants poses a significant risk of nerve damage. Inferior alveolar nerve injury can lead to permanent numbness, paresthesia (tingling), and debilitating pain (5). STIN allows the surgeon to safely move the nerve course within the mandible, creating sufficient space for implant placement while ensuring nerve integrity (6, 7).

In STIN, the surgeon should gain access to the inferior alveolar nerve by creating a surgical flap in the edentulous area. A window is opened in the lateral cortical plate of the mandible until the mental foramen. The cortical bone is detached, removed carefully, and conserved in an isotonic solution to be allocated back in the window slot at the end of the surgery, ensuring protection of the inferior alveolar nerve. The nerve is carefully identified and dissected free from



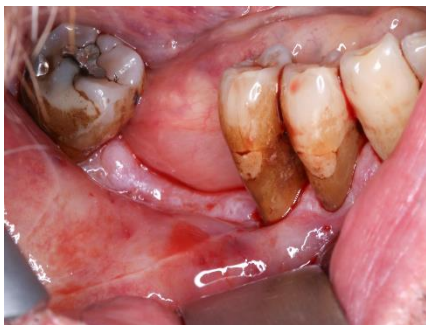the alveolar canal. Studies have shown promising results with STIN for implant placement. Success rates exceeding 90% have been reported, with minimal long-term complications (8). However, potential risks should be considered.

Temporary numbness or tingling in the lip and chin is common after surgery, typically resolving within weeks or months. Although uncommon, permanent nerve injury is a potential risk associated with STIN. Bone resorption around the implant can impact long-term success (8). Here, a case report is reported, and pertinent literature is discussed.

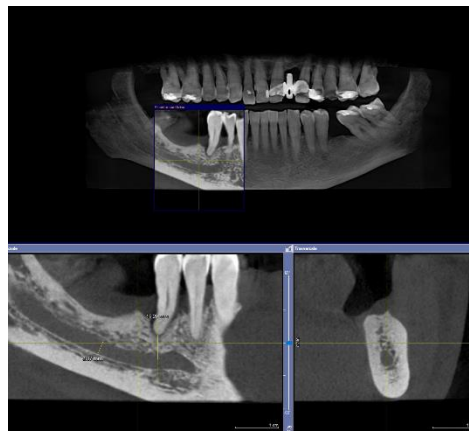
## CASE REPORT

The patient presented to our clinic complaining about his edentulism. He was 50 years old and was a light smoker. At the clinical evaluation, he had a far-advanced periodontal disease and bone defects following endo-perio failure (Fig. 1). The choice of STIN technique was made considering the geometry of the horizontal bone defect in the area: lack of the bone peak in the mesial side of the defect, would not have guided the vertical bone augmentation leading to failure of the regenerative process.

The preoperative work-up included an assessment of the inferior alveolar nerve using appropriate diagnostic records, such as a panoramic radiograph and computed tomography scan (Fig. 2).



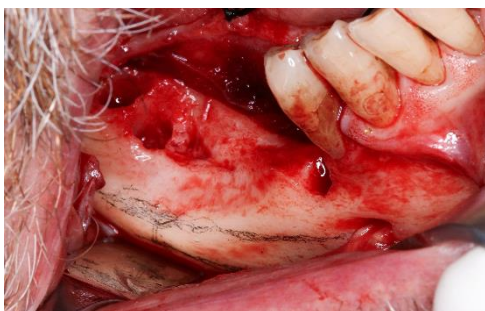
**Fig. 1.** Endo-oral photo showing partial mandibular edentulism in posterior right mandible.



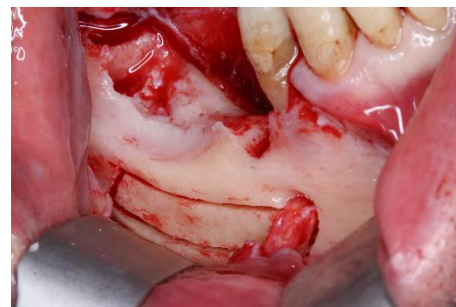**Fig. 2.** Panoramic radiograph and CT scan for the preoperative work-up.

The risk of postoperative neurosensory disturbances following the inferior alveolar nerve repositioning was discussed during preoperative consultation with the patients.

Surgically, a crestal incision with anterior- and posterior-releasing incisions was made, and a labial mucoperiosteal flap was reflected, exposing the alveolar ridge and buccal cortex (Fig. 3). Then a cortical bone window located posterior to the mental foramen was performed via an osteotomy (Fig. 4).

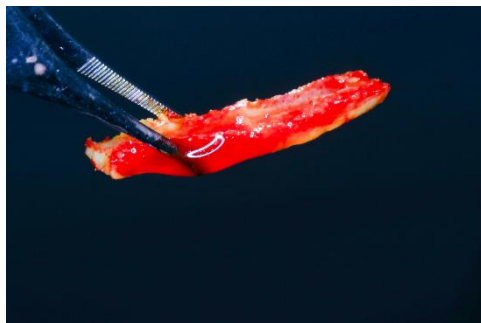

**Fig. 3.** Crestal incision exposing the alveolar ridge and buccal cortex. Inferior alveolar canal is designed.



**Fig. 4.** Osteotomy of a cortical bone window located posterior to the mental foramen.


A bone block corresponding to the lateral wall of the mandibular canal was removed using a sonic tip under copious saline solution for irrigation (Fig. 5).



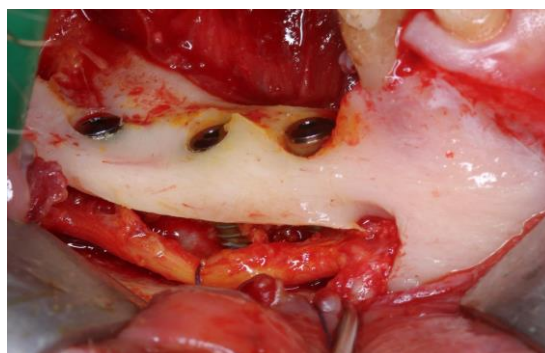
**Fig. 5.** *Cortical bone window removed.*

Autologous bone chips were collected using a scraper before removing the cortical lateral window bone block (Fig. 6, 7).

The area around the nerve was thoroughly irrigated so the nerve bundle could be seen. The neurovascular bundle inside the canal was freed using special curettes and was moved laterally. Then, implants were positioned beside the nerve, gently securing the nerve laterally with sutures (Fig. 8).

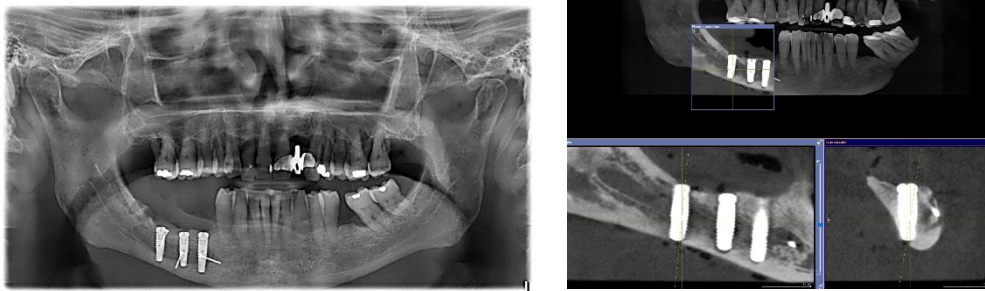


**Fig. 6, 7.** *Autologous bone collected by mean of a scraper and the quantity of collected bone.*



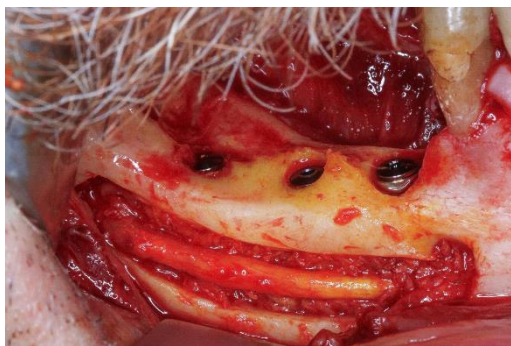**Fig. 8.** *Implants positioned beside the inferior alveolar nerve.*

The implants were long enough to pass the cortical bone and engage the basal body below the canal to achieve sufficient primary stability (Fig. 9, 10).

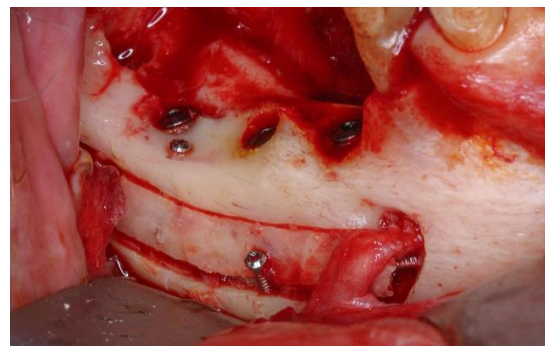

**Fig. 9, 10.** Orthopantomography and TC-scan show implants engaging the basal body below the canal, achieving sufficient primary stability.

Then, the implant surface was covered with previously collected autologous bone (Fig. 11), the nerve was repositioned, and the lateral cortical bone was repositioned and fixed with three mini-screws (Fig. 12).



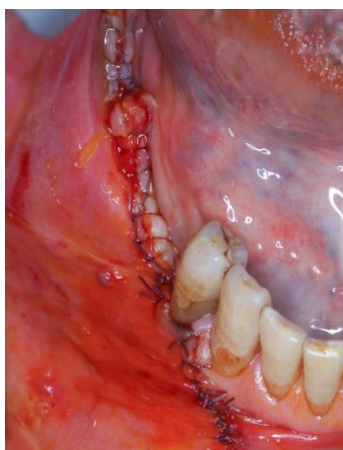
**Fig. 11.** The neurovascular bundle repositioned inside the mandibular canal on a bed of autologous bone previously collected to cover implant surfaces.



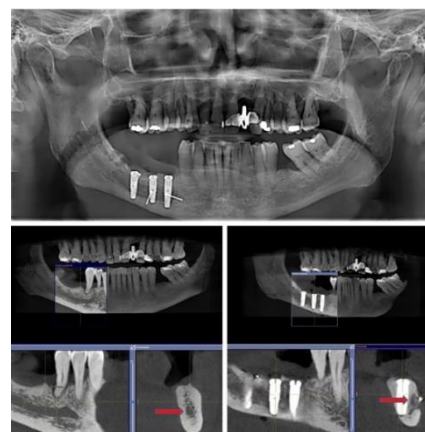
**Fig. 12.** The cortical bone window is repositioned and fixed with mini screws.

Finally, the area was sutured (Fig 13). Then, antibiotics and corticosteroids were prescribed because of the extensiveness and duration of surgery. Using corticosteroids pre- and post-operatively STIN helps diminish swelling and nerve compression.

The patient was discharged and had numbness for one month. Then, the alveolar nerve function completely recovers (Fig. 14).



**Fig. 13.** The sutured area.



**Fig. 14.** TC- scan pre and post-surgery comparison. The red arrow indicates the transposition of the nerve bundle. A shield of autogenous bone is protecting the medial side of nerve by the direct contact with the implant to avoid possible neuropathy.

## DISCUSSION

STIN is a technique that has been used for more than 20 years with good clinical results (9). STIN is a technique for expert oral surgeons and carries potential complications, with temporary inferior homolateral lip numbness the most frequent. In combination with dental implant insertion, STIN offers advantages, such as increasing implant stability due to the bi-cortical insertion and a “controlled” risk of inferior alveolar nerve damage (10) due to a direct vision of the surgical field. This procedure can be used for implant placement in an edentulous atrophic posterior mandible with careful pre-operative surgical and prosthetic planning, imaging, and exact surgical technique (11).

Since it has some advantages, STIN has been used widely as an alternative to short implants or bone grafts for osteo-integrated implant placement in the posterior atrophic mandible. The bone graft technique requires extended healing due to the graft integration process. In contrast, short implants have less expected success in case of peri-implant infection and bone resorption.

STIN has not been popular because of the high risk of damaging the inferior alveolar nerve. Short implants, osteo-regeneration methods, and new prosthetic solutions using inter-foraminal implants have further reduced the use of STIN. However, there are cases in which this surgical procedure is essential to obtain good morphologic and functional jaw rebalancing.

## CONCLUSIONS

STIN is a superior technique in decreasing the need for bone grafting with the immediate insertion of dental implants, thus reducing the overall treatment time, cost, and donor-site morbidity (12). Since the major risk of STIN is neurologic deficiencies of the inferior alveolar bundle and its terminal branches, it should be performed under a strict and meticulous protocol. When used in posterior severely atrophied mandibles, surgical transposition can permit the placement of implants with adequate length and good initial stabilization as used in routine sites, with the same favorable prognosis (13). In addition, STIN allows implants to be placed at a greater depth, enabling an appropriate emergence profile and the desired form of prosthesis.

Finally, implant placement eliminates the need for sequential surgical procedures, minimizing treatment duration and patient inconvenience compared with procedures such as bone grafting, which may require a more extended healing period. STIN is primarily performed to prevent inferior alveolar nerve injury in the posterior mandible in cases with inadequate bone height and anatomical and prosthetic constraints, hindering conventional bone grafting procedures. The reported case adds additional strength to using this technique in selected cases and with a very careful procedure.

## REFERENCES

1. Peleg M, Mazor Z, Chaushu G, Garg AK. Lateralization of the inferior alveolar nerve with simultaneous implant placement: a modified technique. *Int J Oral Maxillofac Implants*. 2002;17(1):101-6.
2. Suzuki D, Bassi AP, Lee HJ, Alcántara PR, de Sartori IM, Luvizuto ER, Facó EF, Faot F. Inferior alveolar nerve lateralization and implant placement in atrophic posterior mandible. *J Craniofac Surg*. 2012 Jul;23(4): e347-9.
3. Lorean A, Kablan F, Mazor Z, Mijiritsky E, Russe P, Barbu H, Levin L. Inferior alveolar nerve transposition and reposition for dental implant placement in edentulous or partially edentulous mandibles: a multicenter retrospective study. *Int J Oral Maxillofac Surg*. 2013;42(5):656-9.
4. Morrison A, Chiarot M, Kirby S. Mental nerve function after inferior alveolar nerve transposition for placement of dental implants. *J Can Dent Assoc*. 2002;68(1):46-50.
5. Vetromilla BM, Moura LB, Sonogo CL, Torriani MA, Chagas OL Jr. Complications associated with inferior alveolar nerve repositioning for dental implant placement: a systematic review. *Int J Oral Maxillofac Surg*. 2014;43(11):1360-6.
6. Romanos GE. Severe Atrophy of the Posterior Mandible and Inferior Alveolar Nerve Transposition. *Int J Periodontics Restorative Dent*. 2021;41(5): e199-e204.
7. Palacio García-Ochoa A, Pérez-González F, Negrillo Moreno A, et al. Complications associated with inferior alveolar nerve reposition technique for simultaneous implant-based rehabilitation of atrophic mandibles. A systematic literature review. *J Stomatol Oral Maxillofac Surg*. 2020;121(4):390-396.
8. Van Vo N, Nguyen T, Ta QD, Truong BC. Contralateral Inferior Alveolar Nerve Transposition for Simultaneous Dental Implant Placement on a Unilateral Reconstructed Mandible: A Case Report With a 7-Year Follow-Up. *J Oral Maxillofac Surg*. 2021;79(4): 813.e1-813.e11.

9. Lorean A, Kablan F, Mazor Z, Mijiritsky E, Russe P, Barbu H, Levin L. Inferior alveolar nerve transposition and reposition for dental implant placement in edentulous or partially edentulous mandibles: a multicenter retrospective study. *Int J Oral Maxillofac Surg.* 2013;42(5):656-9.
10. Hassani A, Motamedi MHK, Saadat S. Inferior alveolar nerve transposition for implant placement. *Oral Maxillofac Surg.* 2013;26.
11. Vasconcelos Jde A, Avila GB, Ribeiro JC, Dias SC, Pereira LJ. Inferior alveolar nerve transposition with involvement of the mental foramen for implant placement. *Med Oral Patol Oral Cir Bucal.* 2008;13(11):E722-5.
12. Ferrigno N, Laureti M, Fanali S. Inferior alveolar nerve transposition in conjunction with implant placement. *Int J Oral Maxillofac Implants.* 2005;20(4):610-20.
13. Del Castillo Pardo de Vera JL, Chamorro Pons M, Cebrián Carretero JL. Repositioning of the inferior alveolar nerve in cases of severe mandibular atrophy. a clinical case. *Med Oral Patol Oral Cir Bucal.* 2008 ;13(12):E778-82.

*Evaluation Study*

# THE EFFICACY OF TOOTHPASTE IN CONTROLLING DENTAL BACTERIAL LOADING

S.M. Tecchio<sup>1</sup>, A. Zama Montagnana<sup>1</sup> and E. Isufaj<sup>2</sup>

<sup>1</sup>University of Ferrara, Ferrara, Italy

<sup>2</sup>Albanian University, Tirana, Albania

*Correspondence to:*

Evisa Isufaj, MD

Albanian University,

Tirana, Albania

e-mail: [e.isufaj@au.edu.al](mailto:e.isufaj@au.edu.al)

## ABSTRACT

The aim of this study was to assess the anti-plaque effects of a toothpaste containing 0.3% triclosan, 2% copolymer, and 0.2% sodium fluoride (TCSF) in subjects with moderate plaque-induced gingivitis. A total of 10 patients with gingivitis were enrolled. None of these patients have previously been treated for periodontal disease and demonstrated radiographic evidence of bone loss. Inclusion characteristics included good general health, male and female subjects aged 18–70. Informed consent was obtained from all individual participants included in the study. Patients underwent professional oral hygiene (POH) and were instructed to use toothpaste TCSF at home twice daily for 2 weeks. Microbial analyses were performed before POH and at the end of the second week and statistically compared to the initial results. The statistic t-student-test was used to outline the statistically relevant results. All subjects completed the study. The results showed statistically significant reductions in total bacterial loading. The overall conclusion was that TCSF was a comprehensive dentifrice significantly reducing bacterial loading.

**KEYWORDS:** *toothpaste, oral hygiene, oral health, gingivitis, periodontal disease*

## INTRODUCTION

Oral home-based hygiene is fundamental to ensure good health and prevent periodontal pathology. Poor dental hygiene can result in tooth decay, gingivitis, periodontitis, tooth loss, bad breath (halitosis), fungal infection, and gum diseases. Using a toothbrush is the most critical oral hygiene measure (1). Fair to poor oral hygiene increases the risk of periodontitis by two- to five-fold. This risk can be reduced by regular toothbrushing and dental visits (2). The most effective way to prevent dental disease is to control the production of dental plaque. Plaque is a soft, thin layer that deposits on teeth, gums, and all appliances fitted in the mouth. It is formed by microbial action. Dietary sugars, particularly sucrose, contribute to plaque formation, and their presence increases plaque formation and thickness rate. Removing plaque from the teeth and related areas is essential for maintaining a healthy mouth (3).

There are various tools that each patient can use: manual toothbrush, electric toothbrush, interdental brush, dental floss, and mouthwash. The literature has tried to demonstrate the most effective, but this does not alter the fact that the crucial point is to carry out home hygiene procedures. There is moderate quality evidence that powered toothbrushes provide a statistically significant benefit compared with manual toothbrushes regarding reducing short- and long-term plaque (4). On the other hand, using toothpaste to improve oral hygiene was relevant. The study aims to evaluate the

Received: 03 September 2021  
Accepted: 01 October 2021

Copyright © by LAB srl 2021 ISSN 2975-1276

This publication and/or article is for individual use only and may not be further reproduced without written permission from the copyright holder. Unauthorized reproduction may result in financial and other penalties. Disclosure: All authors report no conflicts of interest relevant to this article.

effectiveness of toothpaste in reducing oral bacterial plaque. The investigated toothpaste is composed of the following components: Sodium Fluoride (NaF), Hydrated Silica, Sodium Lauryl Sulfate (SLS), Calcium Pyrophosphate and Tetrasodium Pyrophosphate, Arginine, Zinc Oxide and Zinc Citrate (5-7).

Sodium Fluoride (NaF) is primarily used to reduce the prevalence of caries and to enhance enamel remineralization (8, 9). The antibacterial and cariostatic effects of fluorides have been extensively accepted (10), and the widespread use of fluorides has been attributed to the decline of dental caries in Western countries in recent years (11).

Fluorides act primarily by forming fluorohydroxyapatite crystals that are more resistant to organic acids than hydroxyapatite crystals of tooth enamel (12). It has also been shown to reduce organic acid production in cariogenic bacteria such as *Streptococcus mutans* (13). The main ingredient of the silica used in abrasives is high-purity amorphous silicon dioxide, and there are varieties of different types whose properties vary depending on the production method. Since it has been an abrasive, silica is added for rubbing, grinding, or polishing. It removes substances that adhere to the surface of the teeth without scratching and enhances the natural shine. Silica is very suitable for toothpaste containing fluoride because no insoluble salt is formed when it reacts with fluoride. As its refractive index is lower than other abrasives, silica can be used to make transparent gel toothpaste.

A mixture of sodium alkyl sulfates consisting mainly of sodium dodecyl sulfate. It is a white or pale-yellow powder or crystals with a slight characteristic odor. Freely soluble in water; partly soluble in alcohol. The adverse effects of SLS have resulted in the development of toothpaste and mouthwashes with alternative surfactants such as sodium lauryl sarcosinate.

Calcium Pyrophosphate and Tetrasodium Pyrophosphate supplementation in toothpaste or mouth rinse will increase the concentration of these ions in the oral cavity. In this way, they improve remineralization and increase fluoride uptake. Pyrophosphates prevent the formation of calcium phosphate, a calcified inorganic material that makes up about 75% of the tartar, preventing its deposit on the teeth.

Arginine is a prebiotic amino acid that has been shown to affect oral biofilm ecology. Within the limitations of the in vitro study, past research concluded that the incorporation of 2% arginine in NaF toothpaste significantly enhances the antimicrobial effect against caries-generating bacteria (*S. mutans*) when compared to NaF (alone). In comparison, 4% and 8% arginine in NaF toothpaste were ineffective in enhancing the antimicrobial effect of NaF. The 2% Arg-NaF toothpaste might maintain better ecological homeostasis by upregulating the non-mutant streptococci (*S. sanguis* and *S. gordonii*).

Zinc is added to toothpaste and mouthwashes as zinc chloride or citrate. Zinc is a relatively non-toxic, noncumulative essential trace element. Zinc inhibits the glucose uptake pathway by *Streptococcus mutans*, *Streptococcus sanguis*, *Actinomyces naeslundii*, and glucose metabolism to lactic acid.

The present study aimed to assess the effects of a toothpaste containing 0.3% triclosan, 2% copolymer, and 0.2% sodium fluoride (TCSF) in subjects with moderate plaque-induced gingivitis.

## MATERIAL AND METHODS

This study involved the selection of 10 healthy patients who presented gingivitis. Inclusion characteristics included good general health, male and female subjects aged 18–70. Informed consent was obtained from all individual participants included in the study. Patients underwent professional oral hygiene (POH) and were instructed to use toothpaste at home twice daily for 2 weeks. Microbial analyses were performed before POH and at the end of the second week and statistically compared to the initial results. The deepest periodontal pocket site of the oral cavity was used for microbiological analysis. The sites were isolated using cotton rolls. Sterile absorbable paper points (size 60) were used to collect subgingival samples and were immediately transferred to the microbiological lab for processing with Real-Time Polymerase Chain Reaction (PCR). *Aggregatibacter actinomycetemcomitans* (AA), *Porphyromonas gingivalis* (PG), *Tannerella forsythia* (TF), *Treponema denticola* (TD), *Fusobacterium Nucleatum* (FN), *Campylobacter rectus* (CR) and Total Bacterial Loading (CBT) were evaluated.

### *Real-time polymerase chain reaction (PCR)*

Probes oligonucleotides were designed based on 16S rRNA gene sequences of the Human Oral Microbiome Database (HOMD 16S rRNA RefSeq Version 10.1), counting 845 entries. All the sequences were aligned to find either consensus sequences or less conservative spots. Two real-time polymerase chain reaction (PCR) runs were performed for each sample. The first reaction quantified the total amount of bacteria using two degenerate primers and a single probe matching a highly conserved 16S ribosomal RNA gene sequence. The second reaction detected and quantified all selected bacteria in two multiplex PCR. This reaction included twelve primers and six particular probes for each species.

Oligonucleotide concentrations and PCR conditions were optimized to ensure sensitivity, specificity, and no inhibitions in case of unbalanced target amounts. Absolute quantification assays were performed using the Applied Biosystems 7500 Sequence Detection System. The amplification profile was initiated by a 10 min incubation period at 95°C to activate polymerase, followed by a two-step amplification of 15 s at 95°C and 60 s at 57°C for 40 cycles. All these experiments, including nontemplate controls, were performed to exclude contamination of reagents.

Plasmids containing synthetic DNA target sequences (Eurofins MWG Operon, Ebersberg Germany) were standard for the quantitative analysis. Standard curves for each target were constructed in two triplex reactions using a mix of the same plasmids in serial dilutions ranging from 10<sup>1</sup> to 10<sup>7</sup> copies. There was a linear relationship between the threshold cycle values plotted against the copy number log over the entire range of dilutions (data not shown). The copy numbers for individual plasmid preparations were estimated using the Thermo NanoDrop spectrophotometer.

The absolute quantification of total bacterial genome copies in samples allowed for calculating the relative number of red complex species. Plasmid purification and handling were performed in a separate laboratory with dedicated pipettes to prevent contamination of samples and polymerase chain reactions. The SPSS program and paired simple statistic T-test were used for the statistical analysis to detect statistically significant differences.

## RESULTS

Both clinical and microbiological parameters showed improvements. After 15 days of toothpaste, TCSF microbiological analysis significantly reduced total bacterial loading (Table I).

**Table I.** Paired sample test.

		pairwise differences					t	Df	Sig. (2-code)
		Mean	Standard deviation	Mean Error	95% confidence interval for the difference				
					inferior	superior			
Couple 1	AA1-AA2	401639.66667	1253679.07356	417893.02452	-562023.37595	1365302.70928	.961	9	.365
Couple 2	PG1-PG2	230.10000	924.99147	292.50798	-431.59903	891.79903	.787	9	.452
Couple 3	TF1-TF2	1622099.80000	2812431.86976	889369.04725	-389792.76060	3633992.36060	1.824	9	.101
Couple 4	TD1-TD2	1231941.50000	1526348.88168	482673.89702	140057.28657	2323825.71343	2.552	9	.031
Couple 5	FN1-FN2	5417714.70000	4361539.98644	1379240.04631	2297656.95003	8537772.44997	3.928	9	.003
Couple 6	CR1-CR1	20809.60000	25403.34994	8033.24460	2637.13819	38982.06181	2.590	9	.029
Couple 2	TBL1-TBL2	34725019.60000	37150995.83389	11748176.41785	8148798.16654	61301241.03346	2.956	9	.01

## DISCUSSION

Dental plaque is a major etiological factor in the causation of dental caries and plaque-induced gingival diseases. Mechanical removal using toothbrushes, toothpaste, and mouth rinses helps check pathogenic plaque build-up, thereby preventing these diseases. Effective and therapeutic plaque control is an essential aspect of personal hygiene. Appropriate toothpaste has been documented as an effective tool among plaque control measures.

The positive results obtained in this study cannot be completely related to the introduction of TCSF toothpaste during the treatment since a comparison with subjects treated with toothpaste only was not performed. Nevertheless, in the case of acute pathologies, such as gingivitis, the results provisionally demonstrate the most significant effect of using TCSF toothpaste as an adjuvant treatment is primarily related to its ability to reduce bacterial loading post-treatment. TCSF toothpaste has been shown to reduce plaque and gingivitis. Most studies on TCSF toothpaste are related to periodontitis, a highly prevalent, chronic, non-specific, and immunologically devastating disease of periodontal tissues caused by microbial infection.

It may be speculated that TCSF toothpaste's ability to promote antibacterial activity most likely contributes to an overall improvement in the patient's oral hygiene.



## CONCLUSIONS

In our opinion, the result of this clinical trial is very promising with regards to the benefits of using TCSF toothpaste as an adjuvant in the standard treatment of gingivitis to reduce bacterial loading, contributing to an overall improvement in the oral health of the patient. Further studies with a larger sample size are required to confirm the results obtained.

## REFERENCES

1. Hitz Lindenmüller I, Lambrecht JT. Oral care. *Current Problems in Dermatology*. 2011;40:107-115. doi:<https://doi.org/10.1159/000321060>
2. Lertpimonchai A, Rattanasiri S, Arj-Ong Vallibhakara S, Attia J, Thakkinstian A. The association between oral hygiene and periodontitis: a systematic review and meta-analysis. *International Dental Journal*. 2017;67(6):332-343. doi:<https://doi.org/10.1111/idj.12317>
3. Winfield AJ, Richards RME. *Pharmaceutical Practice by A. J. Winfield | Open Library*. 2nd ed. Churchill Livingstone; 1998:421-423.
4. Yaacob M, Worthington HV, Deacon SA, et al. Powered versus manual toothbrushing for oral health. *Cochrane Database of Systematic Reviews*. 2014;(6). doi:<https://doi.org/10.1002/14651858.cd002281.pub3>
5. Rajwani AR, Hawes SND, To A, Quaranta A, Rincon Aguilar JC. Effectiveness of Manual Toothbrushing Techniques on Plaque and Gingivitis: A Systematic Review. *Oral Health & Preventive Dentistry*. 2020;18(1):843-854. doi:<https://doi.org/10.3290/j.ohpd.a45354>
6. Haught JC, Xie S, Circello B, et al. Lipopolysaccharide and lipoteichoic acid binding by antimicrobials used in oral care formulations. *American journal of dentistry*. 2016;29(6).
7. Vranić E, Lačević A, Mehmedagić A, Uzunović A. Formulation ingredients for toothpastes and mouthwashes. *Bosnian Journal of Basic Medical Sciences*. 2004;4(4):51-58. doi:<https://doi.org/10.17305/bjbms.2004.3362>
8. Arnold WH, Dorow A, Langenhorst S, Gintner Z, Bánóczy J, Gaengler P. Effect of fluoride toothpastes on enamel demineralization. *BMC Oral Health*. 2006;6(1). doi:<https://doi.org/10.1186/1472-6831-6-8>
9. Silverstone. Dynamic factors affecting lesion initiation and progression in human dental enamel. Part I. The dynamic nature of enamel caries. *Quintessence international (Berlin, Germany : 1985)*. 1988;19(10):683-711.
10. Rošin-Grget K. The cariostatic mechanisms of fluoride. *Acta Medica Academica*. 2013;42(2):179-188. doi:<https://doi.org/10.5644/ama2006-124.85>
11. Yoshihara A, Sakuma S, Kobayashi S, Miyazaki H. Antimicrobial effect of fluoride mouthrinse on mutans streptococci and lactobacilli in saliva. *Pediatric Dentistry*. 2001;23(2):113-117.
12. Buzalaf MAR, Pessan JP, Honório HM, Ten Cate JM. Mechanisms of action of fluoride for caries control. *Monographs in oral science*. 2011;22:97-114. doi:<https://doi.org/10.1159/000325151>
13. Bradshaw DJ, Marsh PD, Hodgson RJ, Visser JM. Effects of Glucose and Fluoride on Competition and Metabolism within in vitro Dental Bacterial Communities and Biofilms. *Caries Research*. 2002;36(2):81-86. doi:<https://doi.org/10.1159/000057864>

Evaluation Study

## CALCIUM SULFATE ACTS ON MESENCHYMAL STEM CELLS: AN EXPRESSION PROFILE EVALUATION

P. Daliu<sup>1</sup>, E. Isufaj<sup>2</sup>, M. Martinelli<sup>3</sup>

<sup>1</sup>Dept Pharmacology, Albanian University, Tirana, Albania

<sup>2</sup>Dental School, Albanian University, Tirana, Abania

<sup>3</sup>Dept of Medical and Surgical Sciences, University of Bologna, Bologna, Italy

Correspondence to:

Marcella Martinelli, PhD

Department of Medical and Surgical Sciences,

University of Bologna,

40138 Bologna, Italy

e-mail: marcella.martinelli@unibo.it

### ABSTRACT

Calcium sulfate, with the chemical formula  $\text{CaSO}_4$ , exists in several hydrated and anhydrous forms, including gypsum (calcium sulfate dihydrate), hemihydrate (plaster of Paris), and anhydrite. It is insoluble in water and exhibits excellent thermal stability, making it suitable for high-temperature applications. Calcium sulfate is non-toxic and environmentally friendly, contributing to its widespread use in various fields. For this reason, we studied how calcium sulfate can induce osteoblast differentiation in dental pulp-derived stem cells by measuring the expression levels of bone-related and extracellular matrix-related genes using real-time -Polymerase Chain Reaction (real-time -PCR). The obtained results showed an upregulation of the SP7 and MMP7 genes. Calcium sulfate-based materials are used in dental procedures for socket preservation, guided bone regeneration, and sinus augmentation. In periodontal surgery, calcium sulfate barriers prevent soft tissue ingrowth and promote bone regeneration around dental implants. Calcium sulfate can activate several genes of mesenchymal stem cells, stimulating bone regeneration.

**KEYWORDS:** *calcium sulfate, dental implants, bone regeneration, gene expression*

### INTRODUCTION

Calcium sulfate, with the chemical formula  $\text{CaSO}_4$ , exists in several hydrated and anhydrous forms, including gypsum (calcium sulfate dihydrate), hemihydrate (plaster of Paris), and anhydrite. It is insoluble in water and exhibits excellent thermal stability, making it suitable for high-temperature applications. Calcium sulfate is non-toxic and environmentally friendly, contributing to its widespread use in various fields (1, 2).

Best known for its industrial purposes, calcium sulfate has also found valuable applications in the medical field due to its biocompatibility, resorbability, and versatility. Calcium sulfate serves as a bone graft substitute in orthopedic and dental surgery. Its porous structure and resorbability facilitate bone regeneration by providing a scaffold for new bone

Received: 03 September 2021  
Accepted: 01 October 2021

Copyright © by LAB srl 2021 ISSN 2975-1276

This publication and/or article is for individual use only and may not be further reproduced without written permission from the copyright holder. Unauthorized reproduction may result in financial and other penalties. Disclosure: All authors report no conflicts of interest relevant to this article.

formation. Calcium sulfate implants gradually dissolve, releasing calcium and sulfate ions that promote osteogenesis and angiogenesis and are eventually replaced by new bone tissue (3).

Calcium sulfate-based hemostatic agents are utilized to control bleeding during surgical procedures. When applied to bleeding sites, calcium sulfate forms a gel-like matrix that accelerates clot formation and promotes hemostasis. Its biocompatibility and absorbability minimize tissue irritation and allow safe resorption without adverse effects (4).

Calcium sulfate acts as a carrier for local drug delivery in various medical applications. Pharmaceutical agents, growth factors, antibiotics, and analgesics can be incorporated into calcium sulfate matrices and delivered directly to target tissues, such as bone defects or periodontal pockets. The controlled release of therapeutic agents from calcium sulfate carriers enhances treatment efficacy while minimizing systemic side effects.

Calcium sulfate-based materials are used in dental procedures for socket preservation, guided bone regeneration, and sinus augmentation. In periodontal surgery, calcium sulfate barriers prevent soft tissue ingrowth and promote bone regeneration around dental implants. Calcium sulfate pastes are also utilized in endodontic therapy for root canal disinfection and obturation. As calcium sulfate has a wide range of applications in regenerative dentistry, we investigated the effect of calcium sulfate on mesenchymal stem cells (MSCs) *in vitro*.

MSCs have garnered significant attention in regenerative medicine due to their multipotent differentiation capacity, immunomodulatory properties, and tissue repair and regeneration potential. Initially identified in bone marrow, MSCs can now be isolated from various tissues, including adipose tissue, umbilical cord blood, and dental pulp (5, 6). MSCs possess several key characteristics that make them valuable for regenerative medicine. MSCs can differentiate into multiple cell lineages, including osteocytes (bone cells), chondrocytes (cartilage cells), adipocytes (fat cells), myocytes (muscle cells), and even neurons (nerve cells). MSCs secrete various cytokines and growth factors that modulate the immune response, reducing inflammation and promoting tissue repair. MSCs have a high proliferation rate, allowing for the generation of sufficient cells for therapeutic use. MSCs can migrate to sites of injury or inflammation, contributing to tissue repair and regeneration (7).

MSCs can be isolated from various tissues, each with advantages and limitations. Bone marrow-derived MSCs (BM-MSCs) are the most well-studied and have been widely used in clinical applications (7, 8). However, the isolation process is invasive and yields limited cells. Adipose-derived MSCs (AD-MSCs) can be obtained through less invasive procedures and yield more cells than bone marrow. Umbilical cord-derived MSCs (UC-MSCs) offer a non-invasive source with high proliferative potential and low immunogenicity. Dental pulp stem cells (DPSCs) are another accessible source of MSCs with potential applications in dental and orthopedic regenerative therapies (9).

## MATERIALS AND METHODS

### *Dental pulp stem cells (DPSCs) isolation*

Dental pulp was extracted from the third molars of healthy subjects and digested for 1 h at 37°C in a solution containing 1 mg/ml collagenase type I and 1 mg/ml dispase, dissolved in phosphate-buffered saline (PBS) supplemented with 100 U/ml penicillin, 100 µg/ml streptomycin, and 500 µg/ml clarithromycin. The solution was then filtered using 70 µm Falcon strainers (Merck, Darmstadt, Germany) to separate mesenchymal stem cells from fibroblasts. Stem cells were cultivated in  $\alpha$ -MEM culture medium (Merck, Darmstadt, Germany) supplemented with 20% Fetal Bovine Serum (FBS), 100 µM 2P-ascorbic acid, 2 mM L-glutamine, 100 U/ml penicillin, and 100 µg/ml streptomycin (Merck, Darmstadt, Germany). The flasks were incubated at 37 °C and 5% CO<sub>2</sub>, and the medium was changed twice weekly.

DPSCs were characterized by immunofluorescence for the positive mesenchymal stem cell markers CD105, CD90, and CD73 and the negative marker CD34 described in Sollazzo et al. (10).

### *Cell treatment*

DPSCs were seeded at a concentration of  $1.0 \times 10^5$  cells/ml in 9 cm<sup>2</sup> (3 ml) wells containing DMEM supplemented with 10% serum and antibiotics added with calcium sulfate (Surgiplaster, Classimplant, Roma, Italy) at the concentration of 0.001 mg/ml. Another set of wells containing untreated cells was used as a control. The treatment was carried out at two-time points: 24 hours and 4 days.

The cells were maintained in a humidified atmosphere containing 5% CO<sub>2</sub> at 37 °C. At the end of the treatment period, the cells were lysed and processed for total RNA extraction.

*RNA isolation, reverse transcription, and quantitative real-time-PCR*

According to the manufacturer's instructions, total RNA was isolated from the cells using RNeasy Mini Kit (Qiagen, Hilden, Germany). Pure RNA was quantified using a NanoDrop 2000 spectrophotometer (Thermo Fisher Scientific, Wilmington, DE, USA).

cDNA synthesis was performed starting from 500 ng of total RNA using the PrimeScript RT Master Mix (Takara Bio Inc., Kusatsu, Japan). The reaction mixture was incubated at 37 °C for 15 min and inactivated by heating at 70 °C for 10 s. cDNA was amplified by real-time quantitative PCR using an ABI PRISM 7500 (Applied Biosystems, Foster City, CA, USA). All real-time-PCR reactions were performed in a volume of 20 µl. Each reaction contained 10 µl of 2X qPCR BIO SyGreen Mix Lo-ROX (PCR Biosystems, Ltd, London, UK), 400 nM of each primer, and 100 ng cDNA.

Custom primers designed on genes belonging to the “extracellular matrix, adhesion molecule” pathway, “osteoblast differentiation”, and “inflammation” pathway were purchased from Merck (Darmstadt, Germany). The selected genes grouped by functional pathway are listed in Table I.

All experiments were performed using non-template controls to exclude reagent contamination. Real time-PCR was performed using two analytical replicates. The amplification profile was initiated by incubation for 10 min at 95°C, followed by a two-step amplification for 15 s at 95°C and 60 s at 60°C for 40 cycles. In the final step, melt curve dissociation analysis was performed.

**Table I.** Selected genes tested in real time-PCR grouped by functional pathway.

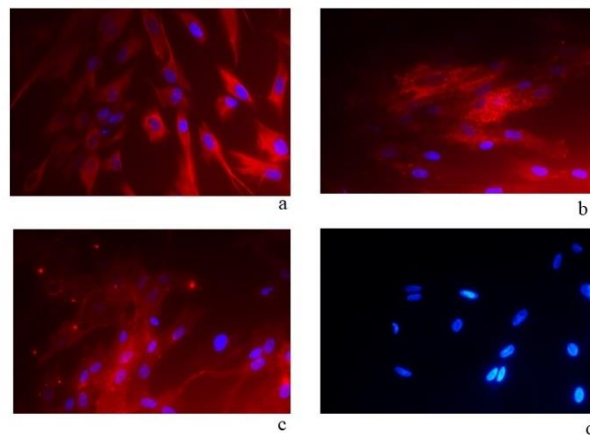
Pathway	Gene
Osteoblast differentiation	SPP1 (Osteopontin) SPARC (Osteonectin) RUNX2 (Runt-related transcription factor 2) ALP (Alkaline phosphatase) FOSL1 (FOS-like antigen 1) SP7 (Osterix) ENG (Endoglin)
Extracellular matrix, adhesion molecule	COL1A1 (Collagen type I alpha 1) COL3A1 (Collagen type III alpha 1) COL4A1 (Collagen type IV alpha 1) MMP7 (Matrix Metalloproteinase 7) MMP12 (Matrix Metalloproteinase 12) MMP14 (Matrix Metalloproteinase 14)
Inflammation	IL1a (Interleukin 1 Alpha) IL1R1 (Interleukin 1 Receptor type 1) IL6 (Interleukin 6) IL6R (Interleukin 6 Receptor)
Reference gene	RPL13 (Ribosomal protein L13)

*Statistical analysis*

The gene expression levels were normalized to the expression of the reference gene (RPL13) and expressed as fold-changes relative to the expression in untreated cells. Quantification was performed using the delta-delta Ct method.

**RESULTS**

The DPCs were phenotypically characterized using immunofluorescence. Fig. 1a shows a cytoskeletal filament stained with vimentin. The cell surfaces were positive for mesenchymal stem cell markers CD90 (Fig. 1b) and CD73 (Fig. 1c) and negative for markers of hematopoietic origin CD34 (Fig. 1d).



**Fig. 1.** DPSCs by indirect immunofluorescence (Rodamine). Immunofluorescence staining of vimentin (a), mesenchymal stem cell marker CD73 (b), CD90 (c), and hematopoietic markers CD34 (d). Nuclei were stained with DAPI. Original magnification  $\times 40$ .

The effect of calcium sulfate treatment on DPSCs was analyzed in quantitative real-time-PCR after 24 h and 4 days of treatment, respectively, and the expression levels of osteoblast-related genes, extracellular matrix, and inflammation pathways were measured. Table II reports the fold change obtained after 24 h and 4 days.

The analyzed genes are significantly upregulated if they show  $\geq 2$ -fold change in expression. In contrast, significantly downregulated genes show  $\leq 0.5$ -fold change in expression compared to the levels found in untreated cells. In DPSCs, after 24 h of treatment, SP7 was strongly up-regulated, as were MMP7 and IL6. Although with a less pronounced fold change, MMP12, MMP14, and IL1a were also upregulated. Of note, the expression level of FOSL1 increased the most after 4 days (Table II).

**Table II.** Expression profile analysis in DPSCs after 24 h and 4 days of treatment with calcium sulfate. Numbers express the fold-changes with respect to untreated cells. In bold, significant gene expression levels. Nd – not determined.

	24 h	4 days
<b>SPP1</b>	nd	nd
<b>SPARC</b>	0.49	0.27
<b>RUNX2</b>	0.56	0.84
<b>ALP</b>	0.22	0.03
<b>FOSL1</b>	1.65	<b>4.75</b>
<b>SP7</b>	<b>20.91</b>	0.24
<b>ENG</b>	0.83	0.73
<b>COL1A1</b>	0.34	0.25
<b>COL3A1</b>	0.6	0.2
<b>COL4A1</b>	0.4	0.5
<b>MMP7</b>	<b>5</b>	0.2
<b>MMP12</b>	<b>2.7</b>	0.3
<b>MMP14</b>	<b>2.7</b>	2
<b>IL1a</b>	<b>2.2</b>	0.2
<b>IL1R1</b>	0.8	1.7
<b>IL6</b>	<b>3.4</b>	1.5
<b>IL6R</b>	1.2	0.9

## DISCUSSION

Calcium sulfate serves as a bone graft substitute in orthopedic and dental surgery. Its porous structure and resorbable nature facilitate bone regeneration by providing a scaffold for new bone formation. Calcium sulfate implants gradually dissolve, releasing calcium and sulfate ions that promote osteogenesis and angiogenesis, ultimately replaced by new bone tissue. In dentistry, calcium sulfate-based materials are used in dental procedures for socket preservation, guided bone regeneration, and sinus augmentation. In periodontal surgery, calcium sulfate barriers prevent soft tissue ingrowth and promote bone regeneration around dental implants. Calcium sulfate pastes are also utilized in endodontic therapy for root canal disinfection and obturation.

Since bone regenerative activity is driven by mesenchymal stem cells, in this study, we wanted to evaluate the effect of calcium sulfate on DPSC after 24 hours and 4 days of treatment. Therefore, we analyzed the expression profile of genes involved in pathways related to osteoblast differentiation, extracellular matrix, and inflammation. Our results demonstrated that calcium sulfate acts on DPSCs, activating SP7 and MMP7, among other genes.

SP7, also known as Osterix, is an osteoblast-specific transcription factor, a downstream target of RUNX2. It is considered an up-regulator of late osteogenic markers and is required for bone formation and mineralization *in vivo* (11). Indeed, SP7 plays a master role in the maturation of osteoblasts from mesenchymal progenitors and their differentiation into osteocytes (12, 13). Interestingly, in our study, after 24 hours of treatment of DPSCs with calcium sulfate, almost 21-fold changes in SP7 overexpression were achieved.

Collectively, matrix metalloproteinases (MMPs) are capable of degradation of the entire extracellular matrix (ECM). Remodeling of bone tissue is ensured by osteoclasts, which actively degrade the bone matrix using a powerful array of proteinases, including MMPs. We found that three MMPs in our model were significantly overexpressed. Specifically, MMP7, also known as matrilysin-1, is a secreted zinc- and calcium-dependent endopeptidase, considered the smallest MMP enzyme; MMP12, also known as macrophage metalloelastase (MME); MMP14, also known as membrane-type 1 matrix metalloproteinase (MT1-MMP), a transmembrane protein.

MMP7 is considered to be a potent proteoglycanase. Its increased expression observed in osteocytes and collagen bundles of haversian canals during osseointegration has been suggested to reflect its role in maintaining matrix content and turnover and in solubilizing osteoid matrix (14). In our study, it was the second most upregulated gene among those analyzed.

Like other MMPs, MMP12 can degrade a wide range of ECM components, including type I/IV collagen, aggrecan, decorin, gelatin, elastin, fibronectin, laminin, vitronectin, entactin (14). Interestingly, intracellular MMP12 in macrophages has been observed to have antimicrobial activity (15). In addition to its antibacterial and antiviral properties, MMP12 has been implicated in regulating embryonic development, reproduction, tissue remodeling, wound healing, and repair (16-18). It is generally accepted that MMP12 is undetectable in adult tissues, which normally secrete negligible amounts. However, MMP12 expression has been documented in tissues undergoing rapid remodeling, such as the placenta at term during human fetal development, and in several tumor tissues (19, 20). The upregulation of MMP12 found in our treated DPSCs seems consistent with its activation during tissue remodeling, plausibly induced by calcium sulfate.

Emerging evidence suggests that MMP14 is critical in bone formation, influencing osteoblast differentiation, bone matrix remodeling, and skeletal development (21). MMP14 influences osteoblast function and bone formation through its effects on ECM remodeling, cell signaling, and cell-matrix interactions. During osteoblast differentiation, MMP14 facilitates the turnover of the bone matrix by cleaving collagen and other ECM components, promoting the release of bioactive factors that regulate osteoblast activity and mineralization. Additionally, MMP14 regulates osteoblast migration and invasion, facilitating their recruitment to bone formation and remodeling sites.

Moreover, MMP14 indirectly modulates osteoclast activity and bone resorption through its effects on other cell types and ECM remodeling. MMP14 expressed by osteoblasts and osteocytes promotes the release of soluble factors such as RANKL (Receptor Activator of Nuclear Factor Kappa-B Ligand) and osteopontin, which stimulate osteoclast formation and activity (22). MMP14 also interacts with cell signaling pathways involved in osteoclastogenesis and bone resorption, influencing the balance between bone formation and resorption (23).

IL-6 is a major pro-inflammatory cytokine. In bone tissue, at high levels, IL-6 can bind to receptors on osteoclasts, promoting catabolic bone metabolism and increasing the rate of bone resorption. However, an opposite effect of IL-6 on osteoclast differentiation has been described, leading to a reduction in osteoclastogenesis. This would, therefore, lead to less erosion of bone tissue (24).

It should be noted that among the genes analyzed in our study, the expression of FOSL1 reached a 4.75-fold overexpression after 4 days of treatment, not 24 hours. FOSL1, a member of the Fos family of transcription factors, plays

a significant role in various cellular processes, including proliferation, differentiation, and apoptosis. In recent years, FOSL1 has garnered attention for its involvement in bone biology, particularly in osteogenesis, the process of bone formation (25). FOSL1 belongs to the AP-1 (Activator Protein-1) family of transcription factors, characterized by a basic leucine zipper (bZIP) domain that mediates dimerization and DNA binding. It forms heterodimers with members of the Jun family, constituting the AP-1 transcription complex. FOSL1 activity is modulated by various signaling pathways, including the mitogen-activated protein kinase (MAPK) pathway, the Wnt/ $\beta$ -catenin pathway, and the BMP-Smad pathway, which regulate FOSL1 expression and activity during osteogenesis (26). FOSL1 is critical in osteogenesis, influencing osteoblast differentiation, bone matrix mineralization, and bone homeostasis. During the early stages of osteoblast differentiation, FOSL1 cooperates with other transcription factors such as RUNX2 and Osterix to activate the expression of osteogenic genes, including alkaline phosphatase (ALP), osteocalcin (OCN), and collagen type I (COL1A1). FOSL1 promotes osteoblast proliferation and survival, facilitating the expansion of the osteoblast progenitor pool and the formation of mature osteoblasts. Moreover, FOSL1 regulates bone matrix mineralization by modulating gene expression in extracellular matrix (ECM) synthesis and remodeling. FOSL1 promotes the expression of matrix metalloproteinases (MMPs) and other proteases that degrade ECM components, facilitating mineralized matrix deposition. Additionally, FOSL1 interacts with signaling pathways involved in calcium homeostasis and phosphate metabolism, influencing bone mineralization processes (27).

## CONCLUSIONS

Calcium sulfate-based materials are used in dental procedures for socket preservation, guided bone regeneration, and sinus augmentation. In periodontal surgery, calcium sulfate barriers prevent soft tissue ingrowth and promote bone regeneration around dental implants. Calcium sulfate pastes are also utilized in endodontic therapy for root canal disinfection and obturation. Calcium sulfate can activate several genes in mesenchymal stem cells, inducing osteoblast differentiation. Specifically, we have shown that 24-hour treatment of DPSCs with calcium sulfate induces more than 20-fold overexpression of SP7, a transcription factor with a master role in osteoblast differentiation and tissue mineralization. It is our knowledge, however, that more research is needed to elucidate the role of calcium sulfate on MSCs fully.

## REFERENCES

1. Kutkut A, Andreana S. Medical-grade calcium sulfate hemihydrate in clinical implant dentistry: a review. *J Long Term Eff Med Implants*. 2010;20(4):295-301. doi:<https://doi.org/10.1615/jlongtermeffmedimplants.v20.i4.40>
2. Yahav A, Kurtzman GM, Katzap M, Dudek D, Baranes D. Bone Regeneration: Properties and Clinical Applications of Biphasic Calcium Sulfate. *Dent Clin North Am*. 2020;64(2):453-472. doi:<https://doi.org/10.1016/j.cden.2019.12.006>
3. Thomas MV, Puleo DA. Calcium sulfate: Properties and clinical applications. *J Biomed Mater Res B Appl Biomater*. 2009;88(2):597-610. doi:<https://doi.org/10.1002/jbm.b.31269>
4. Tang YL, Yuan J, Song YL, Ma W, Chao X, Li DH. Ridge expansion alone or in combination with guided bone regeneration to facilitate implant placement in narrow alveolar ridges: a retrospective study. *Clin Oral Implants Res*. 2015;26(2):204-211. doi:10.1111/clr.12317
5. Naji A, Eitoku M, Favier B, Deschaseaux F, Rouas-Freiss N, Suganuma N. Biological functions of mesenchymal stem cells and clinical implications. *Cell Mol Life Sci*. 2019;76(17):3323-3348. doi:<https://doi.org/10.1007/s00018-019-03125-1>
6. Lauritano D, Avantiaggiato A, Candotto V, et al. Insulin Activity on Dental Pulp Stem Cell Differentiation: An in Vitro Study. *J Biol Regul Homeost Agents*. 2015;29(3 Suppl 1):48-53.
7. Lauritano D, Avantiaggiato A, Candotto V, et al. Effect of Somatostatin on Dental Pulp Stem Cells. *J Biol Regul Homeost Agents*. 2015;29(3 Suppl 1):54-58.
8. Arthur A, Gronthos S. Clinical Application of Bone Marrow Mesenchymal Stem/Stromal Cells to Repair Skeletal Tissue. *Int J Mol Sci*. 2020;21(24):doi:<https://doi.org/10.3390/ijms21249759>
9. Sui B, Wu D, Xiang L, Fu Y, Kou X, Shi S. Dental Pulp Stem Cells: From Discovery to Clinical Application. *J Endod*. 2020;46(9S):S46-S55. doi:<https://doi.org/10.1016/j.joen.2020.06.027>
10. Sollazzo V, Palmieri A, Girardi A, et al. Osteopontin acts on stem cells derived from peripheral blood. *J Indian Soc Periodontol*. 2010;14(1):12-17. doi:<https://doi.org/10.4103/0972-124X.65429>
11. Zhang C. Transcriptional regulation of bone formation by the osteoblast-specific transcription factor *Osx*. *J Orthop Surg Res*. 2010;5(37). doi:<https://doi.org/10.1186/1749-799X-5-37>
12. Nakashima K, Zhou X, Kunkel G, et al. The novel zinc finger-containing transcription factor *osterix* is required for osteoblast differentiation and bone formation. *Cell*. 2002;108(1):17-29. doi:[https://doi.org/10.1016/s0092-8674\(01\)00622-5](https://doi.org/10.1016/s0092-8674(01)00622-5)

13. Chan WCW, Tan Z, To MKT, Chan D. Regulation and Role of Transcription Factors in Osteogenesis. *Int J Mol Sci.* 2021;22(11):doi:https://doi.org/10.3390/ijms22115445
14. Shubayev VI, Branemark R, Steinauer J, Myers RR. Titanium implants induce expression of matrix metalloproteinases in bone during osseointegration. *J Rehabil Res Dev.* 2004;41(6A):757-766. doi:https://doi.org/10.1682/jrrd.2003.07.0107
15. Houghton AM, Hartzell WO, Robbins CS, Gomis-Ruth FX, Shapiro SD. Macrophage elastase kills bacteria within murine macrophages. *Nature.* 2009;460(7255):637-641. doi:https://doi.org/10.1038/nature08181
16. Marchant DJ, Bellac CL, Moraes TJ, et al. A new transcriptional role for matrix metalloproteinase-12 in antiviral immunity. *Nat Med.* 2014;20(5):493-502. doi:https://doi.org/10.1038/nm.3508
17. Hiden U, Eyth CP, Majali-Martinez A, et al. Expression of matrix metalloproteinase 12 is highly specific for non-proliferating invasive trophoblasts in the first trimester and temporally regulated by oxygen-dependent mechanisms including HIF-1A. *Histochem Cell Biol.* 2018;149(1):31-42. doi:https://doi.org/10.1007/s00418-017-1608-y
18. Chakraborty S, Sampath D, Yu Lin MO, et al. Agrin-Matrix Metalloproteinase-12 axis confers a mechanically competent microenvironment in skin wound healing. *Nat Commun.* 2021;12(1):6349. doi:https://doi.org/10.1038/s41467-021-26717-7
19. Kerkela E, Bohling T, Herva R, Uria JA, Saarialho-Kere U. Human macrophage metalloelastase (MMP-12) expression is induced in chondrocytes during fetal development and malignant transformation. *Bone.* 2001;29(5):487-493. doi:https://doi.org/10.1016/s8756-3282(01)00595-6
20. Kerkela E, Ala-aho R, Klemi P, et al. Metalloelastase (MMP-12) expression by tumour cells in squamous cell carcinoma of the vulva correlates with invasiveness, while that by macrophages predicts better outcome. *J Pathol.* 2002;198(2):258-269. doi:https://doi.org/10.1002/path.1198
21. Liang HPH, Xu J, Xue M, Jackson CJ. Matrix metalloproteinases in bone development and pathology: current knowledge and potential clinical utility. *Metalloproteinases In Medicine.* 2016;3(10). doi:https://doi.org/10.2147/MNM.S92187
22. Hikita A, Yana I, Wakeyama H, et al. Negative regulation of osteoclastogenesis by ectodomain shedding of receptor activator of NF-kappaB ligand. *J Biol Chem.* 2006;281(48):36846-36855. doi:https://doi.org/10.1074/jbc.M606656200
23. Bassiouni W, Ali MAM, Schulz R. Multifunctional intracellular matrix metalloproteinases: implications in disease. *FEBS J.* 2021;288(24):7162-7182. doi:https://doi.org/10.1111/febs.15701
24. Feng W, Liu H, Luo T, et al. Combination of IL-6 and sIL-6R differentially regulate varying levels of RANKL-induced osteoclastogenesis through NF-kappaB, ERK and JNK signaling pathways. *Sci Rep.* 2017;7(41411). doi:https://doi.org/10.1038/srep41411
25. Pecce V, Verrienti A, Fiscon G, et al. The role of FOSL1 in stem-like cell reprogramming processes. *Sci Rep.* 2021;11(1):14677. doi:https://doi.org/10.1038/s41598-021-94072-0
26. Lee BK, Uprety N, Jang YJ, et al. Fosl1 overexpression directly activates trophoblast-specific gene expression programs in embryonic stem cells. *Stem Cell Res.* 2018;26(95-102). doi:https://doi.org/10.1016/j.scr.2017.12.004
27. Chande S, Bergwitz C. Role of phosphate sensing in bone and mineral metabolism. *Nat Rev Endocrinol.* 2018;14(11):637-655. doi:10.1038/s41574-018-0076-3



Technical Note

## CONE TEST IN ENDODONTIC THERAPY: A TECHNICAL NOTE

C. Bugea<sup>1</sup>, A. Scarano<sup>1,2\*</sup>, G. Falisi<sup>3</sup>, F. Tricca<sup>1</sup>, I. Alla<sup>1</sup>, E. Ronca<sup>1</sup> and F. Lorusso<sup>1</sup>

<sup>1</sup>Department of Innovative Technologies in Medicine & Dentistry, University of Chieti-Pescara, Italy;

<sup>2</sup>Visiting professor, Department of Oral Implantology, Dental Research Division, College Ingá, UNINGÁ, Cachoeiro de Itapemirim, Espírito Santo, Brazil;

<sup>3</sup>Department of Life, Health and Environmental Sciences, University of L'Aquila, L'Aquila, Italy

\*Correspondence to:

Antonio Scarano, D.D.S., M.D.

Department of Innovative Technologies in Medicine & Dentistry,

University of Chieti-Pescara,

Via Dei Vestini 31,

66100 Chieti Italy

e-mail: ascarano@unich.it

**KEYWORDS:** *thermoplastic guttapercha injection, obturation technique, lateral canals*

### INTRODUCTION

The cone test is a necessary step in endodontic therapy. This is the connecting line between the conclusion of the shaping phase and the beginning of the root canal obturation phase. So, if this test gives good results, one can move on; alternatively, one must resume the previous phase. It's also necessary to know the quality and characteristics of the cone that will be used in the obturation. In this article, all the operations are listed, explained, and motivated individually, and all the necessary tips to complete them.

Test of the guttapercha cone is one of the essential steps to achieve a good three-dimensional obturation of the endodontic space. It is also a step to verify the accuracy of the previous steps. A good fit of the cone allows us to proceed immediately with the obturation of the canal. In contrast, if it is impossible to find a cone that fits the preparation made, it is good to consider the possibility that the shaping is inadequate and that it is necessary to improve it before making the root canal obturation (1, 2). This article aims to provide clinical suggestions to effectively and efficiently perform this phase of endodontic therapy.

### TECHNICAL NOTE

Trying and fitting the cone is an operation that requires a few tools: guttapercha cones, a dedicated gauge, a new scalpel blade, a pair of scissors, a tool to insert the guttapercha cones before obturation, and sodium hypochlorite (NaOCl).

Since knowing the materials being used and having a clear idea of their characteristics is essential for clinical practice, the properties of guttapercha will be summarized shortly. Guttapercha is universally recognized as the material of choice for the obturation of the root canal system.

Essentially, it is characterized by a low coefficient of thermal contraction/expansion, the possibility to be an electrical insulator, compressibility, and plasticity, good dimensional stability once solidified, biocompatibility, radiopacity, ability to be dissolved by appropriate solvents such as chloroform and possibility to be easily sterilized with NaOCl (3).

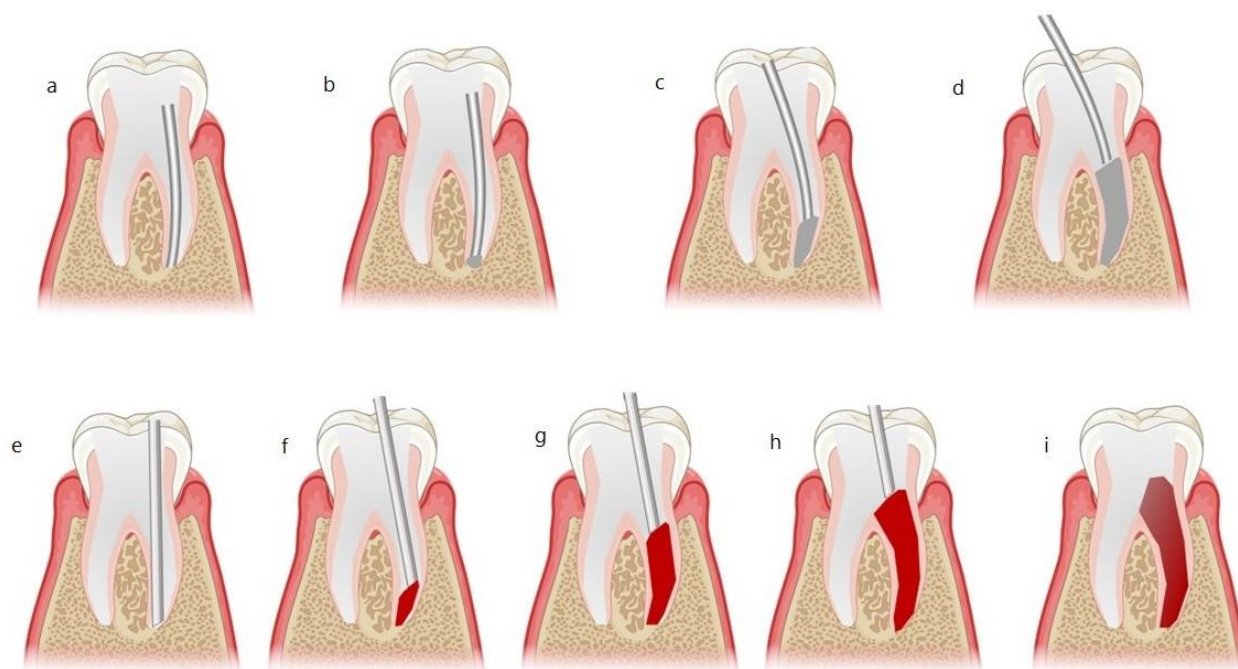
Received: 19 October 2021  
Accepted: 14 November 2021

Copyright © by LAB srl 2021 ISSN 2975-1276

This publication and/or article is for individual use only and may not be further reproduced without written permission from the copyright holder. Unauthorized reproduction may result in financial and other penalties. Disclosure: All authors report no conflicts of interest relevant to this article.

Guttapercha for dental use is not “pure” but is obtained by mixing isoprene (18.9-21.8%) with zinc-oxide (59.1-78.3%), heavy metal sulfate (2.5-17.3%), waxes and resins (1- 4.1%), dyes and antioxidants (3%), and fatty acids (traces) (4). Each brand of guttapercha differs from the others: changing the percentages above, cones with different radiopacity, softness, and color are obtained.

In general, the more complex the guttapercha cone, the more inextensible it is and the higher the percentage of zinc oxide inside it; on the other hand, the softer one, the more extensible it is and the higher the concentration of guttapercha. The mere pressure of a fingernail on the cone's surface will indicate its quality: the more definite the imprint, the higher the quality of the guttapercha. (Fig. 1). This aspect, clinically, will be reflected in greater compressibility and heat conduction capacity.



**Fig. 1.** *a): cone quality test; b): Three different cones with apical diameter 30; c): Ni-Ti instruments and dedicated cones; d): cones soaked in NaOCl in a Petri capsule; e): cone cutting defects; f): cone elongation: before and after; g): one folded on itself; h): twisted cone; i): Root canal reprocessing: after shaping, the walls are still soiled with endomethasone.*

Guttapercha cones are commercialized in standardized and non-standardized forms. According to ISO standards, standardized cones have tip diameters varying from 0.15 to 1.40 mm. They can have a 0.02, 0.04, or 0.06 taper and are generally used as master cones in lateral condensation or single-cone filling.

Non-standardized cones, on the other hand, are more tapered and sharper than the previous ones. They are available in nine sizes: X-fine, fine-fine, medium-fine, fine (0.06), fine-medium (0.08), medium (0.10), medium-large (0.12), large and extra-large; they can vary considerably depending on the manufacturer (5).

The cones preferred in warm compaction techniques are not standardized because they are better filled to shape produced with rotating Ni-Ti instruments. There are also cones dedicated to the different types of instruments that have a taper corresponding to the root canal instruments used for shaping the root canal; this type of cone can be challenging to use because if its taper is identical to that of the shaping, friction of the cone along the walls may impede its descent into the canal. In these cases, it is often preferable to choose the cone corresponding to the instrument of lower taper than the one brought to the working measurement.

The cone should fit the shape developed by the shaping; it is important to know the diameters and taper of the root canal instruments used for shaping, as this will make it easier to select the cone of the correct size. When testing the cone, it is good to remember the following decalogue:

1. the cone must be clean;
2. it must be cut well;
3. it must be longer than the channel;
4. it must go down inside the channel without bending;
5. it must not curl;

6. it must reach the end of the channel;
7. must have apical tug back;
8. must not be accessible in the canal;
9. cone insertion must be repeatable;
10. a radiographic test must be performed. The points will be analyzed one by one.

*The decalogue for the cone test*

1. The cone must be clean. It is a good idea to keep the guttapercha cones soaking in hypochlorite in a tool for guttapercha cone cleaning to make them as aseptic as possible: 60 seconds is sufficient to eradicate even *Bacillus subtilis* spores (6, 7).
2. The cone must be cut well. To make a precise cut, scalpels, micro-scissors, a proper cutting technique, and a zooming system must be used (4). This will help eliminate cutting defects that sometimes lead to a lack of tug back or incomplete descent of the cone within the canal (8).
3. The cone should be longer than the canal. In cases where the canals are exceptionally long, the test steps may be complex because of the cone size. Trying a 21-mm-long cone (e.g., a fine-medium cone with a diameter of 40) in a 22-long canal can be complex, especially when cutting the most apical portion or the adequacy of the tug back. In these cases, it is useful to heat a portion of a guttapercha cone and attach it to the head of the cone to be tested, resulting in a longer and very stable cone.
4. The cone should descend inside the canal without bending. In posterior areas, in patients with limited mouth openings, in difficult-to-access canals such as the mesial or mesiobuccally canal of upper molars, or in the presence of very coronal and large ledge (e.g., after removal of screw-retained posts), it may happen that the cone, before entering the canal, bumps against the floor or walls of the pulp chamber, folded on itself. When this happens, cutting or bending the cone in its coronal portion is advisable to obtain more space for a maneuver. Another solution may be to harden the guttapercha cones by soaking them for a few minutes in pure alcohol. If the cones break during this phase, the guttapercha cones may be damaged.
5. The cone should not twist. In some cases, the cone, before reaching the root apex, undergoes a compressive force that causes a twist: this frequently occurs in re-treatments, when the canals have been greatly widened in the coronal and middle portions, or complex anatomies marked by blockages ledges or sudden changes in direction; the same can also occur in the presence of an excessively reduced taper of the guttapercha cone.
  1. In these eventualities, the problem must be identified early and, if possible, resolved. Modifying the anatomy by re-preparing the canal is a viable option only when there is useful space for preparation.
  2. If the tooth has already been extensively prepared, on the other hand, rather than weakening an already fragile root, it is advisable to use a higher taper guttapercha cone. A step in alcohol, as previously described, may be helpful in case the cone bends (9).
6. The cone should reach the end of the canal and not exceed it. When this does not happen, there can be many causes: the apical diameter has not been understood, the canal is not well shaped, or the preparation does not reach the right length. In retreatments, intracanal obstructions (e.g., broken instrumentation) or inorganic material (e.g., guttapercha residues, pastes, and cement) can hinder cone advancement. The solution is to understand any shaping error, understand the apical diameters, and clean the canal well of the material; in the latter case, using ultrasound instruments or debrider is a valuable aid, especially if the procedure is done with an operating microscope.
7. The cone must have an apical tug back. The guttapercha cone will have friction against the canal walls, and it is necessary to be certain that this is in the apical, not coronal, part to have a three-dimensional filling and avoid overfilling or underfilling. To be sure of the above, it is useful to try a smaller taper and the same tip's diameter second cone and note its size: if the length of the two cones is identical, it is sure that the cone is frictional apically and not coronal. If, on the other hand, the lower taper cone has a longer length, it means that the apical diameter is not correct, and the apex should be remeasured. The smaller cone is more reliable in measuring apical diameter than the cone of greater taper (10, 11).
8. Friction of the cone along the canal walls causes the appearance of tiny visible striations on its surface: if the striations are in the apical third, they confirm tug back in this area.
9. The absence of tug back may be due to debris within the canal lumen, which prevents proper friction of the cone on the walls or less tapering of the cone compared to the preparation. To solve the problem, ultrasound instruments will be sufficient to clean the canal of organic tissue or increase the taper of the cone without changing the tip diameter.

10. The cone should not be free in the canal. Generally, cones have a taper similar to the instruments used for shaping; for this reason, a cone with a diameter corresponding to the apical diameter should be selected and never undersized compared to it. Moreover, the taper must be similar to the preparation, at least in the apical third. If this does not happen, portions of the cone in the canal will be free: having a free cone in the coronal portions of the canal is a problem that can be easily remedied during obturation; if, instead, this occurs at the apical level there will be absence of seal and overfilling.
11. The insertion of the cone must be repeatable. Whenever the guttapercha cone is inserted inside the canal, it must be repeatable, the length must be constant, and the same tug back must always be manifested. The cone containing sodium hypochlorite is inserted into the canal. During such tests, it is advisable to move the cone to activate the irrigants: this activation is not comparable to that obtained with ultrasound; however, it is an easy way to increase the effectiveness of sodium hypochlorite.
12. A radiographic test should be done. Taking an X-ray with the cones inserted provides an opportunity to evaluate some of the points above; it also allows us to verify the working lengths and the fit of the cone to the walls. If the radiograph confirms the selected cone is appropriate, root canal obturation can be initiated.

## CONCLUSIONS

Knowing the taper of the shaping, understanding the apical diameter of the canal, and performing good irrigation will speed up the steps described in the decalogue. A good root canal obturation depends on the correctness of the previous steps.

## REFERENCES

1. West JD. The cone fit: an essential step to creating exceptional endodontic obturation. *Dent Today*. 2005;24(5):102-105.
2. West J. The cone fit: an essential step to creating obturation excellence. *Endod Rep*. 1992;7(1):10-13.
3. Goodman A, Schilder H, Aldrich W. The thermomechanical properties of guttapercha. Part IV. A thermal profile of the warm guttapercha packing procedure. *Oral Surgery, Oral Medicine, Oral Pathology*. 1981;51(5):544-551. doi:[https://doi.org/10.1016/0030-4220\(81\)90017-7](https://doi.org/10.1016/0030-4220(81)90017-7)
4. Friedman CM, Sandrik JL, Heuer MA, Rapp GW. Composition and Mechanical Properties of Guttapercha Endodontic Points. *Journal of Dental Research*. 1975;54(5):921-925. doi:<https://doi.org/10.1177/00220345750540052901>
5. Moule AJ, Kellaway R, Glarkson R, et al. Variability Of Master Guttapercha Cones. *Australian Endodontic Journal*. 2002;28(1):38-43. doi:<https://doi.org/10.1111/j.1747-4477.2002.tb00365.x>
6. Seabra Pereira OL, Siqueira JF. Contamination of guttapercha and Resilon cones taken directly from the manufacturer. *Clinical Oral Investigations*. 2009;14(3):327-330. doi:<https://doi.org/10.1007/s00784-009-0295-z>
7. Siqueira JF, Silva, das M, Lopes HP, M. de Uzeda. Effectiveness of four chemical solutions in eliminating *Bacillus subtilis* spores on guttapercha cones. *Dental traumatology*. 1998;14(3):124-126. doi:<https://doi.org/10.1111/j.1600-9657.1998.tb00824.x>
8. LOPES H, SIQUEIRAJR J, ELIAS C. Scanning Electron Microscopic Investigation of the Surface of Guttapercha Cones after Cutting. *Journal of Endodontics*. 2000;26(7):418-420. doi:<https://doi.org/10.1097/00004770-200007000-00010>
9. Castellucci A. *Endodontics*. Il Tridente (Firenze); 2005.
10. Schilder H. Filling Root Canals in Three Dimensions. *Journal of Endodontics*. 2006;32(4):281-290. doi:<https://doi.org/10.1016/j.joen.2006.02.007>
11. Ruddle Cj. Three-dimensional obturation: the rationale and application of warm gutta percha with vertical condensation. In: *Cohen's Pathways of the Pulp*. Vol 43. Ed. St. Louis, MO: Mosby Yearbook; 1994:Chapter 9.

Technical note

# ZYGOMATIC IMPLANT WITH SELF-TAPPING APEX AND MACHINED BODY: A CLINICAL TRIAL THROUGH A STEREOLITHOGRAPHIC MODEL

A. Scarano<sup>†</sup>, F. Tricca<sup>†</sup>, R. Conte, I. Alla, C. Bugea<sup>††</sup> and S.R. Tari<sup>††</sup>

Department of Innovative Technologies in Medicine and Dentistry, University of Chieti–Pescara, Chieti, Italy

<sup>†</sup>These authors contributed equally as first authors

<sup>††</sup>These authors contributed equally as last authors

Correspondence to:

Antonio Scarano, DDS

Department of Innovative Technologies in Medicine and Dentistry,

University “G. D’Annunzio” of Chieti-Pescara,

Via dei Vestini, 31

66100 Chieti (CH), Italy

e-mail: ascarano@unich.it

## ABSTRACT

Zygomatic and pterygoid implants are used in cases of severe atrophy of the edentulous upper jaw. This trial uses the sinus slot technique and stereolithographic model to place a zygomatic implant with a self-tapping apex and machined body. A model was fabricated using 3D printing technology (SprintRay, Dental model). To allow implant placement, a replica of the entire maxilla and zygomatic bone was manufactured in actual scale model size. A shallow hole was made in the zygomatic bone using a marking bur to prepare for the osteotomy. Subsequently, a groove using a diamond cutter with a conical tip was inserted into the site previously in the zygomatic bone. If necessary, milling cutters could be used with medium- and fine-grit burs to smooth the sharp ends of the bone. A calibrated truncated cone drill was then used to complete the osteotomy by passing through the previously created slot (i.e., tunnel). Finally, the implant was placed after choosing the appropriate length. The proposed protocol simplifies using zygomatic implants in cases of severe maxillary atrophy.

**KEYWORDS:** *zygomatic implants, pterygoid implant, maxillary atrophy, fixed prosthesis, dental implant*

## INTRODUCTION

Severe maxillary atrophy is accompanied by impaired masticatory and phonetic function that makes rehabilitation with conventional techniques difficult(1). Many different approaches were used to increase hard and soft tissue reconstruction with autologous from intraoral and / or extraoral grafts, sometimes associated with Type I Le Fort osteotomies (2, 3). In this context, the use of zygomatic and pterygoid implants may represent a treatment option in situations where there is severe partial or total maxillary atrophy (4, 5). The first clinical study using a zygomatic implant was Brånemark et al. (7), who described a placement technique that involved the insertion of implants through the sinus intra route and guided insertion through the execution of a lateral trapdoor bone without lifting the Schneider membrane,

Received: 29 October 2021  
Accepted: 26 November 2021

Copyright © by LAB srl 2021 ISSN 2975-1276

This publication and/or article is for individual use only and may not be further reproduced without written permission from the copyright holder. Unauthorized reproduction may result in financial and other penalties. Disclosure: All authors report no conflicts of interest relevant to this article.

experiencing a high predictability of the procedure. This technique has been modified to preserve and lift the sinus membrane, contextual to the procedure (6, 7). To avoid sinus complications, Stella and Warner have proposed a zygomatic implant placement technique (sinus slot technique) variant, which does not require detachment of the Schneider membrane (8). Another technical variant was the proposed extrasinus approach, whose implant route is external to the maxillary sinus cavity. The literature suggests different geometries and implant designs to facilitate optimal fixture positioning and long-term maintenance of osseointegration of the placed implants.

This trial aimed to propose using an implant with a spiral self-tapping apex and a machined body that facilitated implant placement in a stereolithographic model. This trial used implants with spiral self-tapping apex and machined body implants (Isomed, Padova, Italy) (Fig. 1).

## MATERIALS AND METHODS

The implants used in this study are characterized by a self-tapping apex of 13 mm with surface treatment, while the remaining part is by a machined surface. The implant has an internal hexagonal connection that allows screwing a Multi-Unit Abutment (MUA) to allow prosthetic anchoring. After examination by three-dimensional X-ray (CBCT), a 3D printing of the atrophic jaws was done to simulate the surgery and confirm the previously planned implant length using 3D planning software (Isomed, Padova, Italy) (Fig. 2-4). CT/CBCT-derived models were fabricated using 3D printing technology (SprintRay, Dental model). To allow implant placement, a replica of the entire maxilla and zygomatic bone was manufactured in actual scale model size.

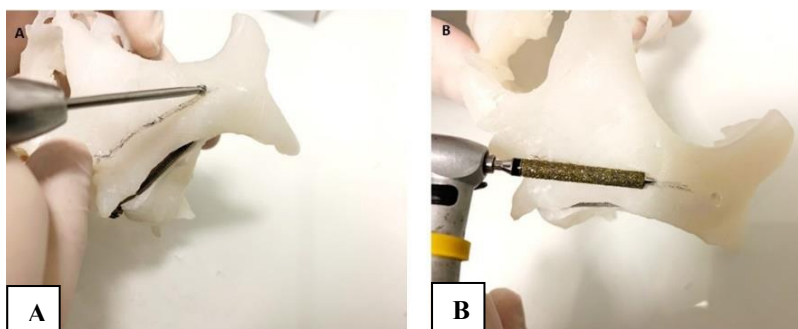
In clinical practice, an initial osteotomy was performed with a 5 mm round bur in the highest part of the bone ridge. A furrow in the crestal direction was performed with a second diamond bur with a machining tip (Fig. 2). The third bur perforated the cortical bone of the maxillary sinus and entered into the zygomatic bone for about 14 mm, impacting forwards at about 1 cm from the orbital cavity. The distance between the point of crestal bone and the apical point was measured with a probe based on the tomography measurement. The suitable length of the implant was confirmed, and it was screwed into the implant bed. The relationship between the alveolar crest and zygomatic

area influences the implant position, and the final preparation was performed with a calibrated bur of the predetermined length. The implant was inserted with an axis extending from the second premolar or canine from the highest point of the cheekbone, precisely in the corner formed by the frontal and temporal process. The point of entry was palatally in the premolar area.

During the placement, the implant leans against the maxillary sinus wall after a small detachment of Schneider's membrane. The implants present a geometric shape characterized by self-tapping threads that allow easy positioning and, above all, a high primary stability. This shape lets the implant slide along the osteotomy and engage in the zygomatic hole simply and predictably.

### Implant bed preparation

- 1) Using a marking bur, a shallow hole was made in the bone zygomatic bone in preparation for the osteotomy.
- 2) A groove was made extending from the first bur to the alveolar ridge using a diamond cutter with a conical tip. The tip was previously inserted into the site of the zygomatic bone. The coarse-grained cutter then created the groove. If necessary, milling cutters were used with medium- and fine-grit burs to smooth the sharp ends of the bone (Fig. 2-3).

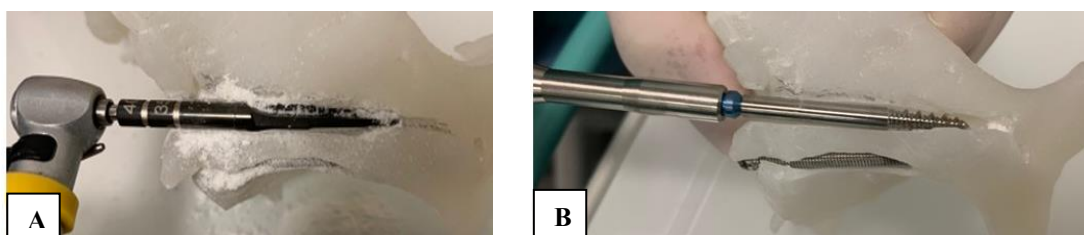


**Fig. 2.** 3D printing of the atrophic jaws. **A):** A bur is used to make an osteotomy at the superior extent of the contour of the zygomatic; **B):** A groove that extends from the first cut to the alveolar ridge using a diamond cutter with a conical tip. The conical tip must be inserted into the site previously in the zygomatic bone. The coarse-grained cutter was used to make the groove, and, if necessary, milling cutters is used with medium- and fine-grit burs to smooth the sharp ends of the bone.



**Fig. 3.** *A): medium-grit burs; B): fine-grit burs.*

3): A calibrated truncated cone drill was used to complete the osteotomy by passing through the previously created slot (i.e., tunnel) (Fig. 4A) and implant placement (appropriate length implant was chosen) (Fig. 4B).



**Fig. 4.** *A): A calibrated truncated cone drill was used to complete the osteotomy by passing through the previously created slot (i.e., tunnel); B): Zygomatic implant placement. Implants with a self-tapping apex of 13 mm with surface treatment, while the remaining part is by a machined surface.*

## RESULTS

All implants with spiral self-tapping apex and a machined body were inserted without any difficulty. The tunnel technique can be used to prepare a simple and secure implant site without involving the maxillary sinus. The simulation of the operation on 3D-printed upper jaw models before the zygomatic implant placement enables better predictability of clinical cases.

## DISCUSSION

In literature, five different surgical approaches were used for zygomatic implant placement: the classic approach (9), the sinus slot technique (8), the exteriorized approach (2), the minimally invasive approach by use of custom-made drill guides (10), and the computer-aided surgical navigation system approach (11).

In this trial, the implant is easily placed thanks to the tunnel technique described by Stella (8). The zygomatic implant proved to be an effective option in managing atrophic edentulous maxilla and defects in the maxillectomy.

This technique was introduced by Brånemark (7), for prosthetic rehabilitation of patients with significant defects of the jaw caused by tumor resection, trauma, and congenital defects. The zygomatic bone arc is used to anchor the implant, which, together with conventional implants, could be used as an anchor for the prosthesis and/or shutters. The technique allowed the successful rehabilitation of these patients, providing functional recovery and improved aesthetics, allowing for a normal social life and relationships. Many authors have suggested using multiple zygomatic implants (two or three on each side) to support a prosthesis.

The technique for atrophic patients, not subjected to maxillectomy, involves opening the maxillary sinus without lifting the sinus membrane to drive the cutter toward the zygomatic bone. Subsequently, several changes were made,

including lifting the membrane to preserve its integrity. The protocol, subsequently further modified, foresees the realization of a groove that extends from the zygomatic bone up to 5 mm from the alveolar crest sinus (slot technique) without lifting the sinus membrane (12). The surgical techniques for inserting the zygomatic implants are essentially two: an intrasinus technique and an extra-sinus procedure, and the approach depends upon the concavity or convexity that describes the outer wall of the maxillary sinus. The sinus morphology affects the passage or otherwise of the alveolar crest to anchor to the zygomatic bone (12).

Despite numerous publications with long-term positive results, there are no randomized controlled trials comparing the clinical efficacy of alternative means of rehabilitating patients with atrophic edentulous jaws. Retrospective studies document a percentage of implant survival rate of 90-100% (13). In addition, few prospective studies, especially long-term randomized clinical studies, confirm this technique's usefulness. No specific and well-defined criteria help the clinician evaluate rehabilitation success with zygomatic implants. After initial clinical use in patients with neoplastic disease, an indication of zygomatic implants has been expanded to fully edentulous patients with severe maxillary atrophy. Since then, the main indication for zygomatic implants remains unchanged. In the most common cases, zygomatic implants are combined with two or four anterior maxillary axial implants.

## CONCLUSIONS

Computed tomography is crucial for evaluating the zygomatic implant site, the sinus condition, and the implant path. With the original technique, the zygomatic implant path was within the maxillary sinus. The emergence of the head of the implant into the alveolar crest bone depends on the spatial zygomatic relationship with the maxillary sinus and the alveolar ridge dimension (14).

The use of this technique provides for the possibility of an extra-sinus implant path with promising results. This research used a zygomatic implant per side and 2 implants in the anterior maxilla. The results observed in the present study show the ease of implant placement with self-tapping apex, making it possible to center the hole in the zygomatic bone easily. Zygomatic implants represent an excellent alternative to regenerative surgery, taking advantage of the available bone anchored in the zygomatic region and native and non-regenerated bone, with obvious biomechanical advantages (15, 16).

## ACKNOWLEDGEMENTS

The authors acknowledge the helpful technical assistance of Dr. Mauro di Bernardino (radiology technician) for the elaboration of CBCT.

## REFERENCES

1. Wagner F, Dvorak G, Nemeč S, Pietschmann P, Figl M, Seemann R. A principal components analysis: how pneumatization and edentulism contribute to maxillary atrophy. *Oral Diseases*. 2016;23(1):55-61. doi:<https://doi.org/10.1111/odi.12571>
2. Migliorança RM, Coppedê A, Dias Rezende R, de Mayo T. Restoration of the edentulous maxilla using extrasinus zygomatic implants combined with anterior conventional implants: a retrospective study. *PubMed*. 2011;26(3):665-672.
3. Schlund M, Nicot R, Lauwers L, Raoul G, Ferri J. Le Fort 1 osteotomy and calvarial bone grafting for severely resorbed maxillae. *Journal of Cranio-Maxillofacial Surgery*. 2016;44(7):859-867. doi:<https://doi.org/10.1016/j.jcms.2016.04.015>
4. Araújo PPT, Sousa SA, Diniz VBS, Gomes PP, da Silva JSP, Germano AR. Evaluation of patients undergoing placement of zygomatic implants using sinus slot technique. *International Journal of Implant Dentistry*. 2016;2(1). doi:<https://doi.org/10.1186/s40729-015-0035-x>
5. Cucchi A, Vignudelli E, Franco S, Corinaldesi G. Minimally Invasive Approach Based on Pterygoid and Short Implants for Rehabilitation of an Extremely Atrophic Maxilla. *Implant Dentistry*. 2017;26(4):639-644. doi:<https://doi.org/10.1097/id.0000000000000603>
6. Aparicio C, Manresa C, Francisco K, et al. Zygomatic implants: indications, techniques and outcomes, and the Zygomatic Success Code. *Periodontology 2000*. 2014;66(1):41-58. doi:<https://doi.org/10.1111/prd.12038>
7. Boyes-Varley JG, Howes DG, Lownie JF, Blackbeard GA. Surgical modifications to the Brånemark zygomaticus protocol in the treatment of the severely resorbed maxilla: a clinical report. *PubMed*. 2003;18(2):232-237.
8. John Paul Stella, Warner MR. Sinus slot technique for simplification and improved orientation of zygomaticus dental implants: a technical note. *Int J Oral Maxillofac Implants*. 2001;15(6):889-893.
9. Becktor JP, Isaksson S, Abrahamsson P, Sennerby L. Evaluation of 31 Zygomatic Implants and 74 Regular Dental



- Implants Used in 16 Patients for Prosthetic Reconstruction of the Atrophic Maxilla with Cross-Arch Fixed Bridges. *Clinical Implant Dentistry and Related Research*. 2005;7(3):159-165. doi:<https://doi.org/10.1111/j.1708-8208.2005.tb00060.x>
10. Van Steenberghe D, Malevez C, Van Cleynenbreugel J, et al. Accuracy of drilling guides for transfer from three-dimensional CT-based planning to placement of zygoma implants in human cadavers. *Clinical Oral Implants Research*. 2003;14(1):131-136. doi:<https://doi.org/10.1034/j.1600-0501.2003.140118.x>
  11. Ewers R, Schicho K, Undt G, et al. Basic research and 12 years of clinical experience in computer-assisted navigation technology: a review. *International Journal of Oral and Maxillofacial Surgery*. 2005;34(1):1-8. doi:<https://doi.org/10.1016/j.ijom.2004.03.018>
  12. Aparicio C. A proposed classification for zygomatic implant patient based on the zygoma anatomy guided approach (ZAGA): a cross-sectional survey. *European journal of oral implantology*. 2011;4(3):269-275.
  13. Malevez C, Abarca M, Durdu F, Daelemans P. Clinical outcome of 103 consecutive zygomatic implants: a 6-48 months follow-up study. *Clinical Oral Implants Research*. 2004;15(1):18-22. doi:<https://doi.org/10.1046/j.1600-0501.2003.00985.x>
  14. Scarano A, Conte R, G Murmura, Lorusso F, Harrath AH. Satisfaction grade assessment of patients treated with zygomatic implants with self-tapping apex and machined body. *J Biol Regul Homeost Agents*. 2019;33(5):1651-1656. doi:<https://doi.org/10.23812/19-9239-1>
  15. Scarano A, Pecora G, Piattelli M, Piattelli A. Osseointegration in a Sinus Augmented With Bovine Porous Bone Mineral: Histological Results in an Implant Retrieved 4 Years After Insertion. A Case Report. *Journal of Periodontology*. 2004;75(8):1161-1166. doi:<https://doi.org/10.1902/jop.2004.75.8.1161>
  16. Scarano A, Degidi M, Iezzi G, et al. Maxillary Sinus Augmentation With Different Biomaterials: A Comparative Histologic and Histomorphometric Study in Man. *Implant Dentistry*. 2006;15(2):197-207. doi:<https://doi.org/10.1097/01.id.0000220120.54308.f3>

Letter to the Editor

# THE EVOLUTION OF BIOLOGICAL AGENTS FOR TERRORISTIC PURPOSES. A NARRATIVE HISTORICAL REVIEW

A.M. Inchingolo<sup>\*1†</sup>, A.D. Inchingolo<sup>1†</sup>, L. Bottalico<sup>2</sup>, L. Santacroce<sup>1</sup>, S. Topi<sup>3</sup>, K. Haxhirexha<sup>4</sup>, A. Scarano<sup>5</sup>, F. Lorusso<sup>5</sup>, G. Malcangi<sup>1</sup>, F. Inchingolo<sup>1</sup>, R. Gagliano-Candela<sup>6</sup>, B. Rapone<sup>1‡</sup>, G. Dipalma<sup>1‡</sup> and I.A. Charitos<sup>2‡</sup>

<sup>1</sup>Department of Interdisciplinary Medicine, Microbiology and Virology Unit, University of Bari School of Medicine, Bari, Italy;

<sup>2</sup>Interdepartmental Research Center for Pre-Latin, Latin and Oriental Rights and Culture Studies (CEDICLO), University of Bari, Bari, Italy;

<sup>3</sup>Department of Clinical Disciplines, School of Technical Medical Sciences, University of Elbasan "A. Xhuvani", Elbasan, Albania;

<sup>4</sup>Department of General Surgery, Medical Faculty, University of Tetovo, Tetovo, North Macedonia;

<sup>5</sup>Department of Innovative Technologies in Medicine & Dentistry and CAST, University of Chieti-Pescara, Chieti, Italy;

<sup>6</sup>Department of Interdisciplinary Medicine, Section of Forensic Toxicology, University of Bari, School of Medicine, Bari, Italy;

†These authors equally contributed to this work as co-first authors.

‡These authors equally contributed to this work as co-last authors.

*\*Corresponding author:*

A.M. Inchingolo, DDS  
Interdisciplinary Department of Medicine,  
University of Bari "Aldo Moro",  
Bari, Italy  
e-mail: [angeloinchingolo@gmail.com](mailto:angeloinchingolo@gmail.com)

## ABSTRACT

A terrorist action can take place with traditional weapons and/or with weapons of mass destruction. According to the United Nations Office on Drugs and Crime, it can be divided into conventional and non-conventional weapons; the present investigation aimed to evaluate through a literature overview the evolution of biological agents for terroristic purposes. Conventional weapons are the common firearms such as pistols (semiautomatic, revolvers), light submachine guns, small artillery (machine guns, small mortars, portable missile launchers, mines), and heavy artillery weapons (machine guns of larger caliber, mortars, missiles). The narrative review focused on non-conventional weapons since their effects extend to large quantities of people, over a large territory, and for a prolonged period, also called "weapons of mass destruction", and as such, are subject to complex, restrictive political agreements. The non-conventional weapons include several types of weapons, including nuclear weapons, biological weapons, chemical weapons, and radiogenic weapons. However, terrorism has ancient roots, and the term terrorism was used for the first time during the French Revolution. Many changes over time have occurred, both in the evolution of development and the non-legalized use of the aggressive agents that today are identified with the acronym N.B.C. (Nuclear, Biological, and Chemical).

Received: 12 November 2021  
Accepted: 10 December 2021

Copyright © by LAB srl 2021 ISSN 2975-1276

This publication and/or article is for individual use only and may not be further reproduced without written permission from the copyright holder. Unauthorized reproduction may result in financial and other penalties. Disclosure: All authors report no conflicts of interest relevant to this article.

**KEYWORDS:** *non-conventional weapons, terrorism, biowarfare, biological agent*

## INTRODUCTION

Countering the development and production of weapons of mass destruction is, therefore, impossible without states devoting more economic resources to organizational activities and studies in this area. For an effective response against biological attacks, for example, it is necessary to equip the leading hospitals with large quantities of antibacterial drugs and adequate facilities for the treatment of infected and intoxicated people, as well as tools to guarantee prompt investigations into the causes and mechanisms of spread of epidemics (1, 2).

Biological warfare, more commonly known as bacteriological warfare, has ancient origins. The Romans used the dead animals to pollute the water reserves of the besieged enemies and the Tartars; in 1347, during the siege of the Crimean city of Kaffa, the garrison of the Genoese Republic in the Black Sea catapulted corpses of plague victims into the city. Carried by the ships of the fleeing Genoese, the disease landed in Europe, where, in the Middle Ages, it killed over twenty million people in three years. The war of infections continued over the centuries, from the period of colonization (infected smallpox blankets donated to the Indians of Canada or syphilis prostitutes sent to the Maori of New Zealand) until the Second World War, with the Japanese flooding Manchuria with plague, cholera, and leptospirosis. The risk that biological war could entail, above all for the uncontrollable effects that derive from it, had led the first group of countries, including Italy, to sign a "non-use treaty" in Geneva (3) which entered into force on February 8, 1928 and was subsequently signed by over 120 states. These include Iran (1929), Iraq (1930), Pakistan (1960), Syria (1968), the United States (1975) and Afghanistan (1986) (1, 4, 5). However, the 1928 Geneva Protocol did not put any effective control on the acceding States. Even the subsequent Convention on Biological and Toxic Weapons of 1972 (6), which prohibits their development, production, acquisition, storage, and possession, does not contemplate verification procedures, a loophole that allowed many States to continue biological warfare programs for another twenty years (3, 5-13).

### *Features of biological agents*

Biological weapons are more devastating than the atomic bomb because they can cause pandemic diseases. The production of biological weapons is highly accessible without the need for investments and specific technologies, nor do you need any factories and plants; even simple research labs can be quickly converted. Some studies have calculated that hitting a square kilometer of territory would cost 800 USD with nuclear weapons, 600 USD with chemical agents, but only 1 USD with biological agents. A laboratory to produce viruses, bacteria, or any other infectious agent is easily dissimulated: the equipment needed for production is generally on sale and identical to any analysis laboratory. The "raw materials" are readily available from universities, pharmaceutical companies, and research centers. This is why the risk that bacteriological attacks can be carried out in a moment of extremely high tension is particularly topical (1, 14).

Biological weapons are bacteria, viruses, and toxins that cause disease, usually fatal, and are used to affect the military and civilian population. Even the diffusion method is within reach and difficult to predict: each system used has uncontrollable effects. Depending on the type of infection, people are infected and die within hours on most days. Those who are contaminated, in turn, become infectious, spreading the epidemic in continuous progression. Toxins are generally more lethal and faster acting, capable of causing death in a matter of hours, if not minutes. Viruses and bacteria require an incubation period of one day to six weeks before symptoms appear. The reason for the terror induced in the Western world is because, silent and invisible until the moment of use, they produce particularly insidious and difficult-to-recognize symptoms, easily confused with an epidemic of flu. There is a wide variety of possible infectious agents: bacterial agents (carbuncle, lung plague, epidemics among animals), viral agents (smallpox, yellow fever, equine encephalitis, flu), toxins (botulinum, mycotoxins) (1, 15).

The products used are obtained with modifications that make them resistant to the action of known antibiotics, at least until the agent causing the infection has been precisely identified, and the antidote or therapy and other has been found (16). For this, it can take many days, not counting the time necessary to isolate all potentially infected people, immunize them, and wait for the epidemic to disappear. For some of these infections, there is a vaccine, which, however, cannot be imposed on an entire country without creating collective panic, especially if we consider that protective drugs do not provide total immunity, often cause side effects of a certain magnitude and of course, each of them is effective only against one of the dozens of germs that can be used in an attack (Table I) (17).

**Table I.** *Biological agents doses, incubation time, and availability of vaccines.*

Agent	Infective dose	Incubation period (days)	Vaccine
Anthrax	8.000-50.000 spores	1-5	Available
Brucellosis	10-100 organisms	5-60 (sometimes months)	Not available
Plague	100-500 organisms	2-3	Available but ineffective
Q fever	1-10 organisms	10-40	Under study
Tularemia	10-50 organisms	2-10	Under study
Smallpox	10-100 organisms	7-17	Available
Viral encephalitis	10-100 organisms	2-6 (encephalitis equine Venezuelan) 7-14 (Western and Eastern equine encephalitis)	Under study
Viral hemorrhagic fever	1-10 organisms	4-21	Under study
Botulinum toxin	0,001 µg/kg (type A)	1-5	Under study
Staphylococcal enterotoxins	30 ng (debilitating) 1,7 ng (lethal)	1-6 ore	Not available

Finally, for the defense against genetically modified organisms, which are particularly resistant, there are neither protections nor cures nor is there experience of their infectivity. Much information on the spreading of diseases caused by bacteriological weapons comes from accidents or experiments on the unsuspecting population. For example, in 1979, an accidental release of the carbuncle bacillus from the Soviet plant in Sverdlovsk provided many valuable indications of the toxicity of the bacterium. The most Viruses used for war or terrorist purposes and their families are reported in Table II (1, 14).

**Table II.** *Viruses used for war or terrorist purposes.*

- **Filoviridae** (Ebola and Marburg haemorrhagic fevers virus)
- **Arenaviridae** (Lassa hemorrhagic fever virus; Junin; Machupo)
- **Bunyaviridae** (Congo-Crimea Hemorrhagic Fever Virus)
- **Flaviviridae** (yellow fever virus)
- **Togaviridae** (Venezuelan Encephalitis Alphavirus; eastern equine, western equine)

The spread can occur by air of infected vectors (mosquitoes, ticks) or contamination of materials and objects of everyday use. In general, these viruses are not very resistant to the external environment, whose cycle in nature is maintained by vectors or infection tanks. They are still not identified in the case of Filoviruses. The incubation period depends on the agent involved: 2-21 days for Ebolavirus; 3-9 days for Marburg virus; 7-21 days for Virus Lassa; 7-16 days for Junin and Machupo viruses (Argentine and Bolivian hemorrhagic fevers); 5-15 days for Alphavirus. In forms transmissible by human infection, the patient is contagious if the virus is present in the blood for several months starting from the pre-clinical period.

The clinical features of viral hemorrhagic fevers and viral encephalitis are, at least at the beginning, remarkably similar, non-specific, and flu-like: fever, general malaise, prostration, and bone and joint pain. Within 1-4 days, symptoms that point towards a definitive diagnosis (exanthema, hemorrhagic manifestations, or neurological signs) appear. Lethality is varied: 50-90% for Ebolavirus, 25% for Marburg virus; 15-60% for Virus Lassa; 5-30% for Argentine and Bolivian hemorrhagic fevers; 5-15% for Eastern equine encephalitis, 5-80% for Western equine encephalitis; 2-50% for Congo-Crimea haemorrhagic fever; 20-50% for yellow fever (in jaundiced forms) (1, 17, 18).

*Variola major (smallpox)*

It is a DNA virus, pathogenic only for humans, and highly diffusible. Before the eradication of the disease (WHO declaration in 1980), it was responsible for extremely high morbidity and mortality, with an attack rate between unvaccinated populations of about 50%. The possible diffusion can occur by dissemination by aircraft, with the formation of colorless, odorless, and invisible aerosols for contamination of materials and objects of everyday use and of different nature (e.g., paper, fabrics, leathers, objects of everyday use, etc.) The incubation period is from 7 to 17 days, usually 10-14 days; commonly, 10-12 days for the first symptoms to appear, then another 2-4 days for the rash to appear. The period of contagiousness begins from the appearance of the first lesions to the fall of all the crusts; the contagiousness is most significant in the first week of illness due to the high concentration of viruses in saliva. At the onset, the symptoms are nonspecific flu-like: fever, general malaise, prostration, bone, and joint pain, which is followed by an eruption that affects mucous membranes and skin within 2-4 days, with progression in subsequent stages of macules, papules, pustules, crusts and with the possibility of successive waves. The lethality of the greater smallpox is 20-40%; smallpox, or alastrim, caused by the variola minor virus (similar clinical form but more attenuated and benign course) is less than 1% (17).

*Bacillus anthracis*

The *Bacillus anthracis* is a gram-positive bacterium that forms spores that contain the DNA of the microorganism in the event of adverse environmental changes for life. Very resistant to heat, radiation, and extreme pH; when the environmental conditions are favorable again, the spores become living bacteria. It is a disease that has existed for hundreds of years and still affects both animals and humans in many parts of the world today, including Asia, southern Europe, sub-Saharan Africa, and parts of Australia. In its most common natural form, it creates dark wounds on the skin, from which the name derives: anthrax in Greek means coal.

If the spores are inhaled, they penetrate into the lungs, where they multiply rapidly, producing toxins that spread throughout the body through the blood vessels. A billionth of a gram can cause the death of a person. There are three types of anthrax, each has different symptoms (1, 17):

- a) Cutaneous or skin carbuncle is the most common form. Usually, it contracts when a person has a wound or abrasion on the skin and comes into direct contact with the anthrax spores. The resulting itchy skin swelling quickly develops into a black wound. Within 2-6 days, the skin lesion passes from the papule state to that of a necrotic eschar. Some people manifest symptoms such as headache, muscle pain, fever, and vomiting. Cutaneous anthrax must be treated quickly.
- b) Gastrointestinal carbuncle transmitted by eating meat from infected animals. Initially, it causes symptoms similar to those found in food poisoning, but these can worsen, causing severe abdominal pain, vomiting of blood, and severe diarrhea.
- c) The lung carbuncle is the most severe form of human anthrax, and although it is the rarest form, it is the one that is now causing the most concerns. This form of disease occurs when a person is directly exposed to large quantities of anthrax spores in the air, breathing them. Lethality varies according to the forms and fluctuates, in untreated cases, from 5% to 90%.

*Yersinia pestis (plague)*

Gram-negative germ, non-sporogenic, aerobic, optionally anaerobic, sensitive to the action of common chemical and physical disinfectants; in nature, the infection cycle is maintained by reservoirs (rodents) and vectors (fleas). Diffusion can occur by disseminating bacilli of the plague by aerosol, contamination of materials and objects of everyday use (indirect transmission), and introduction of infected vectors and tanks. It can be manifested as bubonic form (from puncture of infected fleas), lung form (from inhalation of aerosols containing secretions from sick people), or septicemic form (as such or as a complication of bubonic or pulmonary forms). Fleas (disease carriers) remain infected for months in favorable conditions; the spread of the lung form is favored in crowded environments.

The incubation period ranges from 1 to 7 days (can be slightly longer in vaccinated people); in primary lung plague, it is shorter (2 to 4 days). Using *Yersinia pestis* as a biological weapon, disseminated using aerosol, the first cases of lung plague could appear within 2 days (17, 19).

*Clostridium botulinum (botulism)*

*Sporogenous bacillus* gram-positive, anaerobic, produces botulinum toxin; 7 antigenic types of botulinum toxin are known (A, B, C, D, E, F, G). Diffusion can occur by contamination of food or by dispersion as an aerosol. The contamination of water resources seems more problematic due to the need for vast quantities of toxin and the inactivation

of this with standard treatments for drinking water (are sufficient for 3-6 days). The spores of *Clostridium botulinum* produced in conditions of absence of oxygen can resist up to 3-5 hours at a temperature of 100°C while at temperatures of 121°C, they are destroyed after 180 seconds; heat resistance is decreased in an acid environment, and the presence of high salt and sugar concentrations. The botulinum toxin is thermolabile and is destroyed by exposure to temperatures above 80 ° C for at least 10 min.

The neurological symptoms of intoxication appear in usually 12-36 hours after ingestion, but it can reach 8 days: the duration of the incubation period is dose-dependent; the prognosis is all the more serious, the shorter the incubation; lethality in the absence of treatment can reach 70-80%. In the case of inhalation, the symptoms appear after 12 hours. It is not transmissible from person to person (1, 17).

## CONCLUSIONS

From antiquity to date, we have known about several local and international conflicts. Usually, the soldiers and the armies must fight single battles and wars directly facing the enemies. Still, army officials and politicians always ask their national scientists to search for special weapons that should be invisible, effective, and highly destructive. Several weapons have been developed, sometimes adapting existing substances or creating instruments that subsequently have had peaceful and civilian applications (i.e., biological agents).

## REFERENCES

1. Riedel S. Biological Warfare and Bioterrorism: A Historical Review. *Baylor University Medical Center Proceedings*. 2004;17(4):400-406. doi:<https://doi.org/10.1080/08998280.2004.11928002>
2. Smithson AE, Levy LA. Ataxia: Chemical and Biological Terrorism Threat and the U.S. Response | Office of Justice Programs. [www.ojp.gov](http://www.ojp.gov). Published October 2000. <https://www.ojp.gov/ncjrs/virtual-library/abstracts/ataxia-chemical-and-biological-terrorism-threat-and-us-response>
3. United Nations Office for Disarmament Affairs. 1925 Geneva Protocol – UNODA. United Nations. Published 1925. <https://disarmament.unoda.org/wmd/bio/1925-geneva-protocol/>
4. Santacroce L, Bottalico L, Charitos IA. The Impact of COVID-19 on Italy: A Lesson for the Future. *The International Journal of Occupational and Environmental Medicine*. 2020;11(3):151-152. doi:<https://doi.org/10.34172/ijocem.2020.1984>
5. Santacroce L, Bottalico L, Topi S, Castellaneta F, Charitos IA. The “Scourge of the Renaissance”. A short review about *Treponema pallidum* infection. *Endocrine, Metabolic & Immune Disorders - Drug Targets*. 2019;19(3). doi:<https://doi.org/10.2174/1871530319666191009144217>
6. Tuzmukhamedov B. Convention on the Prohibition of the Development, Production and Stockpiling of Bacteriological (Biological) and Toxin Weapons and on their Destruction - Main Page. [legal.un.org](http://legal.un.org). Published April 10, 1972. <https://legal.un.org/avl/ha/cpdpsbttwd/cpdpsbttwd.html>
7. Pham VH, Isacco CG, Nguyen KT, et al. Rapid and sensitive diagnostic procedure for multiple detection of pandemic Coronaviridae family members SARS-CoV-2, SARS-CoV, MERS-CoV and HCoV: a translational research and cooperation between the Phan Chau Trinh University in Vietnam and University of Bari “Aldo Moro” in Italy.. *Eur Rev Med Pharmacol Sci*. 2020;24(12):7173-7191. doi:[https://doi.org/10.26355/eurev\\_202006\\_21713](https://doi.org/10.26355/eurev_202006_21713)
8. Goldwat J. The Biological Weapons Convention an Overview 1997.
9. United Nations. Convention on the prohibition of the development, production and stockpiling of bacteriological (biological) and toxin weapons and on their destruction 1972.
10. Gronvall GK. Prevention of the Development or Use of Biological Weapons. *Health Secur*. 2017;15(1):36-37. doi:10.1089/hs.2016.0096
11. Smithson AE. International cooperation to prevent biological weapons research and development. *Public Health Rep*. 2001;116 Suppl 2(Suppl 2):23-26. doi:10.1093/phr/116.S2.23
12. Roffey R, Lantorp K, Tegnell A, Elgh F. Biological weapons and bioterrorism preparedness: importance of public-health awareness and international cooperation. *Clin Microbiol Infect*. 2002;8(8):522-528. doi:10.1046/j.1469-0691.2002.00497.x
13. Thinus G, Werner A, Wallyn S, et al. Increased cooperation needed between law enforcement and public health to prepare for a bioterrorist attack. *Euro Surveill*. 2005;10(4):E050414.3. Published 2005 Apr 14. doi:10.2807/esw.10.15.02683-en
14. Santoianni F. L'ultima epidemia. La guerra batteriologica: dalla peste all'AIDS? ECP - Edizioni Cultura della Pace 1990..
15. Di Serio F, Lovero R, D'Agostino D, et al. Evaluation of procalcitonin, vitamin d and c-reactive protein levels in septic patients with positive emocultures. Our preliminary experience. *Acta medica Mediterranea/Acta medica mediterranea*. 2016;32:1911-1914. doi:[https://doi.org/10.19193/0393-6384\\_2016\\_6\\_182](https://doi.org/10.19193/0393-6384_2016_6_182)
16. Santacroce L, Charitos IA, Bottalico L. A successful history: probiotics and their potential as antimicrobials. *Expert*

- 
- Review of Anti-infective Therapy*. 2019;17(8):635-645. doi:<https://doi.org/10.1080/14787210.2019.1645597>
17. Bennett. Dolin. Blaser. Mandell, Douglas, And Bennett's Principles And Practice Of Infectious Diseases: 2-Volume Set. 9th ed. *Elsevier*; 2020.
  18. Meima M, Kuijpers E, van den Berg C, Kruizinga A. Biological agents and prevention of work-related diseases: a review 0 European Agency for Safety and Health at Work -EU-OSHA Biological agents and prevention of work-related diseases: a review European Risk *Observatory Report European Agency for Safety and Health at Work*. Published online 2020. doi:<https://doi.org/10.2802/403960>
  19. Corsalini M, Inchingolo F, Dipalma G, et al. Botulinum Neurotoxins (BoNTs) and Their Biological, Pharmacological, and Toxicological Issues: A Scoping Review. *Applied Sciences*. 2021;11(19):8849. doi:<https://doi.org/10.3390/app11198849>