

Journal of Orthopedics

Volume 6, Number 3, September – December 2014

CONTENTS

Editorial

P. Conti, T.C. Theoharides and G. Cerulli. Impact of cytokines on bone homeostasis..... 93

Case Reports

B. Chan, A. Anand, W. Liu, T. Yang, R. Chang, X. Cheng and W. Song. Therapy with adefovir dipivoxil in patients with chronic hepatitis B may cause pathological calcaneal occult fractures..... 99

N. Sunku and M. Pai. Unstable irreducible femoral neck fracture in children treated by closed reduction and internal fixation with joystick technique..... 107

Letter to the Editor

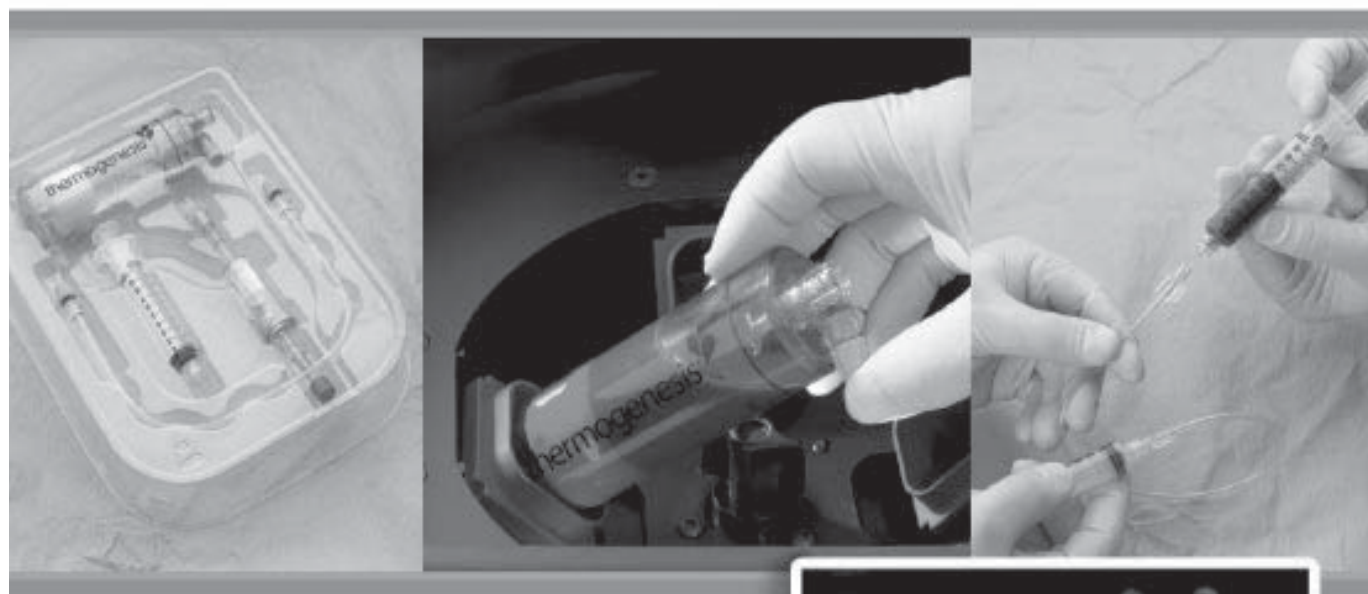A. Ziranu, P. F. Manicone, A. Sgambato, L. Raffaelli, S. Careri, F. Mariotti and G. Maccauro. Biocompatibility of some ceramic materials for clinical applications..... 111

Biological Study


P. Ruggeri, G. Marolda, A. Ianni and N. Franceschini. Protease activities in synovial fluids from patients suffering from pigmented villonodular synovitis: could nimesulide therapy reduce matrix metalloproteinase activation?..... 121

Dall' **esperienza** e dalla **collaborazione**
con l'Istituto Ortopedico Rizzoli

IOR-G1



Kit per la
**rigenerazione
osteocondrale**



EDITORIAL

IMPACT OF CYTOKINES ON BONE HOMEOSTASIS

P. CONTI¹, T.C. THEOHARIDES² and G. CERULLI³

¹*Immunology Division, Medical School, University of Chieti-Pescara, Italy;* ²*Department of Molecular Immunopharmacology and Drug Discovery Laboratory, Department of Internal Medicine, and Biochemistry, Tufts University School of Medicine and Tufts Medical Center, Boston, MA, USA;* ³*Institute of Clinical Orthopedics and Traumatology, Sacred Heart Catholic University, Rome, Italy*

Received May 21, 2014 - Accepted August 5, 2014

Cytokines are involved in the regulation of the immune system and clearly communicate with immune cells and bone cells. Therefore, cytokines are produced by many different cell types and are potent mediators of osteoclast function and differentiation. Pro-inflammatory cytokines have been shown to promote bone erosion in inflammatory diseases such as osteoporosis, rheumatoid arthritis, periodontitis, etc. Inflammatory cytokines act on osteoclasts leading to exacerbation of the inflammatory state. Cytokines such as IL-1, TNF, IL-6, TGF- β , IL-2, IL-8, M-CSF, IL-12, IL-18 and IFN- γ , and anti-inflammatory cytokines such as IL-4 and IL-10, are deeply involved in osteoclast generation and bone resorption. The immune system and bone cells require positive and negative regulators to maintain homeostasis. In this article, we discuss the interactions between cytokines and bone cells in maintaining homeostasis of the bone. However, the relationship between intercellular signalling, osteoprogenitor cells, mature osteoblasts, osteocytes and osteoclasts, in regulating the pathophysiology of the bone, still remains to be elucidated. Editorial.

Many cells including leukocytes generate glycoproteins, termed cytokines, that serve as chemical communicators from one cell to another. Cytokines commonly referred as “biological response modifiers” are soluble factors, large and heterogeneous group, that bind to cell surface receptors, exercising diverse functions. Most of the more recently discovered cytokines have been classified as interleukins and numbered in the order of their discovery. Cytokines are secreted from cells to elicit their effects in an autocrine and paracrine manner, but also they can act in an “intracrine,” non-secreted manner as nuclear factors. These proteins

act in an intracrine manner entering in the nucleus regulating gene transcription (1). Cytokines regulate intercellular communication by binding to specific cell-surface receptors and play an important and essential role in the control of the innate and adaptive immune responses (2-3). They can be localized in the nucleus, associated with heterochromatin and mitotic chromosomes, and exhibit potent transcriptional effect (4). Some activated immune cells lead to increased serum immunoglobulin (Ig) levels and cytokines that are typical of Th2-driven hyper-responsiveness (5). In this regard, these cytokines are able to regulate the transcription of

Key words: cytokines, osteoclasts, osteocytes, bone diseases

Mailing address:

Prof. Pio Conti,
Immunology Division,
Medical School,
University of Chieti-Pescara, Italy

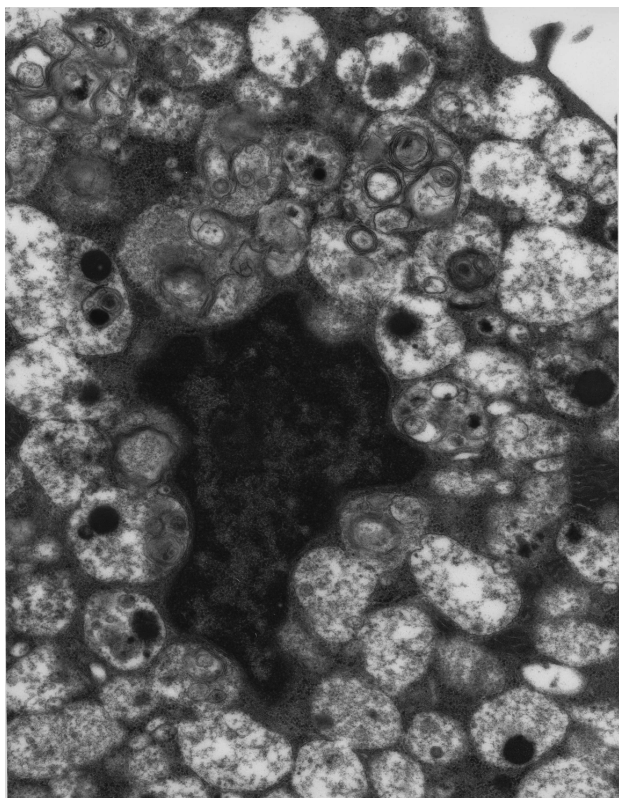


Fig. 1. Human cord-blood mast cell cultured for 15 weeks in RPMI medium. Electron microscope image magnified 34,500 X.

cytokines typically associated with a Th2 response. Some cytokines play an important role in asthma and others in allergic-type diseases (6) and enhance experimental allergic inflammation by directly stimulating mast cells to produce inflammatory cytokines (7). In addition, mast cells and their secreted products play a potentially important pathogenic role in bone loss of osteoporosis (8). Lymphocytes and a number of cytokines regulate osteoclastogenesis, osteoblast functions and osteoimmunology, which is a discipline that studies the interaction between the immune system and bone cells and involves cytokine expression and release (9). Regulatory T cells (Tregs) are produced by Th2 cells and are inhibited by TGF β and IL-4 (10). Tregs function to restore immune homeostasis after inflammatory responses in order to limit inflammation and prevent chronic inflammatory diseases (10). It has been found that these immune cells have the capacity to

inhibit osteoclast differentiation from peripheral blood mononuclear cells in a cytokine-dependent manner (11).

Osteoclasts are unique giant multinucleated cells involved in bone resorption (12). Maintenance of skeletal integrity is an important process characterized by timely regulation between bone formation and bone resorption. It has been reported that inflammatory diseases predispose to osteoclastic bone loss, which leads us to think that inflammatory cytokines play critical roles in osteoclast formation (13).

Physiologically, osteoclastogenesis is sustained by osteoblasts, cells arising from the bone marrow stromal cells (by differentiation of pluripotent mesenchymal stem cells) which, following the activation of different pathways and specific transcription factors, differentiate into mature cells producing bone matrix (14). It has been reported that there is an intercommunication between osteoblasts activity and osteoclasts, which is important in regulating bone remodeling (15). This relationship is also dynamically influenced by the immune cells and cytokines, an activity called osteoimmunological regulation which presents the links from bench to bedside. Bone remodeling is a restructuring process of the bone which is important not only for the normal bone mass and strength, but also for the mineral homeostasis. Bone remodeling is stringently regulated by communication between bone component cells such as osteoclasts, osteoblasts and osteocytes (16). An imbalance of this process is often linked to various bone diseases.

Physiological bone remodeling depends upon a balance between the action of bone-resorbing cells, osteoclasts, and bone-forming cells, osteoblasts (17). In inflammatory diseases, this balance is broken up and the role of inflammatory cytokines such as IL-1 and TNF α are fundamental, since they induce osteoclast differentiation and inhibit osteoblast maturation, leading to an exacerbation of the inflammatory states (18).

Interleukin-1 (IL-1) is a polypeptide produced by activated mononuclear phagocytes. Treatments of IL-1 *in vivo* causes fever and synthesis of acute phase protein cartilage and bone resorption, and stimulate fibroblasts and chondrocytes to make potent inflammatory compounds such as prostaglandins,

leukotrienes and collagenase. Therefore, IL-1 is an important inflammatory mediator and may be involved in the destruction of cartilage and bone that is a feature of rheumatoid arthritis and other inflammatory diseases of joints (19). IL-1 is increased in plasma of patients with severe infections and septic shock and can also stimulate the release of thromboxane B2 (TxB2) (another arachidonic acid product) by PMNs and macrophages. IL-1 has activities upon non-immune cells which promote the degradation of connective tissue matrices and stimulates bone resorption through a primary action on osteoblasts (17).

It has been reported that IL-1 is involved in bone loss induced by estrogen deficiency (20). Blocking IL-1 or its receptor reduces the bone resorption in osteoporosis. The mechanisms by which IL-1 provokes bone loss is through its capacity to increase receptor activation of nuclear factor- κ B ligand (RANKL) expression on osteoclast differentiation (20). IL-1 can also up-regulate the effects of TNF α on osteoclast precursors, since TNF α is also involved in osteoclastogenesis, bone loss, cancer and inflammation, effects mediated by its interaction with RANKL, NF κ B and AP-1 expression (21). TNF α , mainly produced by activated T cells and macrophages, is also involved in inflammation and its increases could be one of the mechanisms responsible for bone loss. The effect of TNF α on osteoclastogenesis is upregulated by IL-1.

IL-6 is a factor that induces B cells to produce immunoglobulins and is a pleiotropic cytokine with a wide range of biological activities in immune regulation, hematopoiesis, inflammation and oncogenesis. Accumulating evidence indicates pathological roles for IL-6 in various disease conditions, such as inflammatory, autoimmune and malignant diseases (22). Acting on estrogen deprivation, IL-6 is also involved in bone loss, even if it is not essential for bone resorption.

The pleiotropic cytokines, transforming growth factor- β (TGF- β), is predominantly expressed in the immune system and osteoblasts and is believed to be an important compound with potent immunoregulatory properties (23). TGF- β has been identified in mammals and regulates the development and functions of various immune cells. TGF- β regulates cell proliferation through controlling the

expression of cell cycle regulators and one of the most important effects of TGF- β on T cells is its capacity to suppress IL-2 production, an effect that leads to anti-proliferation of activated T cells. In addition, TGF- β and interleukin-10 (IL-10) play critical roles in suppressing the immune response. TGF- β is also involved in osteoclastogenesis, acting on osteoclast and osteoblast generation (24). TGF β is implicated in the pathogenesis of bone loss by preventing bone loss at the site of the injection as reported *in vivo*. TGF β found in the bone matrix modulates the activity of osteoblasts and osteoclasts and is released and activated during bone resorption.

However, the exact mechanism/s how inflammatory cytokines perturbs the pathophysiology and homeostasis of the bone, it is still unknown.

Parfitt AM. et al. reported that in experimental animals parathyroid hormone stimulates bone cells by increasing cell membrane permeability to calcium and is involved in the proliferation of osteoprogenitor cells into osteoclasts, an effect that augments the bone turnover (25). In addition, this hormone stimulates osteoclasts and acts on osteocytes causing a quick mobilization of calcium, an effect mediated by the activation of adenylate-cyclase (26). Since the osteocytes potentially contribute to the controls of bone remodeling, as well as being involved in mechanical stress, we propose that there is a relationship between osteocytes and cytokine-derived mast cells which are also involved in stress.

The osteoclasts along with osteoblasts are important cells which contribute to the maintenance of healthy bone metabolism (27). It has been reported that osteoclast activity contributes to the inflammatory response and destructive activity, as for example, in osteoporosis; whereas an increased osteoblast activity can result in osteopetrosis (28).

Cytokines such as IL-1, TNF α , M-CSF, IL-7, IL-17, IL-23, IL-6, TGF- β , IFN- γ and others, are important proteins acting indirectly on osteoclastogenesis, promoting receptor activator factor of nuclear factor κ B ligand (RANKL) release from other cells (29). Suppression of cytokine signaling provokes the inhibition of Janus Kinase (JAK)-signal transducer and activator of transcription (STAT) pathways (27).

Human bone cells can be obtained by the outgrowth of cells from bone chips discarded after orthopedic procedures (30). Usually the small bone

fragments are washed in calcium magnesium free buffered saline solution in order to remove blood and bone marrow and the cells are cultured *in vitro*. Another method for studying osteoblasts *in vitro*, includes the rat osteosarcoma cell line that exhibits osteoblast-like properties and expresses a growth hormone-response JAK2/STAT5 signaling system (27).

Growth responses of the osteoblasts are usually studied for cytokine concentrations and characterizations. Altered osteoblast differentiation *in vitro* has already been associated with *in vivo* alterations of bone metabolism and might help to explain some pathological conditions *in vivo* (31). In addition, it is well known that exposure of osteoblasts to certain cytokines provokes cell modifications and changes in the metabolic functions.

Osteoclasts, derived from hematopoietic stem cells, are responsible for bone synthesis and for bone resorption, these effects are influenced by several factors including NF- κ B ligand, monocyte-colony stimulating factor and some cytokines. Cytokines, during the dynamic of osteoclast generation, provide information about local cellular metabolism, reflecting the status of the bone formation. Therefore, they control the osteoclast formation. In fact, IL-1 β , TNF α , TGF- β , IL-2, IL-6, IL-8, M-CSF and IFN- γ are involved in osteoclast generation and increasing bone resorption; while IL-4, IL-10, IL-12, IL-18 and IFN- γ inhibit the formation and several functions of osteoclasts (32).

For example, Goodman et al. (33) have demonstrated that even in high doses, IFN- γ did not cause bone loss in rats and is not associated with any degree of *in vitro* impairment in osteoblastic differentiation, proliferation, or increase in cell death rate. Metabolic alterations of osteoblasts or osteoblast-like cells might lead to a decrease in bone formation and to an *in vivo* bone loss.

M-CSF affinity receptors (c-fms) are expressed on cells of the monocyte/macrophage lineage and the cytokine M-CSF is well known, acting as an essential factor in osteoclast formation inducing osteoclast proliferation, differentiation and survival (34). It has been reported that administration of an antibody anti-M-CSF receptor completely blocks osteoclastogenesis and bone erosion induced by TNF α administration in chronic inflammatory states

(29).

M-CSF (monocyte-colony stimulating factor) along with RANKL are osteoclastogenic factors which induce proliferation and differentiation of osteoclast precursors and survival of mature osteoclasts (28). Granulocyte colony-stimulating factor (G-CSF) is also involved in osteoclastogenesis, in fact, experimental animals treated with G-CSF for several weeks show osteopenia due to an increase of osteoclast number and activity. Moreover, G-CSF induces osteoblast apoptosis through an augmentation of osteoblast turnover (35). Therefore G-CSF suppresses osteoblasts, probably acting through other hematopoietic cells but not through the RANKL which seems to remain constant and not involved in this case.

Some of these effects, such as osteoclastogenesis and bone resorption are mediated by monocyte activation, which releases many inflammatory cytokines such as TNF α . It is well known that TNF α is mainly produced by activated T cells and it is also involved in inflammation and cancer-induced bone loss, both systemically and *in loco*. Several authors reported that TNF α enhances osteoclast formation and differentiation by up-regulating stromal cell production of RANKL and M-CSF, an effect mediated by the synergistic action of NF- κ B and AP-1. Therefore, the inhibition of TNF α may have potential therapeutic functions in several diseases including osteoporosis and bone resorption.

There is evidence that there is a known interrelationship between interferons and osteoclasts (36). In humans, IFN γ is positively correlated with bone erosions in several diseases such as rheumatoid arthritis. In contrast, IFN γ is able to restore bone resorption in osteopetrosis. However, IFN γ does not prevent bone loss in rheumatoid arthritis. IFN γ plays an important role during the commitment of pluripotent mesenchymal stem cells into the osteoblastic cells, most probably by accelerating this process. In addition, several interferon IFN γ -inducible genes are expressed during the proliferative phase by pluripotent mesenchymal stem cells undergoing osteoblastic differentiation *in vitro* (37). However, the exact role of IFN γ and osteoclast differentiation remains poorly defined.

The IL-17 produced by Th17 cells is also positively involved in the generation of osteoclasts,

most likely in conjunction with RANKL and other inflammatory cytokines (38); whereas IL-27 seems to be an anti-osteogenic cytokine (39).

Lack of cytokines in knockout experimental animals may exhibit variable forms of osteopathogenesis and the effects of cytokines in bone pathophysiology is not well understood. The concepts expressed in this article can be useful in understanding the role of cytokines in promoting clinical bone repair, in various pathologic conditions.

REFERENCES

1. Werman A, Werman-Venkert R, White R, Lee JK, Werman B, Krelin Y, Voronov E, Dinarello CA, Apte RN. The precursor form of IL-1alpha is an intracrine proinflammatory activator of transcription. *Proc Natl Acad Sci USA* 2004; 101(8):2434-9.
2. Bullens DM, Decraene A, Seys S, Dupont LJ. IL-17A in human respiratory diseases: innate or adaptive immunity? *Clin Dev Immunol* 2013; 2013:840315.
3. Shaik-Dasthagirisahab YB, Varvara G, Murmura G, Saggini A, Caraffa A, Antinolfi P, Tete' S, Tripodi D, Conti F, Cianchetti E, Toniato E, Rosati M, Speranza L, Pantalone A, Saggini R, Tei M, Speziali A, Conti P, Theoharides TC, Pandolfi F. Role of vitamins D, E and C in immunity and inflammation. *J Biol Regul Homeost Agents* 2013; 27(2):291-5.
4. Lin HY, Davis PJ, Tang HY, Mousa SA, Luidens MK, Hercbergs AH, Davis FB. The pro-apoptotic action of stilbene-induced COX-2 in cancer cells: convergence with the anti-apoptotic effect of thyroid hormone. *Cell Cycle* 2009; 8(12):1877-82.
5. Dong GH, Liu MM, Wang D, Zheng L, Liang ZF, Jin YH. Sub-chronic effect of perfluorooctanesulfonate (PFOS) on the balance of type 1 and type 2 cytokine in adult C57BL6 mice. *Arch Toxicol* 2011; 85(10):1235-44.
6. Holgate ST. The epithelium takes centre stage in asthma and atopic dermatitis. *Trends Immunol* 2007; 28(6):248-51.
7. Kritas SK, Saggini A, Varvara G, Murmura G, Caraffa A, Antinolfi P, Toniato E, Pantalone A, Neri G, Frydas S, Rosati M, Tei M, Speziali A, Saggini R, Pandolfi F, Cerulli G, Theoharides TC, Conti P. Luteolin inhibits mast cell-mediated allergic inflammation. *J Biol Regul Homeost Agents* 2013; 27(4):955-9.
8. Chiappetta N, Gruber B. The role of mast cells in osteoporosis. *Semin Arthritis Rheum* 2006; 36(1):32-6.
9. Shinoda K, Sugiyama E, Taki H, Harada S, Mino T, Maruyama M, Kobayashi M. Resting T cells negatively regulate osteoclast generation from peripheral blood monocytes. *Bone* 2003; 33(4):711-20.
10. Zaiss MM, Axmann R, Zwerina J, Polzer K, Gückel E, Skapenko A, Schulze-Koops H, Horwood N, Cope A, Schett G. Treg cells suppress osteoclast formation: a new link between the immune system and bone. *Arthritis Rheum*. 2007; 56(12):4104-12.
11. Kim YG, Lee CK, Nah SS, Mun SH, Yoo B, Moon HB. Human CD4+CD25+ regulatory T cells inhibit the differentiation of osteoclasts from peripheral blood mononuclear cells. *Biochem Biophys Res Comm* 2007; 357(4):1046-1052
12. Glowacki JI, Jasty M, Goldring S. Comparison of multinucleated cells elicited in rats by particulate bone, polyethylene, or polymethylmethacrylate. *J Bone Miner Res* 1986; 1(4):327-31.
13. Pacifici R, Brown C, Puschek E, et al. Effect of surgical menopause and estrogen replacement on cytokine release from human blood mononuclear cells. *Proc Natl Acad Sci USA* 1991; 88(12):5134-5138.
14. Nakashima T, Hayash M, Takayanagi H. Regulation of bone resorption by osteocytes. *Clin Calcium* 2012; 22(5):685-96.
15. Del Fattore A, Teti A. The tight relationship between osteoclasts and the immune system. *Inflamm Allergy Drug Targets* 2012; 11(3):181-7.
16. Nakashima T. Regulation of bone homeostasis by bone cells. *Clin Calcium* 2013; 23(2):218-28.
17. Baum R, Gravalles EM. Impact of inflammation on the osteoblast in rheumatic diseases. *Curr Osteoporos Rep* 2014; 12(1):9-16.
18. Suda T, Kobayashi K, Jimi E, Udagawa N, Takahashi N. The molecular basis of osteoclast differentiation and activation. *Novartis Found Symp* 2001; 232:235-47.
19. Bird TA, Saklatvala J. Identification of a common class of high affinity receptors for both types of

- porcine interleukin-1 on connective tissue cells. *Nature* 1986; 324(6094):263-6.
20. Nich C, Langlois J, Marchadier A, Vidal C, Cohen-Solal M, Petite H, Hamadouche M. Oestrogen deficiency modulates particle-induced osteolysis. *Arthritis Res Ther* 2011; 13(3):R100.
 21. Weitzmann MN, Cenci S, Rifas L, Brown C, Pacifici R. Interleukin-7 stimulates osteoclast formation by up-regulating the T-cell production of soluble osteoclastogenic cytokines. *Blood* 2000; 96(5):1873-8.
 22. Kishimoto T. IL-6: from its discovery to clinical applications. *Int Immunol* 2010; 22(5):347-52.
 23. Thomas T, Martin A. Pathways regulating bone formation: a complex network. *J Soc Biol* 2008; 202(4):257-64.
 24. Yamaguchi M, Weitzmann MN, Murata T. Exogenous regucalcin stimulates osteoclastogenesis and suppresses osteoblastogenesis through NF- κ B activation. *Mol Cell Biochem* 2012; 359(1-2):193-203.
 25. Parfitt AM. The actions of parathyroid hormone on bone: relation to bone remodeling and turnover, calcium homeostasis, and metabolic bone diseases. II. PTH and bone cells: bone turnover and plasma calcium regulation. *Metabolism* 1976; 25(8):909-55.
 26. Chen JR, Plotkin LI, Aguirre JI, Han L, Jilka RL, Kousteni S, Bellido T, Manolagas SC. Transient versus sustained phosphorylation and nuclear accumulation of ERKs underlie anti-versus pro-apoptotic effects of estrogens. *J Biol Chem* 2005; 280(6):4632-8.
 27. Gao A, Van Dyke TE. Role of Suppressors of Cytokine Signaling 3 in Bone Inflammatory Responses. *Front Immunol* 2014; 4:506
 28. Lange U, Teichmann J, Schett G, Neumann E, Müller-Ladner U. Osteoimmunology: how inflammation influences bone metabolism. *Dtsch Med Wochenschr* 2013; 138(37):1845-9.
 29. Mori G, D'Amelio P, Faccio R, Brunetti G. The Interplay between the Bone and the Immune System. *Clin Dev Immunol* 2013; 2013:720504.
 30. Moreira RO, Balduino A, Martins HSLH, Reis JSN, Duarte MEL, Farias MLF, Borojevic R. Ribavirin, but Not Interferon α -2b, is Associated with Impaired Osteoblast Proliferation and Differentiation In Vitro. *Calcif Tissue Int* 2004; 75:160-168.
 31. Delany AM, Hankenson KD. Thrombospondin-2 and SPARC/osteonectin are critical regulators of bone remodeling. *J Cell Commun Signal* 2009; 3(3-4):227-38.
 32. Kitaura H, Kimura K, Ishida M, Sugisawa H, Kohara H, Yoshimatsu M, Takano-Yamamoto T. Effect of Cytokines on Osteoclast Formation and Bone Resorption during Mechanical Force Loading of the Periodontal Membrane. *ScientificWorld Journal* 2014; 2014:617032.
 33. Goodman GR, Dissanayake IR, Gorodetsky E, Zhou H, Ma YF, Jee WS, Epstein S. Interferon- α , unlike interferon- γ , does not cause bone loss in the rat. *Bone* 1999; 25(4):459-63.
 34. Munn DH, Cheung NK. Antibody-dependent antitumor cytotoxicity by human monocytes cultured with recombinant macrophage colony-stimulating factor. Induction of efficient antibody-mediated antitumor cytotoxicity not detected by isotope release assays. *J Exp Med* 1989; 170(2):511-26.
 35. Christopher MJ, Link DC. Granulocyte colony-stimulating factor induces osteoblast apoptosis and inhibits osteoblast differentiation. *J Bone Miner Res* 2008; 23(11):1765-74.
 36. Shinoda K, Sugiyama E, Taki H, Harada S, Mino T, Maruyama M, Kobayashi M. Resting T cells negatively regulate osteoclast generation from peripheral blood monocytes. *Bone* 2003; 33(4):711-20.
 37. Duque G, Huang DC, Macoritto M, Rivas D, Yang XF, Ste-Marie LG, Kremer R. Autocrine regulation of interferon γ in mesenchymal stem cells plays a role in early osteoblastogenesis. *Stem Cells* 2009; 27(3):550-8.
 38. Komatsu N, Takayanagi H. Bone and cartilage destruction in rheumatoid arthritis. *Clin Calcium* 2012; 22(2):179-85.
 39. Zolochewska OI, Diaz-Quñones AO, Ellis J, Figueiredo ML. Interleukin-27 expression modifies prostate cancer cell crosstalk with bone and immune cells in vitro. *J Cell Physiol* 2013; 228(5):1127-36.

CASE REPORT

**THERAPY WITH ADEFOVIR DIPIVOXIL IN PATIENTS WITH CHRONIC HEPATITIS B
MAY CAUSE PATHOLOGICAL CALCANEAL OCCULT FRACTURES**

B. CHAN, A. ANAND, W. LIU, T. YANG, R. CHANG, X. CHENG and W. SONG

*Department of Orthopedic Surgery, Sun Yat-Sen Memorial Hospital of Sun Yat-Sen University,
Guangzhou, People's Republic of China*

Received November 11, 2014 - Accepted November 30, 2014

Adefovir dipivoxil (ADV), a eutherapeutic antiviral drug, is widely used in the treatment of chronic hepatitis B. However, long-term ADV therapy carries several side effects. Hypophosphatemic osteomalacia (HO) is one of them. Although HO is a fairly rare occurrence, it can cause severe painful manifestations and potentially be misdiagnosed as osteoporosis or ankylosing spondylitis (AS). We present a case of a 50-year-old man who suffered bilateral heel pain induced by calcaneal stress fractures after receiving nearly 6 years of ADV treatment. He had a 15-month history of bone pain involving his shoulders, rib cage, back, pelvis and both sides of heel portions as well as weakness in the lower limbs. Prior to admission to our hospital, he was misdiagnosed with osteoporosis, hypokalemia and AS. Therefore physicians should be made aware that osteomalacia and pathological fractures may be caused by drug-induced renal dysfunction. Level of Evidence: IV - Case Report.

Adefovir dipivoxil (ADV) is an important antiviral agent used in the treatment of chronic hepatitis B. The usage of this drug has considerably increased since 2002 and side effects such as nephrotoxicity and bone damage have been noted.

Long-term ADV intake can damage proximal renal tubule, which leads to impaired resorption of amino acids, urate, glucose and phosphate, and induce Fanconi's syndrome (1). The chronic loss of phosphate breaks the calcium and phosphorus balance, resulting in failure of bone mineralization, which may cause hypophosphatemic osteomalacia (HO). Recently, cases of ADV-induced HO with pathological fracture have been occasionally reported (2).

In this manuscript, we present a case of bilateral pathological occult calcaneal fractures resulting

from HO during the course of ADV administration for treating chronic hepatitis B.

Case

The patient was a 50-year-old man who had received ADV therapy for 5 years and 11 months. He had been diagnosed to have hepatitis B for 20 years and had started antiviral therapy (ADV, 10mg/day) in November 2007. One year prior to his admission to our hospital, he started experiencing multiple bone pain in his rib cage, back, pelvis and shoulders with weakness of the lower limbs with no history of trauma. He visited a clinic and was administered oral potassium therapy for hypokalemia. However, the pain gradually aggravated, and he started experiencing bilateral heel pain which made him unable to stand for long periods. In addition, he had a

Key words: hypophosphatemic osteomalacia, calcaneal stress fractures, chronic hepatitis B, antiviral drugs

Mailing address:

Dr. Weidong Song,
No.107, Yanjiang West Road,
Yuexiu District,
Guangzhou 510120,
People's Republic of China
e-mail: songsz999@163.com

1973-6401 (2014) Print

Copyright © by BIOLIFE, s.a.s.

This publication and/or article is for individual use only and may not be further reproduced without written permission from the copyright holder.

Unauthorized reproduction may result in financial and other penalties
**DISCLOSURE: ALL AUTHORS REPORT NO CONFLICTS OF
INTEREST RELEVANT TO THIS ARTICLE.**

history of chronic kidney disease. Therefore, he was admitted to our hospital for further investigation in October 2013.

Physical examination was remarkable for tenderness on both ribs and bilateral Achilles tendon attachment points to calcaneus. Our initial impression of this patient with dorsalgia, multiple arthralgia and claudication was that the symptoms might be caused by spondyloarthropathies (SpAs) such as ankylosing spondylitis (AS). However, his human leucocyte antigen B27 (HLA-B27) was negative and his erythrocyte sedimentation rate (ESR, 21 mm/h; N, <15 mm/h) was slightly increased. Magnetic resonance imaging (MRI) of sacrum and ilium showed multiple bone edemas, but there were no abnormalities in the sacroiliac joints. Therefore the diagnosis of SpAs needed to be reconsidered.

Further examinations were subsequently performed. Dual energy X-ray absorptiometry (DEXA) was used to measure the bone mineral density (BMD) and its printouts showed T-score were -3.2 and -3.7 at lumbar spine and femoral neck respectively. Bone scintigraphy demonstrated increased uptake of ^{99m}Tc-methylene diphosphonate (HMDP) in ribs and bilateral calcaneuses (Fig. 1). Though abnormal uptake in ribs was visible, the chest radiography and computed tomography (CT)

did not show any fracture lines in ribs. MRI revealed bilateral calcaneal occult fractures. It is worth noting that the calcaneal fracture lines could be clearly seen on MRI but were hardly noticeable at radiography (Fig. 2).

Furthermore, the laboratory data revealed hypophosphatemia (0.51mmol/L; N, 0.60-1.60 mmol/L), hypouricemia (98 µmol/L; N, 120-452 µmol/L) and increased levels of both serum total alkaline phosphatase (TALP, 254 U/L; N, 45-125 U/L) and bone-specific alkaline phosphatase (BALP, 71.0 µg/L; N, 3.7-20.9 µg/L). He had intact serum calcium (2.24 mmol/L; N, 2.10-2.60 mmol/L), parathyroid hormone (PTH, 23 pg/ml; N 11-67 mg/ml), β-crosslap (0.553 ng/ml; N, ≤0.584 ng/ml), N-terminal midfragment osteocalcin (N-MID.Oc 27.1 ng/ml; N, 14.0-42.0 ng/ml) and mildly decreased Serum 25-hydroxyvitamin D (35.0 nmol/L; N, 47.4-144.0 nmol/L). In addition, he had a remarkably increased Amino-terminal propeptide of type I procollagen (PINP, 69.24 ng/ml; N, ≤36.4 ng/ml). His serum creatinine (Cr, 163 µmol/L; N, 44-133 µmol/L) and blood urea nitrogen (BUN, 7.9 mmol/L; N, 3.0-7.2 mmol/L) levels were also increased, which suggested chronic renal insufficiency. Arterial blood gas analysis revealed hypokalemia (2.32 mmol/L; N, 3.50-5.30 mmol/L), hyperchloremia (111.6 mmol/L;

Table I. Urine chemistry of the patient.

Test	Value	Normal range(units)
Volume	2.70	1.00 - 2.00 L
PH	7.0	5.5 - 6.5
Ur. phosphate	53.2	23.0 - 48.0 mmol/24h
TmPO ₄ /GFR	1.62	0.80 - 1.35
Ur. kalium	101.1	51.0 - 102.0 mmol/24h
Ur. glucose	Positive	Negative
Ur. protein	1163	0 - 150 mg/24h
Ur. amino acids	542	50 - 200mg/24h
Ur. Albumin	221	0 - 30 mg/L
α1-microglobulin	231	0 - 12 mg/L
β2-microglobulin	87.50	0 - 0.25 mg/L
Ur. N-acetyl-β-D-glucosaminidase	52.0	1.1 - 12.0 U/L

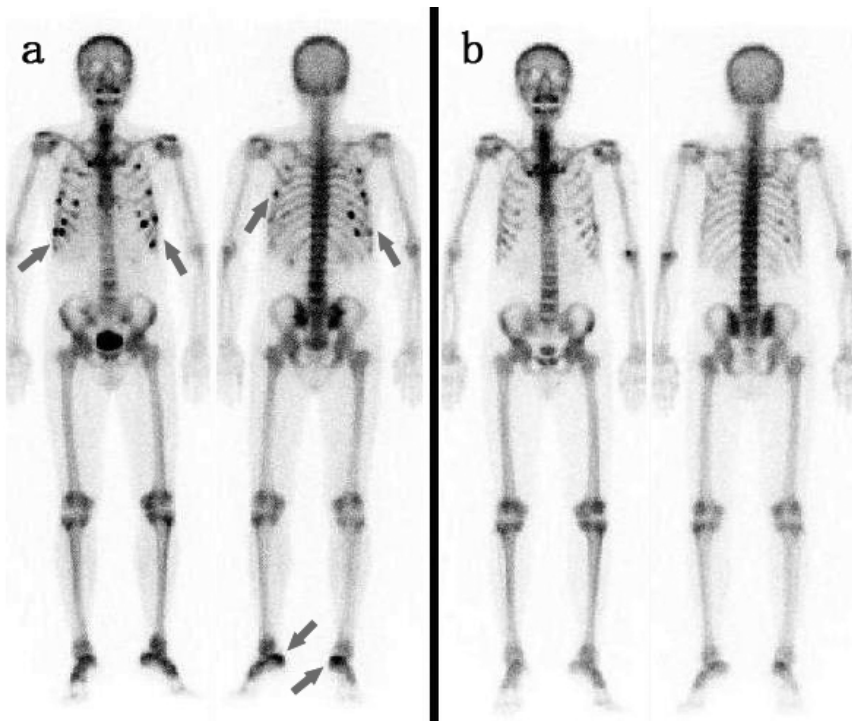


Fig. 1. *99mTc-methylene diphosphonate (HMDP) bone scintigraphy. A) Increased uptake in ribs and bilateral calcanei (Arrow). B) A follow-up examination conducted 20 weeks after the withdrawal of adefovir dipivoxil revealed the improvement of bone metabolism.*

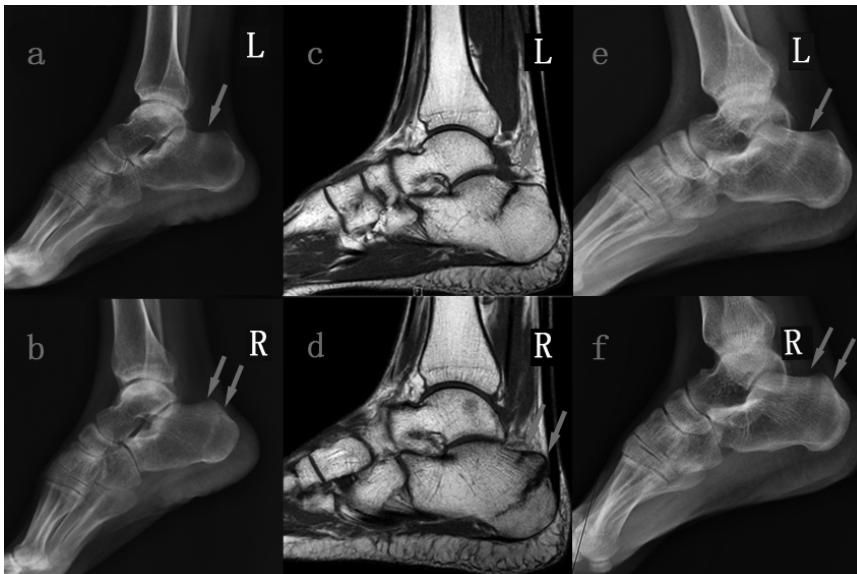

Fig. 2. *X-ray and magnetic resonance imaging showed bilateral pathological calcaneal occult fractures (Arrow). A and B) Radiographic osteopenia and a band of sclerosis between the calcaneal tuberosity and the posterior facet of the subtalar joint. C and D) Calcaneus marrow edema and fracture lines located in the same region of the band of sclerosis. E and F) A follow-up X-ray conducted 20 weeks after the withdrawal of adefovir dipivoxil showed increased bone mass and fuzzy fracture lines.*

Table II. Statistics of 47 cases with hypophosphatemia osteomalacia induced by long-term ADV therapy.

No.	Case Report	Publication	Year	Author	Heel pain cases	Muscle weakness cases	Total cases
1	Adefovir dipivoxil-induced Fanconi syndrome and hypophosphatemic osteomalacia associated with muscular weakness in a patient with chronic hepatitis B	J South Med Univ	2011	Ling Lee et al.	0	1	1
2	A case of hypophosphatemic osteomalacia induced by adefovir dipivoxil and clinicopathologic analysis	the 6th National Conference on Osteoporosis & Bone Mineral Disease, Xi'an	2011	Ning Fu et al.	0	0	1
3	A case of osteomalacia, hypophosphatemia, hypercalciuria, proteinuria, renal glycosuria and renal insufficiency: a case report about Fanconi's syndrome induced by adefovir dipivoxil	the 6th National Conference on Osteoporosis & Bone Mineral Disease, Xi'an	2011	Xinyu Shao et al.	0	1	1
4	Diagnosis and treatment of acquired Fanconi's syndrome: a case report	the 10th National Conference on Endocrinology, Suzhou	2011	Mingwei Shao et al.	0	0	1
5	A case of Fanconi's syndrome induced by adefovir therapy for chronic hepatitis B	Chinese Hepatology	2011	Hao Bai et al.	0	0	1
6	A case with poly-bone pain, decrease of bone density and increase of serum creatinine related to adefovir dipivoxil treatment in a chronic hepatitis B patient	Chin J Hepatol	2011	Xuebing Yan et al.	1	0	1
7	Fanconi syndrome induced by adefovir dipivoxil: a case report	Chin J Intern Med	2011	Dong Wang et al.	0	0	1
8	A case of adefovir dipivoxil induced hypophosphatemic osteomalacia and literature review	Chin J Intern Med	2011	Xiaofang Sun et al.	0	0	1
9	Adefovir-induced hypophosphatemic osteomalacia: 2 cases report and literature review	Clinical Misdiagnosis & Mitherapy	2012	Jian Wu et al.	0	0	2
10	A patient with adefovir dipivoxil associated renal disease was mistaken as primary osteoporosis	Chin J Osteoporosis & Bone Miner Res	2012	Nan Zhang et al.	1	0	1
11	Renal tubular acidosis and secondary hypophosphatemic osteomalacia caused by adefovir dipivoxil: 3 cases report	Chin J Osteoporosis	2012	Dan Wu et al.	0	3	3
12	Fanconi syndrome with hypophosphatemic osteomalacia: a case report and literature review	Chin J Misdiagn	2012	Xin Lee et al.	1	0	1
13	Long term adefovir dipivoxil for chronic hepatitis B treatment induced Fanconi syndrome: a case report	Chin J Clinicians (electronic edition)	2012	Li Wang et al.	0	1	1
14	Two cases of hypophosphatemic osteomalacia induced by the small dose of adefovir dipivoxil and literature review	Chin J Osteoporosis	2013	Lingling He et al.	1	0	2
15	Two cases of adefovir dipivoxil-induced hypophosphatemia osteomalacia and literature analysis	Pharm Care Res	2013	Jinying Wang et al.	1	0	2
16	Six cases of hypophosphatemic osteomalacia induced by adefovir dipivoxil	Chin J Endocrinol Metab	2013	Nan Zhang et al.	0	0	6

17	Adefovir dipivoxil induced hypophosphatemic osteomalacia: report of two cases	Chin General Practice	2013	Xia Wang et al.	0	1	2
18	A case of Fanconi syndrome induced by long-term excessive taking of adefovir dipivoxil	J Clin Hepatol	2013	Quanchu Wang et al.	0	0	1
19	Fanconi syndrome caused by adefovir dipivoxil: 3 cases report and literature review	Shandong Medical Journal	2013	Qiuzi Zhang et al.	1	2	3
20	Hypophosphatemia and chest pain related to adefovir dipivoxil treatment for chronic hepatitis B: report of two cases	J South Med Univ	2013	Zhiwei Liu et al.	0	0	2
21	Adefovir therapy for chronic hepatitis B induced Fanconi syndrome : 2 cases report and literature review	Clinical Focus	2013	Li Fang et al.	0	1	2
22	Drug-induced Fanconi syndrome: 3 cases report and literature review	Chin J Endocrinol Metab	2013	Mingxian Chen et al.	0	2	3
23	Low-dose adefovir dipivoxil-induced hypophosphatemic osteomalacia: Four cases Study	Chin General Practice	2013	Shumin Yan et al.	3	0	4
24	Clinical features of adefovir dipivoxil-induced Fanconi syndrome and hypophosphatemic osteomalacia	Chin J Endocrinol Metab	2014	Xiaojing Lee et al.	0	4	4
Total					9	16	47

N, 99-110 mmol/L) and metabolic acidosis (PH, 7.334; N, 7.350-7.450). Urinalysis is shown in Table I, indicating the dysfunction of the proximal renal tubule.

Based on the diagnostic imaging and laboratory data, we diagnosed hypophosphatemic osteomalacia and pathological calcaneal fractures due to Fanconi's syndrome secondary to ADV therapy. ADV was then replaced with entecavir (0.5mg/day), and calcitriol (0.5µg/day) as well as phosphate (1.5 g/day) were administered (3). Pain control relied on local physiotherapy and a non-steroid anti-inflammatory drug. Weight bearing was avoided (4). Eight weeks later, significant relief from heel pain was observed, though pain in the rib cage and shoulders did not disappear until 12 weeks after ADV withdrawal. After 20-weeks of treatment, his serum phosphate, creatinine and blood urea nitrogen levels were normal. A follow-up X-ray and bone scan showed that his bone mass had increased and bone metabolism returned to normal (Fig. 1 and 2).

DISCUSSION

ADV is a commonly used and eutherapeutic

antiviral agent for the treatment of chronic hepatitis B. It is primarily excreted in the urine and its toxicity often shows up in the kidneys. Previous studies indicated that the possible toxicity of ADV to the proximal renal tubule is through the accumulation of ADV in the renal tubules, which causes renal tubular epithelium apoptosis and mitochondrial toxicity. Subsequently, Fanconi's syndrome, as a result of dysfunction of the proximal tubule, leads to impaired resorption of amino acids, urate, bicarbonate, phosphate and potassium and increased excretion of these factors into the urine. Thus, the blood and urine tests of patients can show hypoproteinemia, hypouricemia, metabolic acidosis, hypophosphatemia, hypokalemia, proteinuria, alkaluria and hyperphosphaturia (5).

We herein present a case of pathological calcaneal occult fractures related to HO with typical serological manifestations induced by long-term low dose ADV therapy. Although the adverse drug reactions such as increases in creatinine, post-treatment ALP elevations, hypophosphatemia, abnormal renal function and renal failure are mentioned, the description on the side effects of ADV in its package insert is still far from comprehensive. Actually, an increasing number

of case reports from East Asian countries, especially China, have shown that some patients exhibited osteomalacia and subsequent fractures even on a low-dose ADV therapy. Therefore, the potential bone damage effects from ADV therapy should be brought to the physician's attention. As a similar case, a Japanese male with pathological calcaneal associated with ADV therapy, was reported this year (6). The case we present here is the first pathological calcaneal stress fracture related to ADV therapy reported in China. As we know, China has the largest number of HBV carriers in the world. In 2006, the Chinese Ministry of Health estimated that the HBsAg carrier rate in the Chinese population aged 60 years or less was 7.2% and that there were approximately 120 million HBV carriers in China (7). A considerable part of these HBV carriers have been receiving ADV therapy since its introduction to the Chinese market in 2005. We reviewed 47 cases of HO related to ADV therapy in China reported from 2011 to 2014, and found that 9 of them (19%, 9/47) had bilateral heel pain but none of them had been diagnosed with calcaneal fracture (Table II). A previous report described some patients with a high uptake in ankle and calcaneus revealed upon bone scan who had no bony abnormality or indiscoverable sclerosis bands on plain radiographs (8). It is difficult to determine fracture lines on CT or MRI in these cases; therefore, in accordance with our finding, we have reason to believe that this type of calcaneal fracture can be easily overlooked.

In addition, despite the increasing number of case reports published in the past ten years, it seems possible that generalized bone pain and muscle weakness caused by ADV therapy will still be misdiagnosed. Generalized bone pain tends to be misdiagnosed as primary osteoporosis if a patient has decreased BMD or multiple myeloma and if a patient has abnormal isotope uptake in multiple regions in the bone scan. Such patients with multiple arthralgias are likely to be mistakenly diagnosed as AS or rheumatoid arthritis. Furthermore, muscle weakness, a common concomitant symptom (34%, 16/47) that may be caused by Fanconi's syndrome-induced electrolyte disturbance, needs to be differentiated from myasthenia gravis, hyperthyroidism or other muscle diseases (Table II). We also found that ADV-induced HO seems to occur more frequently in the Asian Population. It is probably because Asia has the

largest population with HBV infection or a diet that relies mainly on vegetables. We have not enough evidence to confirm the role of potential genetic factors for the infrequency and sporadicity of the ADV induced osteomalacia.

In conclusion, long term oral administration of ADV can damage the renal tubular function and lead to Fanconi's syndrome and HO with pathological fractures. One fifth of patients with HO may present heel pain. To determine the presence of calcaneal fractures, we suggest that clinicians should pay serious attention to any abnormalities in calcaneal X-rays when their patients have heel pain with a history of ADV therapy or HO. If necessary, performing a bone scan or MRI would be a good choice for a definite diagnosis. An early and accurate diagnosis may help make a timely off-loading of the therapy and an excellent therapeutic outcome.

REFERENCES

1. Izzedine H, Hulot JS, Launay-Vacher V, Marcellini P, Hadziyannis SJ, Currie G, Brosgart CL, Westland C, Arterbrun S, Deray G. Renal safety of adefovir dipivoxil in patients with chronic hepatitis B: two double-blind, randomized, placebo-controlled studies. *Kidney Int* 2004; 66:1153-8.
2. Tanaka M, Setoguchi T, Ishidou Y, Arishima Y, Hirotsu M, Saitoh Y, Nakamura S, Kakoi H, Nagano S, Yokouchi M, Kamizono J, Komiya S. Pathological femoral fractures due to osteomalacia associated with adefovir dipivoxil treatment for hepatitis B: a case report. *Diagn Pathol* 2012; 7:108.
3. Law ST, Li KK, Ho YY. Acquired fanconi syndrome associated with prolonged adefovir dipivoxil therapy in a chronic hepatitis B patient. *Am J Ther* 2013; 20:e713-6.
4. Lassus J, Tulikoura I, Konttinen YT, Salo J, Santavirta S. Bone stress injuries of the lower extremity. *Acta Orthopaedica* 2002; 73:359-68.
5. Ahmad M. Abacavir-induced reversible Fanconi syndrome with nephrogenic diabetes insipidus in a patient with acquired immunodeficiency syndrome. *J Postgrad Med* 2006; 52:296-7.
6. Eguchi H, Tsuruta M, Tani J, Kuwahara R, Hiromatsu Y. Hypophosphatemic osteomalacia due to drug-

- induced Fanconi syndrome associated with adefovir dipivoxil treatment for hepatitis B. *Internal medicine* (Tokyo, Japan) 2014; 53:233.
7. Cui Y, Jia J. Update on epidemiology of hepatitis B and C in China. *J Gastroenterol Hepatol* 2013; 28(1):7-10.
 8. Kim DH, Sung DH, Min YK. Hypophosphatemic osteomalacia induced by low-dose adefovir therapy: focus on manifestations in the skeletal system and literature review. *J Bone Miner Metab* 2013; 31:240-6.

CASE REPORT

UNSTABLE IRREDUCIBLE FEMORAL NECK FRACTURE IN CHILDREN TREATED BY CLOSED REDUCTION AND INTERNAL FIXATION WITH JOYSTICK TECHNIQUE

N. SUNKU and M. PAI

*Department of Orthopaedics, Pariyaram Medical College, Kannur, India**Received August 24, 2014 - Accepted November 30, 2014*

Femoral neck fractures in children are an uncommon but difficult situation and associated with high complication rate. Avascular Necrosis (AVN) is one of the most serious complications of femoral neck fractures in children (1-3). In children the dense bone of femoral neck is surrounded by a strong periosteum and a high energy force must be applied before breaking it (2, 4). This explains the rarity of femoral neck fractures in children which are less than 1% of all fractures (3). Level of Evidence: IV - Case Report.

Case Report

A 5-year-old boy who was playing had a fall and sustained injury to his left hip. He was not able to stand by himself or walk immediately after the fall. He was admitted to the local hospital, assessed and referred. He presented to us 3 days after the fall. His general condition was stable and was taken up for investigations.

A plain radiograph of pelvis with both hips showed displaced fracture of the femoral neck. Initial radiographs were analyzed for fracture classification. He had sustained displaced Delbet type III femoral neck fracture (Fig 1).

We considered the possibility that ORIF might represent overtreatment, with a higher morbidity. Therefore CRIF was the preferred treatment. Here we used a Joystick Technique for closed reduction of this unstable irreducible femoral neck fracture. Initially we passed a k-wire close to ASIS and under c-arm guidance the k-wire was inserted in the proximal fragment (which was not under our control) and the fracture was reduced (Fig. 2). Closed reduction could be achieved in this case under fluoroscopic

control. Then after getting good closed reduction 2 Moore's smooth pins were passed parallel through the femoral neck to head.

The postoperative period was uneventful. Post operative spica was applied over the next 6 weeks during which time the patient was mobilized to full weight bearing.

Follow up of the patient at 3 months and 6 months showed united fracture with good range of movements (Fig. 3). Later the implant was removed. X-ray (Fig. 4) shows normal anatomy was restored with clinically good range of function.

DISCUSSION

Femur neck fractures were initially classified according to the four-part classification system described by Delbet and popularized by Colonna (1). 'Type I' was an intraarticular transepiphyseal fracture, 'type II' an intra-articular transcervical fracture, 'type III' an intra-articular cervicotrochanteric fracture, and 'type IV' an extracapsular intertrochanteric fracture. The fractures were also classified as 'non-displaced'

Key words: femoral neck fracture, internal fixation, children, closed reduction

Mailing address:

Dr. Nithin Sunku ,
'KRISHNA KUTEERA',
22,4th main,Nataraj layout,
J.P.nagar 7th phase,
Bangalore, India
e-mail: drsnithin@gmail.com

1973-6401 (2014) Print

Copyright © by BIOLIFE, s.a.s.

This publication and/or article is for individual use only and may not be further reproduced without written permission from the copyright holder.

Unauthorized reproduction may result in financial and other penalties
DISCLOSURE: ALL AUTHORS REPORT NO CONFLICTS OF

INTEREST RELEVANT TO THIS ARTICLE.

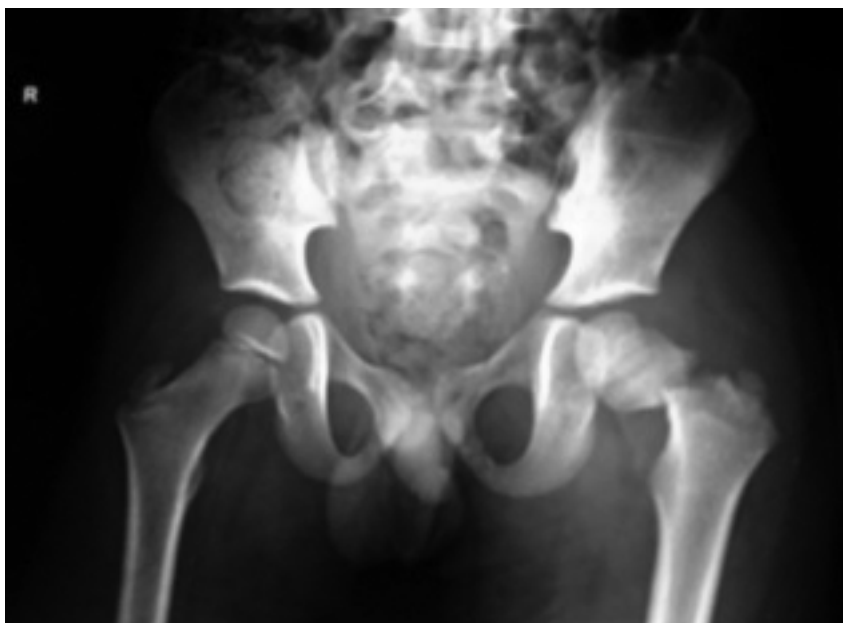

Fig. 1. A plain radiograph of pelvis with both hips (AP view) showing displaced femoral neck fracture (type III).

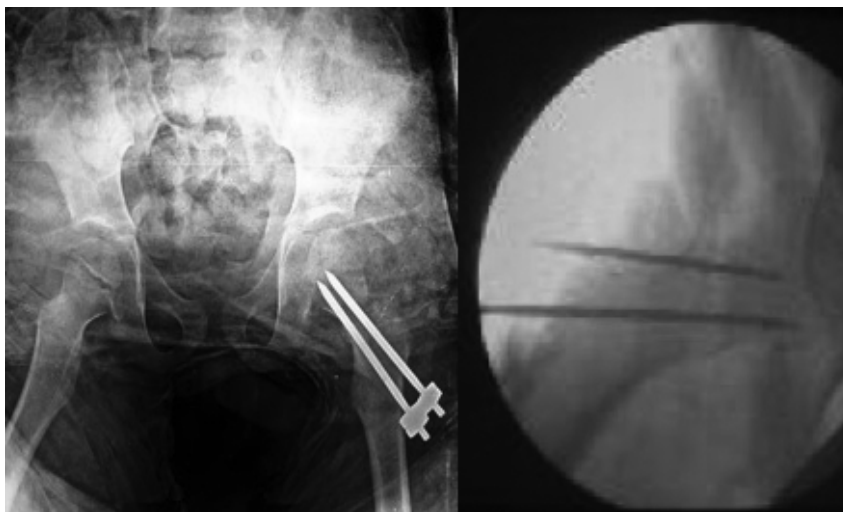

Fig. 2. Immediate postoperative radiograph and intra-op c-arm.

and 'displaced' (from minimum to complete).

Displaced fractures of the femoral neck are associated with a high rate of complications. AVN is the most serious and has been reported to have a variable incidence, depending on several factors

including age, the degree of initial displacement, the type of fracture, the time of surgery, and the method of fixation (5-11). However, there have been no reports relating the incidence of AVN to the method of treatment and the quality of reduction.

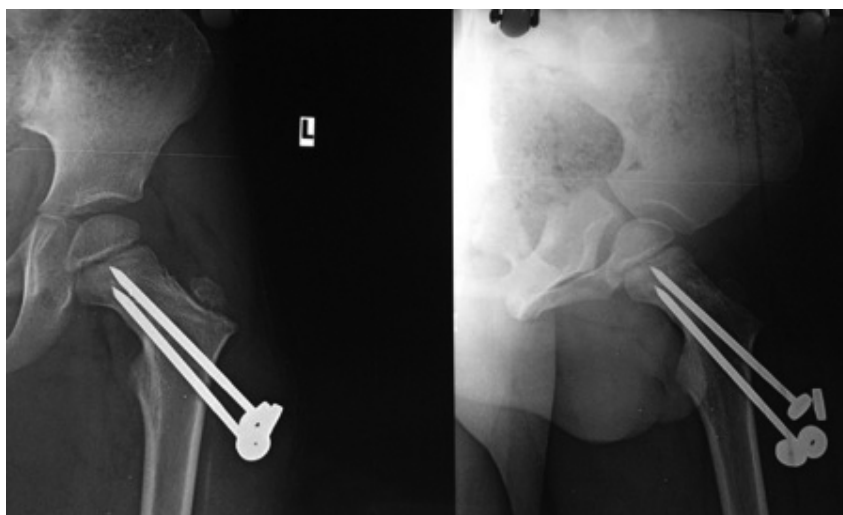


Fig. 3. A) At 3 months, fracture shows evidence of union B) AP radiograph at 6 months of follow up.

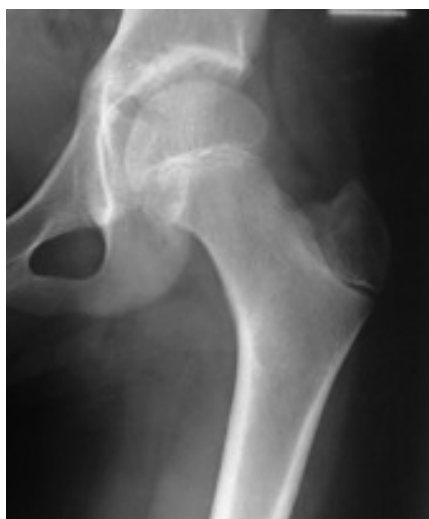

Fig. 4. X-ray taken after implant removal.

We believe that anatomic reduction by closed method and maintaining this reduction by internal fixation is the best way of managing pediatric femur neck fractures. In our opinion, closed reduction and internal fixation using a k-wire as Joystick technique even in irreducible fractures seems to be the most convenient method in children. The existence or absence of AVN is the main determinant of the clinical and radiographic outcomes in pediatric

femur neck fractures and the development of this complication should not be underestimated (12-18). AVN cannot be completely prevented or effectively treated, but its rate of occurrence may be decreased by performing an appropriate management, as stated above.

In conclusion, our method of early, stable closed reduction and internal fixation using a k-wire as Joystick technique is a technically simple yet effective method of treating difficult fractured neck femur. Although a larger series and multicentre trials are needed, we would safely recommend extension of this technique to stable fractures, to minimize the incidence of complications.

REFERENCES

1. Colonna PC. Fractures of the neck of the femur in children. *Clin Orthop* 1929; 6:793-7.
2. Trueta J. The normal vascular anatomy of human femoral head during growth. *J Bone Joint Surg (Br)*. 1957; 39:358-94.

3. Ratiff AHC. Fractures of neck of femur in children. *J Bone Joint Surg (Br)* 1962; 44:528-42.
4. Ratliff AHC. Complications after fracture of femoral neck in children and their treatment. *J Bone Joint Surg (Br)* 1970; 52:175.
5. Ratlif AHC. Fractures of neck of femur in children. *Orthop Clin N Am* 1974; 5:903-24.
6. Canale ST, Bourland WL. Fracture of the neck and intertrochanteric region of the femur in children. *J Bone Joint Surg (Am)* 1977; 59:431-43.
7. Heiser JM, Oppenheim WL. Fracture of the hip in children; a review of 40 cases. *Clin Orthop* 1980; 12:355-8.
8. Pforringer W, Rosemeyer B. Fractures of hip in children and adolescents. *Acta Orthop Scand* 1980; 51:91-108.
9. Canale ST. Fractures of the hip in children and adolescents. *Orthop Clin N Am* 1990; 21:341-52.
10. Tachdijian MO. Fractures of neck of femur. *Pediatric Orthopaedics* second Ed. Philadelphia; WB Saunders Co. 1990: 3231-47.
11. Davison BL, Weinstein SL. Hip fractures in children. A long-term follow up study. *J Paediatr Orthop* 1992; 12:355-8.
12. Hughes LO, Beaty JH. Fractures of head and neck of femur in children; current concepts review. *J Bone Joint Surg (Am)* 1994; 76:283-92.
13. Canale ST, Beaty JH. Pelvic and hip fractures. In Rockwood CA, Wilkins KE, Beaty JH (Eds) *Fractures in Children*. Ed 4, Philadelphia; Lippincot Raven 1996: 1109-93.
14. Ng CP, Cole WG. Effect of early hip decompression on the frequency of avascular necrosis in children with fracture of neck of femur. *Injury* 1996; 27:419-21.
15. Cheng JC, Tang N. Decompression and stable internal fixation of femoral neck fractures in children can affect the outcome. *J Paediatr Orthop* 1999; 19:338-43.
16. Mirdad T. Fractures of neck of femur in children. An experience at Aseer Central Hospital, Abha, Saudi Arabia. *Injury* 2002; 33:823-7.
17. Togrul E, Bayram H, Gulsen H. Fractures of femoral neck in children, long term follow up in 62 fractures. *Injury* 2005; 36:123-30.
18. Quick TJ, Eastwood DM. Pediatric fractures and dislocations of the hip and pelvis. *Clin Orthop* 2005; 432:87-96.

LETTER TO THE EDITOR

BIOCOMPATIBILITY OF SOME CERAMIC MATERIALS FOR CLINICAL APPLICATIONS

A. ZIRANU¹, P.F. MANICONE², A. SGAMBATO³, L. RAFFAELLI², S. CARERI¹,
F. MARIOTTI¹ and G. MACCAURO¹

¹Department of Geriatrics Sciences, Neuro-Sciences and Orthopedics Sciences, Catholic University, Rome; ²Department of Oral Sciences, Catholic University, Rome; ³Institute of General Pathology, Catholic University, Rome, Italy

Received January 9, 2014 - Accepted January 16, 2015

The purpose of this study was to define the state-of-art regarding the biocompatibility characteristics, *in vivo* and *in vitro*, of some ceramic materials. A comprehensive search in Pubmed, Cochrane and Google Scholar databases was performed. Ceramic materials are made of an inorganic non-metallic oxide. Depending on their *in vivo* behaviour, ceramics are classified as bioresorbable, bioreactive or bioinert. Alumina and zirconia are bioinert ceramics; their low reactivity together with their good mechanical features has led them to be used in many biomedical restorative devices. Their most popular application is in arthroprosthetic joints where they have proven to be very effective, thus making their use suitable especially in younger, more active patients. Also the use of these materials in dentistry was proposed to achieve aesthetic and reliability of dental repairs. Ceramic materials in different physical states (powder and solid) were used to perform *in vitro* tests on cell cultures. *In vitro* assays are influenced by material characteristics, such as the physical state, reactive surface, chemical composition, impurity content etc, as well as by the cell conditions during the tests. Zirconium oxide is also used as a dental restorative material. Ceramic restorations allow an aesthetical outcome more similar to natural teeth than conventional metal-ceramic ones. Zirconia's resilience and its similar colour to teeth have led to the use of this material for different purposes. The most interesting application of this material is nowadays for fixed partial dentures. Mechanical resistance of zirconia FPD was studied on single tooth restorations and on partial dentures. Alumina matrix composites were selected as the best new family of ceramics to provide the foundation for the widespread use of ceramics in orthopedics. Our analysis confirms the role of zirconia and even more of alumina matrix composites as optimal metal-free materials for implant-prosthetic components used in orthopedics, dentistry and other medical areas. Level of Evidence: V - Letter to the Editor

Currently several types of ceramic material are available for clinical use (1), especially in orthopedics, and dentistry as well as in ophthalmic surgery (2).

Ceramic materials are made of an inorganic non-metallic oxide (3). Usually ceramics are divided into two groups: silicon ceramics and aluminous

Key words: Biocompatibility, Zirconia, Ceramic materials, Alumina, Carcinogenicity.

Mailing address: Dr. Antonio Ziranu,
Department of Geriatrics Sciences,
Neuro-Sciences and Orthopaedics Sciences,
Catholic University,
Largo A. Gemelli 8, 00168 Rome, Italy;
Tel: ++39 06 3051161
e-mail: antonioziranu@hotmail.com

1973-6401 (2014) Print

Copyright © by BIOLIFE, s.a.s.
This publication and/or article is for individual use only and may not be further reproduced without written permission from the copyright holder.
Unauthorized reproduction may result in financial and other penalties
DISCLOSURE: ALL AUTHORS REPORT NO CONFLICTS OF INTEREST RELEVANT TO THIS ARTICLE.

ceramics. Ceramics are also divided into crystalline and non-crystalline depending on the inner molecular organization. Depending on their *in vivo* behavior, ceramics are classified as bioresorbable, bioreactive or bioinert (4). Alumina and zirconia are bioinert ceramics; their low reactivity together with their good mechanical features (low wear and high stability) have led to their use in many biomedical restorative devices (5-8). Their most popular application is in arthroprosthetic joints where they have proven to be very effective, making their use suitable especially in younger, more active patients (9). Also the dental use of these materials was proposed to achieve aesthetic and reliability of dental restorations.

More recently Zirconia Toughened Alumina (ZTA) was developed for clinical application.

In this study, *in vivo* tests, *in vitro* tests and clinical applications of these materials have been reviewed, comparing effects of each material in cell cultures, animals and humans.

Biocompatibility

Biocompatibility has been defined as “the ability of a material to perform with an appropriate host response in a specific application”. Reaction of bone, soft collagenous tissues and blood are involved in the host response to ceramic implants. Interfacial reaction between these materials and body tissues both *in vitro* and *in vivo* must be considered evaluating biocompatibility of bioinert ceramics. The low rate of tissue reactions towards alumina are the reason why it is often considered as a reference in testing orthopedic ceramic biomaterials. The first experimental data of solid ceramics (ZrO₂) *in vivo* biocompatibility in orthopedic surgery were published in 1969 by Helmer and Driskell (6) while the first clinical cases on alumina were described later by Boutin (10), shortly followed by Griss (11). *In vitro* biocompatibility evaluations of alumina and zirconia were performed after their clinical use. As biocompatibility tests often report the comparison of alumina and zirconia biocompatibility, we have reviewed the results in the same manner.

In vitro test

Ceramic materials in different physical forms (powders and dense ceramics) were used to perform *in vitro* tests on cell cultures. Many studies have

reported the absence of acute toxic effects of ceramic in powder or disk form on the different cell lines used in tests of both alumina and zirconia. *In vitro* assays are influenced by material characteristics, such as the physical form, reactive surface, chemical composition, impurity content etc, as well as by the cell conditions during the tests. Surface characteristics govern the biocompatibility of the materials (12). Alumina and zirconia disks with 30% of porosity allow adhesion and spreading of 3T3 fibroblasts as observed via SEM (Fig. 1). HUVEC and 3T3 (4) fibroblasts did not show any toxic reaction toward Al₂O₃ or ZrO₂ samples (MTT test on cells in direct contact with ceramic particles); the same effects were also observed on ceramic extracts cocultured with fibroblasts. Li et al. (13) demonstrated that powders were more toxic than dense ceramics, using direct contact tests and MTT tests with human oral fibroblasts. Ceramic powders can induce apoptosis in macrophages depending on material concentration (14). Meboumta (15) et al. reported for the first time a different toxic effect between alumina and zirconia; in particular a higher cytotoxicity of alumina particles compared to the zirconia ones which was measured as human monocyte differentiation. This is probably due to the higher reactive surface of the alumina particles, which are significantly smaller than the zirconia ones. Degidi (16) compared soft tissue reactions to ZrO₂ and titanium; he reported that inflammatory infiltrate, microvessel density and vascular endothelial growth factor expression appeared higher around titanium samples than around ZrO₂ ones. Moreover, cellular proliferation on zirconia surfaces is higher than on titanium ones. Furthermore, Warashima (17) reported less proinflammatory mediators (IL-1-b, IL-6 and TNF-a generated by ZrO₂ than titanium or polyethylene) (18). Biocompatibility is also influenced by particle size. In 1999 Webster demonstrated that osteoblast adhesion increased as nanophase alumina grain size decreased from 177 nm to 23 nm. Subsequently, in 2008 Chanda demonstrated that bigger Alumina grain substrate (12 μm compared to 1 μm) allows a better cell-material interaction in terms of osteoblast cell-attachment, proliferation and differentiation (19-29).

In vivo test

Different physical forms and in different sites

of implantation were evaluated in order to analyse systemic toxicity, adverse reactions of ceramics in soft tissue and/or bone. The work of Helmer and Driskell (6) already cited is the first report of implant in bone of zirconia. Pellets were implanted into a monkey's femur, the Authors observed an apparent bone ingrowth without any adverse tissue reaction. Hulbert et al. (7) implanted porous and non-porous disks and tubes of different ceramics in the paraspinal muscles. The authors observed ingrowth depending on porous size but no signs of systemic toxicity. After subcutis, intramuscular or intraperitoneal and intraarticular introduction of alumina and zirconia powders in rats and/or mice, many authors reported the absence of acute systemic adverse tissue reactions to ceramics; similar results were reported after implantation of bars or pins to paraspinal muscles of rabbits or rats and after the insertion in bone. Bone ceramic interface showed connective tissue presence, progressively transformed in the bone in direct contact with the ceramic. Bortz (21) reported adverse tissue reaction: fibrous tissue in the lumen of zirconia cylinders implanted in dog and rabbit tracheas, and an inflammatory reaction toward ceramic powders inserted into PMMA grooves implanted in rabbit femurs. In any case this inflammatory reaction was lower than the one observed toward CoCr and UHMWPE (22-23).

Carcinogenicity

Griss, et al. in 1973 (11) reported that alumina and zirconia powders did not induce tumors. They analyzed the long term *in vivo* reactions to ceramics. The Ames test, and carcinogenic or mutagenic tests used to study zirconia dishes, confirmed that this bioceramic did not elicit any mutagenic effect *in vitro*. Moreover zirconia radioactivity and its possible carcinogenic effect was also evaluated: radioactivity of the powder depends on the source of ores used in the production of the chemical precursor of the zirconia powders. Only Ryu et al. (24) reported a possible carcinogenic effect of ceramic. They observed association between ceramic and soft tissue sarcoma. Some recent studies have been performed to investigate the carcinogenicity of zirconia toughened alumina. Maccauro et al. (25) showed that ZPTA as well as alumina and zirconia ceramics did not elicit any *in vitro* carcinogenic effects; the same group are

studying the possible carcinogenic effects *in vivo* of ZPTA.

MATERIALS AND METHODS

A comprehensive search of Pubmed, Cochrane and Google Scholar databases was performed, using various combination of the keywords 'biocompatibility', 'zirconia', 'ceramic materials', 'alumina' and 'carcinogenity', over the years 1960-2014. All articles were initially screened for relevance by title and abstract, excluding articles without an abstract. Given the linguistic capabilities of the authors, articles not in English or Italian were excluded.

RESULTS

Several comprehensive reviews on the clinical outcomes of ceramic ball heads for orthopedic devices are available (26). Jenny (8), Caton (27), Oonishi (28) and Hamadouche (29) demonstrated the favourable behaviour of ceramic biomaterials in reducing the wear of arthroprostheses in joints (Table I-II). Clinical trials demonstrated that ceramic-on-ceramic coupling decreased significantly the amount of wear debris (28). Nevertheless, Wroblewski (30) demonstrated that ceramic in association with new generation polyethylene may constitute a significant evolution in arthroplasty (31). This would make ceramics in joints suitable, especially in younger patients (9). The matching of surface roughness, roundness and linearity in the coupling of ceramic tapers with a metal trunnion plays a relevant role on stress distribution and intensity; depending also on cone angle, extent of the contact, friction coefficient between the two surfaces Mismatch in female-to-male taper, e.g. due to the many angles in clinical use, roundness, roughness or linearity errors in the taper, are among the most likely "technological" causes of ceramic ball head failures (32). It should be noted that the mechanical behavior of the ceramic ball heads once installed on the metallic taper, depend not only on the ceramic but also on the material and design of the taper. Besides the "technological" failure initiators, several other precautions are necessary when using ceramic ball heads: avoid third body interposition to the ceramic metal, or ceramic/ceramic interface during surgery (e.g. blood clots, bone chips, PMMA cement debris);

Table I. Selected properties of load bearing bioceramics for medical devices.

PROPERTY	UNIT	ALLUMINA	Y-TZP	ZTA	ZPTA
DENSITY	G/CM ²	3.98	6.08	5.00	4.36
AVERAGE GRAIN SIZE	MM	≤1.8	0.3÷0.5	-	-
BENDING STRENGTH	MPA	>550	1200	900	1150
COMPRESSION STRENGTH	MPA	5000	2200	2900	4700
YOUNG MODULUS	GPA	380	200	285	350
FRACTURE TOUGHNESS KIC	MPAM-1/2	4-5	9	6.9	8.5
MICROHARDNESS	HV	2200	1000-1300	1500	1975

Table II. Orthopedic medical devices made of bioinert ceramics.

THR ball heads
THR ACETABULAR INLAYS
THR CONDYLES
FINGER JOINTS
SPINAL SPACERS
HUMERAL EPIPHYSIS
HIP ENDOPROSTHESES

avoid use of metal mallets when positioning ball heads on the metallic taper (or of alumina inlay in the metal back). Use plastic tools provided by the manufacturer or gently push and rotate by hand; avoid thermal shocks to ball heads (e.g. dip the ceramic in saline to cool it after autoclave sterilization); avoid application of new ceramic ball heads onto stems damaged during revision surgery. A third important aspect to achieve good arthroprosthetic results is the surgical technique: both perfect THR component adaptation and orientation, together with soft tissue tension are required. Special care must be taken with orientation, as edge loading of the socket and impingement on components depend on this parameter. In the past zirconia was much used in orthopedics; about 900,000 zirconia ball heads have been implanted in total hip arthroplasties, although there was much debate regarding the potential radioactivity and

carcinogenicity of the zirconia source. However, after some ball head fractures, zirconia has no longer been used for total hip arthroplasties (33-34). Zirconium oxide is also used as a dental restorative material (3). Inlays, onlays, single crowns, fixed partial dentures, can be created using a ZrO₂ core. Moreover, implant abutment and osteointegrated implant for tooth replacement are available in zirconia-containing ceramic systems (35). Making dental products requires proper designing and successive manufacturing in order to satisfy clinical requirements. However, not only personalized service is needed; accuracy is absolutely mandatory. Misfits greater than 50 µm are considered unacceptable for dental restorations. Mechanical resistance must also be considered. Frameworks with minimal thickness, often less than 1 mm, must be able to sustain chewing stresses. Masticatory load on posterior teeth range from 50N to 250N, while parafunctional behavior such as clenching and bruxism can create loads about 500 and 800N. Zirconia frameworks can bear loads between 800 and 3450N. These values are compatible with restorations on posterior teeth if parafunctional loads are not present and a correct framework design is made. In order to avoid misfit due to shrinkage during sintering, it is possible to obtain zirconia frameworks by milling full-sintered ZrO₂ samples (36). This technique is not influenced by sintering problems because zirconia is already sintered, but it could be influenced by operator's accuracy in using the probe. The CAD/CAM technique is the ultimate opportunity in managing zirconia dental devices

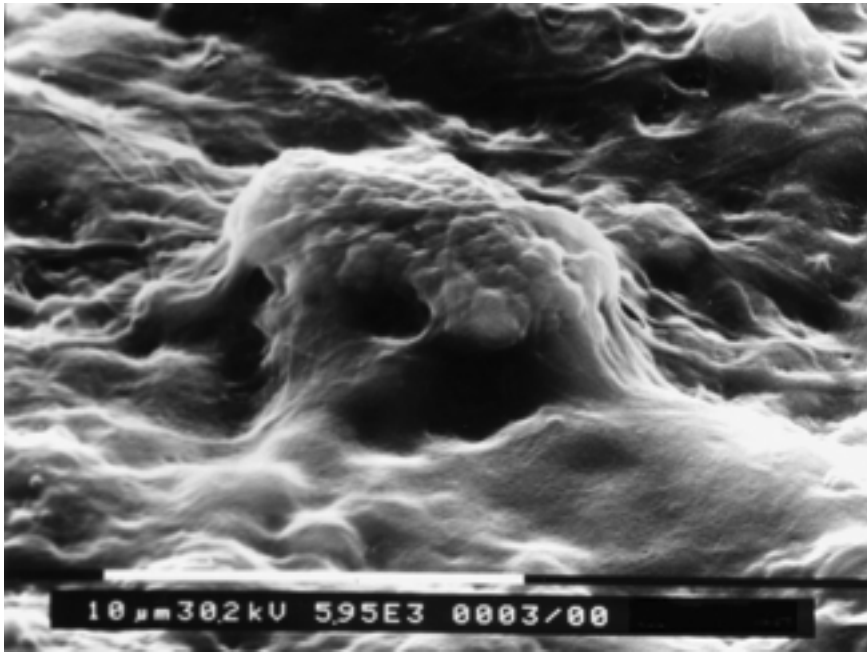


Fig. 1. Scanning electron microscopy (SEM) view of fibroblasts cultured on zirconia: cells grow on the zirconia surface, covering it completely with a cellular layer. A cellular body covered by cytoplasm is discernible (magnification 7400T).

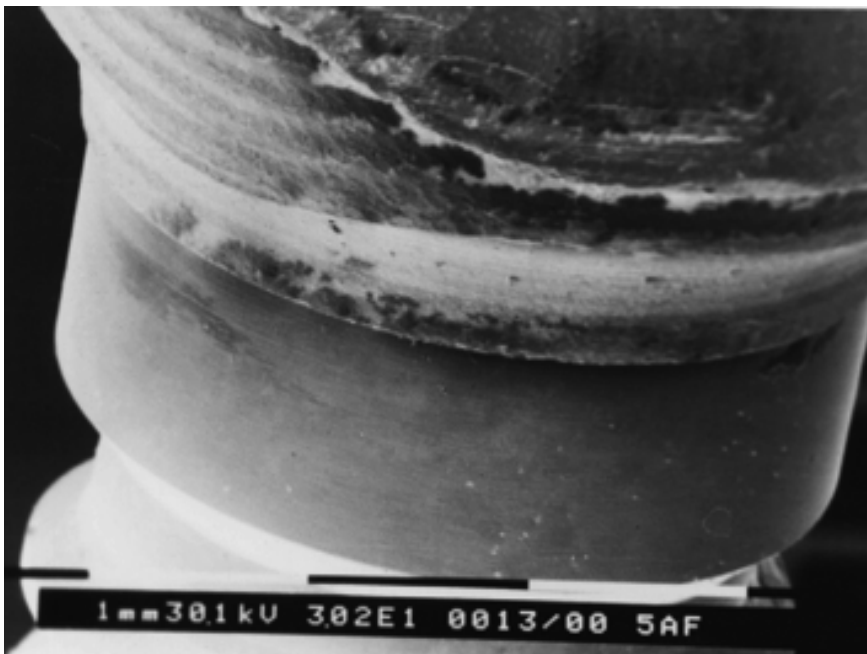


Fig. 2. Scanning electron microscopy (SEM) view of the implant interface between a zirconia CAD-CAM abutment and a fixture with a hexagonal external connection: the zirconia abutment is perfectly fitted and screwed onto the hexagonal implant connection (magnification 30.2T).

production. CAD/CAM is the acronym of Computer Aided Design and of Computer Assisted Manufacturing. This system is composed by a digitizing machine to collect information about teeth position and shape, appropriate software for design zirconia restoration and a computer assisted milling machine that cuts the desired framework from a zirconia sample. This technique reduces human influence, allowing greater accuracy in zirconia core production. Ceramic restorations allow an aesthetical outcome more similar to teeth than conventional metal ceramic ones. Also gingival aesthetics is improved by restoration with a colour similar to teeth, that, together with the mucosal thickness, is the fundamental parameter for an optimal soft tissue color outcome. The toughness and color similar to teeth that zirconia offers, has led to the use of this material for different purposes. Zirconium oxide is used as a reinforcement for endocanal fiber-glass post. Also orthodontic brackets were proposed in ZrO₂. However, the most interesting application of this material is nowadays for fixed partial dentures. Single crowns and 3-5 units FPD are described and studied in literature. The continuative search for an optimal metal-free material for prostheses has found in zirconia an answer to many problems yet to be solved with other ceramic restorations. Also small dental restorations, like inlays and onlays have been proposed using this material. Implant-prothetical components, such as implant abutment are available with zirconia. Osteointegrated implants for tooth replacement are proposed by some manufacturers, but at present there are not enough studies about the behavior of zirconia implants. Zirconia restorations have found their indications for FPDs supported by teeth or implants (24, 37-40). Single tooth restorations are possible on both anterior and posterior elements because of the mechanical reliability of this material. Mechanical resistance of zirconia FPD was studied on single tooth restorations and on partial dentures (Fig. 2). Luthy asserted that zirconia core could fracture with a 706N load. Tinsert reported a fracture loading for ZrO₂ of over 2000N; Sundh measured fracture load between 2700-4100N. zirconia restorations have better fracture resistance than alumina or lithium non-silicate ceramic restorations. Ageing of zirconia can have detrimental effects on its mechanical properties (41). Hence a

new family of ceramic material that would complement alumina ceramic where needed (40). It had to possess the highest possible toughness and the smallest matrix grain size to improve mechanical reliability but this had to be accomplished without sacrificing the wear resistance and chemical stability of current day alumina ceramics. Alumina matrix composites were selected as the best new family of ceramics to provide the foundation for a widespread use of ceramics in orthopedics. The main characteristics of this alumina matrix composite are its two toughening mechanisms. One is given by *in-situ* grown platelets which have a hexagonal structure and are homogeneously dispersed in the microstructure. Their task is to deflect any sub-critical cracks created during the lifetime of the ceramic and to give the entire composite stability. The other important characteristic is related to the addition of 17 vol.-% zirconia nanoparticles that are dispersed homogeneously and individually in the alumina matrix. This increases strength and toughness of the material to levels equal to, and in some cases above those seen in pure zirconia (42). Here, the effect of the tetragonal to monoclinic phase transformation is used as a toughening mechanism. In the case of micro-crack initiation, the local stress triggers phase transformation to the individual zirconia grain which acts then as an obstacle to further crack propagation. It is a desired behavior pattern which uses the volume expansion in an attempt to prevent further crack propagation. Zirconia-Alumina (ZA) ceramics could be associated with bioactive hydroxyapatite. This association increase the biocompatibility of ZA allowing a faster osseointegration and bone regeneration (43-45). Although the occurring of chemical reactions between HA and zirconia reduces mechanical resistance of the final composite, the use of ZA nanocomposite powder decrease the contact area between zirconia and HA, thus maintaining a high mechanical strength (22, 44, 46). Furthermore, it is possible to produce composite materials, called functionally graded materials, in which constituents have a gradual spatial variation of microstructure and relative volume fractions. This characteristic allows the integration of different materials, like hydroxyapatite, ceramics and metals, combining mechanical properties and biocompatibility without

severe internal stress. This group of new materials demonstrates better functional performance in orthopaedics and dentistry applications (1-14, 16, 18, 20-23, 25-27, 29, 32, 35-36, 41, 43-44, 46-48).

DISCUSSION

In the past zirconia was much used in orthopedics (total hip arthroplasties). However, after the observation of some ball head fractures, zirconia has no longer been used. Zirconium oxide is also used as a dental restorative material. Moreover, implant abutment and osteointegrated implants for tooth replacement are also available in zirconia. Ageing of zirconia can have detrimental effects on its mechanical properties. This process can be accelerated by mechanical stresses and wetness exposure. Whereas, ageing on zirconium oxide used for oral rehabilitation is not completely understood. However, an *in vitro* simulation reported that, although ageing leads to the loss of mechanical features, this does not influence resistance under clinically acceptable values. Further evaluations are needed as long-term studies of zirconia behavior have not yet been performed. Alumina matrix composites were selected as the best new family of ceramics to provide the foundation for a widespread use of ceramics in orthopedics. Alumina matrix composite has a unique strength and toughness unattained by any other ceramic material used in structural applications in the human body.

REFERENCES

1. Conrad HJ, Seong W, Pesun IJ. Current ceramic materials and systems with clinical recommendations: a systematic review. *J Prosthet Dent.* 2007; 98(5):389-404.
2. Bairo F, Vitale-Brovarone C. Bioceramics in ophthalmology. *Acta Biomater* 2014; 10:3372-97.
3. Carinci F, Pezzetti F, Volinia S, Francioso F, Arcelli D, Farina E, Piattelli A. Zirconium Oxide: Analysis of mg63 osteoblast-like cell response by means of a microarray technology. *Biomaterials* 2004 ;25:215.
4. Dion I, Bordenave L, Lefebvre F. Physico-chemistry and cytotoxicity of ceramics, Part 2. *J. Mater. Sci. Mater. Med.* 1994; 5:18-24.
5. Heimke G, Leyen S, Willmann G. Knee Arthroplasty: Recently developed ceramics offer new solutions. *Biomaterials* 2002; 23:1539-51.
6. Helmer JD, Driskell TD. Research on bioceramics. Symp. On Use Of Ceramics As Surgical Implants. South Carolina (Usa): Clemson University 1969.
7. Hulbert SF, Morrison SJ, Klavitter JJ. Tissue reaction to three ceramics of porous and non-porous structures. *J Biomed Mater Res* 1972; 6:347-74.
8. Jenny JY, Boeri C, Tavan A, Schlemmer B. Results versus wear couple. *Proc. Société Française Chi Orthop Traumatol* 1997; 11-3.
9. Fenollosa J, Seminario P, Montijano C. Ceramic hip prostheses in young patients - A retrospective study. *Clin Orthop* 2000; 379:55-67.
10. Boutin P. Arthroplastie total de la hanche par prothese on alumine frittee. *Revue chirurgie et Orthopadie* 1972; 58:229-46.
11. Griss P, Von Adrian Werburg HV. Biological activity and histocompatibility of dense AL₂O₃ - MGO ceramics implants in rats. *J Biomed Mater Res* 1973; 7:453-62.
12. Al-Sanabani FA, Madfa AA, Al-Qudaimi NH. Alumina ceramic for dental applications: A review article. *American Journal of Materials Research* 2014; 1:26-34.
13. Li J, Liy Y, Hermansson L, Soremark R. Evaluation of biocompatibility of various ceramic powders with human fibroblasts in vitro. *Clin Mat* 1993; 12:197-201.
14. Catelas I, Petit A, Zukor DJ, Marchand R, Yahia LH, Huk OL. Induction of macrophage apoptosis by ceramic and polyethylene particles in vitro. *Biomaterials* 1999; 20:625-30.
15. Meboumta NE, Adnet JJ, Bernard J. In vitro effects of zirconia and alumina particles on human blood monocyte-derived macrophages: X-Ray microanalysis and flow cytometric studies. *J Biomed Mater Res* 2000; 52:587-94.
16. Degidi M, Artese M, Scarano A, Pernotti V, Gehrke P, Piattelli A. Inflammatory infiltrate, microvessel density, nitric oxide synthase expression, vascular endothelial growth factor expression, and proliferative activity in peri-implant soft tissues around titanium and zirconium oxide healing caps. *J Periodont* 2006; 77:73-80.
17. Warashina H, Sakano S, Kitamura S, Yamauchi Ki, Yamaguchi J, Ishiguro N, Hasegawa Y.

- Biological reaction to alumina, zirconia, titanium and polyethylene particles implanted onto murine calvaria. *Biomaterials* 2003; 24:3655-61.
18. Covacci V, Bruzzese N, Maccauro G. In vitro evaluation of the mutagenic and carcinogenic power of high purity zirconia ceramics. *Biomaterials* 1999; 20:371-6.
 19. Webster TJ, Siegel RW, Bizios R. Design and evaluation of nanophase alumina for orthopaedic/dental applications. *Nanostructured Materials* 1999; 12:983-6.
 20. Chanda A, SinghaRoy R, Xue W, Bose S, Bandyopadhyay A. Bone cell-materials interaction on alumina ceramics with different grain sizes. *Materials Science and Engineering:C* 2009; 29:1201-6.
 21. Bortz SA, Onesto EJ. Flame sprayed bioceramics. *Cer Bull* 1973; 52:898.
 22. Kubo T, Hirasawa Y. Histiocyte reaction in rabbit femurs to UHMWPE, metal, and ceramic particles in different sizes. *J Biomed Mat Res* 1999; 45:363-9.
 23. Maccauro G, Cittadini A, Magnani G, Sangiorgi S, Muratori F, Manicone PF, Rossi Iommetti P, Marotta D, Chierichini A, Raffaelli L, Sgambato A. In vivo characterization of zirconia toughened alumina material: a comparative animal study. *Int J Immunopathol Pharmacol* 2010; 23:841-6.
 24. Ryu RK, Bovill EG, Skinner HB. Soft tissue sarcoma associated with aluminium oxide ceramic total hip arthroplasty. A case report. *Clin. Orthop.* 1987; 216:207-12.
 25. Maccauro G, Bianchino G, Sangiorgi S, Magnani G, Marotta D, Manicone PF, Raffaelli L, Rossi Iommetti P, Stewart A, Cittadini A, Sgambato A. Development of A new zirconia-toughened alumina: promising mechanical properties and absence of in vitro carcinogenicity. *Int J Immunopathol Pharmacol* 2009; 22:773-9.
 26. Maccauro G, Piconi C, Burger W. Fracture of a y-tzpceramic femoral head. Analysis of a fault. *J Bone Joint Surg Br* 2004; 86:1192-6.
 27. Caton J, Bouraly YP. Zirconia UHMWPE articulation using 22,3 mm dia. Femoral heads. Workshop on zirconia femoral heads in total hip prostheses. 6th world biomaterials congress, May 2000, Paper 9.
 28. Oonishi H, Amino H, Ueno M, Yunoki K. Concepts and design with ceramics for total hip and knee replacement. Reliability and long term results of ceramics in orthopedics. *Thieme Publ* 1999; 1:7-28.
 29. Hamadouche M, Sedel L. Alumina-on-alumina total hip arthroplasties. *J Bone Joint Surg* 2000; 82:901-9.
 30. Wroblewski BM, Fleming PA. Low-friction arthroplasty of the hip using alumina ceramic and cross linked polyethylene. *J Bone Joint Surg* 1999; 81:54-5.
 31. Mendes DG, Said M, Zukerman V. Ten rules of technique for ceramic bearing surfaces in total hip arthroplasty. *Bioceramics in total hip joint replacement.* 2002.
 32. Kingery WD, Bowen HK, Uhlmann DR. Introduction to ceramics. *John Wiley Publ.* USA 1960.
 33. Piconi C, Burger W, Richter HG, Cittadini A, Maccauro G, Covacci V, Bruzzese N, Ricci GA, Marmo E. Y-tzp ceramics for artificial joint replacements. *Biomaterials* 1998; 19:1489-94.
 34. Piconi C, Maccauro G. Zirconia as a ceramic biomaterial. *Biomaterials* 1999; 20:1-25.
 35. Madfa AA, Al-Sanabani FA, Al-Qudami NH, Al-Sanabani JS, Amran AG. Use of Zirconia in dentistry: an overview. *The Open Biomaterials Journal* 2014; 5:1-9.
 36. Manicone PF, Rossi Iommetti P, Raffaelli L. An overview of zirconia ceramics: basic properties and clinical applications. *J Dent* 2007; 35:819-26.
 37. Raffaelli L, Rossi Iommetti P, Piccioni E, Toesca A, Serini S, Resci F, Missori M, De Spirito M, Manicone PF, Calviello G. Growth, viability, adhesion potential, and fibronectin expression in fibroblasts cultured on zirconia or feldspatic ceramics in vitro. *J Biomed Mater Res A* 2008; 86:959-68.
 38. Salomoni A, Tucci A, Esposito L, Stamenkovich I. Forming and sintering of multiphase bioceramics. *J Mater Sci Mater Med* 1994; 5:651-3.
 39. Sato T, Shimada M. Control of the tetragonal-to-monoclinic phase transformation of yttria partially stabilized zirconia in hot water. *J Mater Sci* 1985; 20:3899-992.
 40. Swab JJ. Low temperature degradation of y-tzp materials. *J Mater Sci* 1991; 26:6706-14.
 41. Maccauro G, Rossi Iommetti P, Raffaelli L, Manicone PF. Alumina and Zirconia ceramic for orthopaedic and dental devices. In: Pignatello R (ed.). *Biomaterials applications for nanomedicine.*

- InTech, 2011, p. 299-308.
42. Vigolo P, Fonzi F, Majzoub Z, Cordioli G. An in vitro evaluation of titanium, zirconia, and alumina procera abutments with hexagonal connection. *International Journal Of Oral Maxillofacial Implants* 2006; 21:575-80.
 43. Harada Y. Experimental studies of healing process on compound blocks of hydroxyapatite particles and tricalcium phosphate powder implantation in rabbit mandible. *J Tokyo Dent College Soc* 1989; 89:263-97.
 44. Kong YM, Bae CJ, Lee SH, Kim HW, Kim HE. Improvement in biocompatibility of ZrO₂-Al₂O₃ nano-composite by addition of HA. *Biomaterials*. 2005; 26:509-17.
 45. Monma H. Tricalcium phosphate ceramics complexed with hydroxyapatite. *J Ceram Soc Jpn* 1987; 96:60-4.
 46. Li J, Hastings GW. Oxide bioceramics: inert ceramic materials in medicine and dentistry. In: Black J, Hastings GW, editors. *Handbook of biomaterials properties*. London: Chapman & Hall; 1998. p. 340-54.
 47. Al-Sanabani J, Madfa AA, Al-Sanabani FA. Application of calcium phosphate materials in dentistry. *Int J Biomater* 2013 vol. 2013, Article ID 876132, 12 pages, 2013. doi:10.1155/2013/876132.
 48. Manjubala I, Sastry TP. Structural and morphological analysis of functionally graded calcium phosphate bioceramic. *Key Engineering Materials* 2001; 218:89-9234.

BIOLOGICAL STUDY

PROTEASE ACTIVITIES IN SYNOVIAL FLUIDS FROM PATIENTS SUFFERING FROM PIGMENTED VILLONODULAR SYNOVITIS: COULD NIMESULIDE THERAPY REDUCE MATRIX METALLOPROTEINASE ACTIVATION?

P. RUGGERI¹, G. MAROLDA², A. IANNI¹ and N. FRANCESCHINI¹

¹*Department of Biotechnological and Applied Clinical Sciences, University of L'Aquila, L'Aquila;*

²*Regina Elena National Cancer Institute, Orthopaedic Division, Rome, Italy.*

Received July 23, 2014 - Accepted September 15, 2014

The aim of this study was to investigate the presence and the activity of matrix metalloproteinases, as well as the expression of TIMP-1, in synovial fluids drawn from two patients suffering from pigmented villonodular synovitis, one of whom was treated with the nonsteroidal antiinflammatory drug nimesulide. Synovial fluids were aspirated and collected before the surgical treatment; afterwards, gelatin zymography, Western blot analysis and an ELISA determination of matrix metalloproteinases 3 and 13 were performed. Samples showed the same pattern of proteases, characterised by the presence of matrix metalloproteinases 1, 2, 3, 9 and 13, with a marked decrease of total activity in the case of the patient under treatment with nimesulide. Based on the results obtained through Western blot, the amount of TIMP-1 as well as MMP-1 seems to be similar in both cases. This study confirms that high levels of different proteases are associated to the cartilage degradation in pigmented villonodular synovitis. The mechanism by which nimesulide seems to interfere with the activation of matrix metalloproteinases zymogen could be an interesting field worthy of further investigation. Biological study.

Pigmented Villonodular Synovitis (PVNS) is a rare (1.8 cases per million population) benign proliferative disorder of synovial membrane, characterised by the formation of villi and nodules, with deposition of hemosiderin (1-2). Histologically, PVNS can be characterised by a proliferation of mononuclear synovial cells, scattered osteoclast-like giant cells, an accompanying lymphocytic infiltrate with focal accumulation of lipid-loaded macrophages and deposits of iron pigment (3-4). Different authors report that TNF α could explain the presence of significant amounts of degradative enzymes, such as matrix metalloproteinases (MMPs) and also cathepsins, that are associated with the progressive

destruction of cartilage of affected joints (5-7). This observation prompted some clinicians to investigate the role of a monoclonal anti-TNF α antibody, namely infliximab, as a therapeutic agent to be used in some refractory PVNS (8-9). At present, the gold-standard treatment is surgical excision. Sometimes arthroscopic synovectomy provides partial relief in patients affected by knee PVNS. Nevertheless, this treatment exposes patients to relapse events due to the proliferative nature of this pathology.

Two clinical cases of knee PVNS with extended synovitis are reported in this study. One of the patients assumed nimesulide (200 mg/die) for one month, while the other did not receive any treatment.

Key words: matrix metalloproteinases, synovial fluid, pigmented villonodular synovitis, nimesulide

Mailing Address:

Prof. Nicola Franceschini,
Dept. of Clinical, Applied and Biotechnological Sciences,
University of L'Aquila, L'Aquila, Italy,
Via Vetoio, 67100,
Tel: +39-0862-433456 Fax +39-0862-433433
e-mail: nicola.franceschini@cc.univaq.it

1973-6401 (2014) Print

Copyright © by BIOLIFE, s.a.s.
This publication and/or article is for individual use only and may not be further reproduced without written permission from the copyright holder.
Unauthorized reproduction may result in financial and other penalties
DISCLOSURE: ALL AUTHORS REPORT NO CONFLICTS OF INTEREST RELEVANT TO THIS ARTICLE.

Synovial fluids from both patients were used as biological sources of proteases. As previously reported by Dieppe PA et al. (10), synovial fluid represents an optimal source to detect different collagenolytic or neutral proteolytic activities (11). The usefulness of synovial fluids to determine a broad MMPs activity in a comparative analysis between local and systemic level has also been widely confirmed by Tchetcherichov et al. (12). This is the first report that investigates the presence and the possible role of MMPs in synovial fluids from patients suffering from PVNS, as well as the potential protective function of nimesulide, a non-steroidal anti-inflammatory drug (NSAID) with analgesic, anti-inflammatory and antipyretic properties, that could act on MMP expression, activation and function.

PATIENTS AND METHODS

Patients

The first patient (case 1) was a 46-year-old man with a 1 year history of left knee pain. He presented a palpable soft tissue mass arising from anterolateral aspect of the knee. He had no history of previous traumas. Upon physical examination, pain could be elicited by palpating the apex and the lateral aspect of the patella. The Magnetic Resonance Imaging (MRI) obtained before surgery revealed the presence of a mass in the lateral compartment of the knee which crossed over the lateral condyle. By arthroscopy, a yellow pedunculated mass was found and excised. The synovial layer surrounding the lesion appeared hypertrophic with villous expansions. The villous-like synovial layer was also excised during the arthroscopic procedure. All other structures were found without defects. Microscopic examination confirmed the diagnosis of PVNS.

The second patient (case 2) was a 30-year-old man hospitalised during the same period as case 1. This patient reported a 5-year history of anterior right knee pain. After a long period of rest and repeated courses of anti-inflammatory medication, he still complained that the pain was worse when he tried to kneel down and reported repeated episodes of swelling of the knee. The examining physician could easily feel a “pop” when holding his fingers on the medial joint while moving the knee from flexion

to full extension. The same sensation was reported by the patient who experienced it without pain. The preoperative MRI of the knee revealed the presence of a well-circumscribed mass contouring the medial femoral condyle. By arthroscopy a pedunculated brownish mass between the medial femoral condyle and the fat pad could be noted. The mass was resected and partial synovectomy was performed all around the insertion of the lesion. The histological examination confirmed the intraoperative diagnosis of localised PVNS. This patient had been under therapeutic treatment (nimesulide 200 mg/die) for one month.

Synovial fluid (SF) sample collection

Patients gave informed consent for their synovial fluids to be studied. The SFs were aspirated from the knee joint before the surgery treatment and, immediately after aspiration, they were stored at -80°C until further use. Prior to assay, samples were thawed and treated with hyaluronidase at a final concentration of 30 U/ml for 1h at 30°C to reduce viscosity.

Matrix metalloproteinase zymography analysis

Gelatin zymography was performed using 10% SDS-PAGE containing 0.3 mg/ml type B gelatin (Sigma-Aldrich, Milan, Italy). Samples were diluted in a non-reducing sample buffer without heating. After electrophoresis, the gel was incubated for one hour in a renaturation buffer (50 mM Tris-HCl pH 8, containing 2.5% Triton X-100) to remove SDS. At a later stage the gel was incubated for 24 hours in a developer buffer (50 mM Tris-HCl pH 8, containing 5 mM CaCl₂, 200 mM NaCl and 0.02% Brij35) to allow enzyme renaturation. The gel was then stained in a 0.1% solution of Coomassie Blue R250 in 40% (v/v) methanol and 10% (v/v) acetic acid followed by extensive destaining in the same solution without dye. Spots quantitative analysis was carried out using ImageJ software (13).

Western blot analysis

Synovial fluid samples were resolved by 10% SDS-PAGE under reducing conditions. After separation, proteins were blotted onto polyvinylidene difluoride transfer membranes (PVDF). The membranes were then blocked 1 hour with a

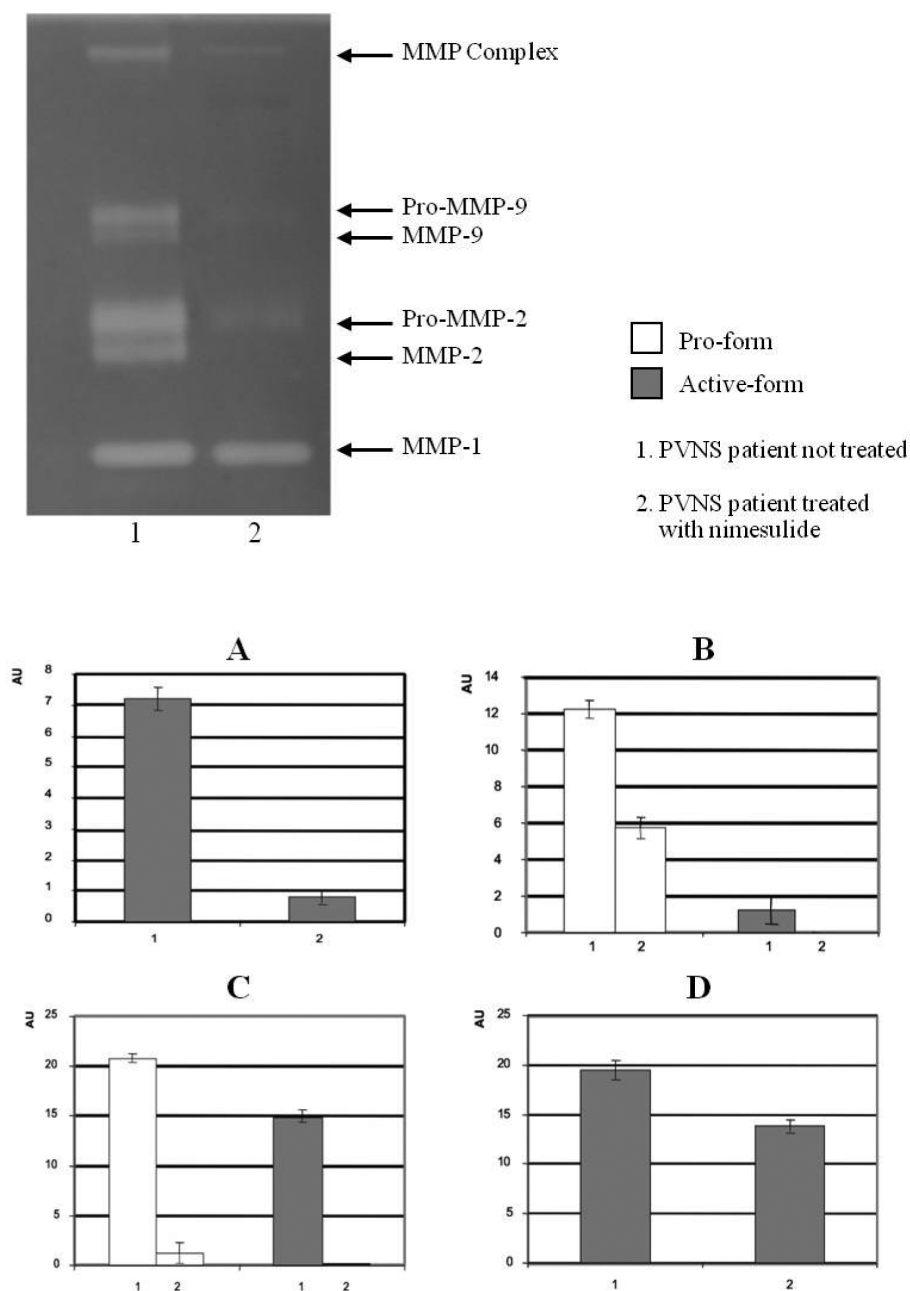


Fig. 1. Zymographic analysis of MMPs activity. Samples were standardized according to the protein content, and untreated patient (1) and treated patient (2) were analysed as reported in methods. Empty or filled bars represent respectively zymogen or the activated form of the respective enzymes. MMP complex proMMP-9/MMP-9 proMMP-2/MMP-2 MMP-1. All data are expressed as mean \pm S.D. Significance was set at $P < 0.05$.

solution containing 5% non-fat dry milk (Biorad, Milan, Italy) in TBS containing 0.1% Tween 20 (TBS-T) and then incubated overnight at 4°C with the specific antibody mixed to 1% non-fat dry milk in TBS-T; in particular antibodies anti-hMMP-1,

anti-hMMP-2, anti-hMMP-3, anti-hMMP-9 and anti-hTIMP-1 were used. After a short rinsing with TBS-T, the membranes were incubated for one hour at room temperature with HRP conjugated antibodies (1:10000) from rabbit or mouse as appropriate. The

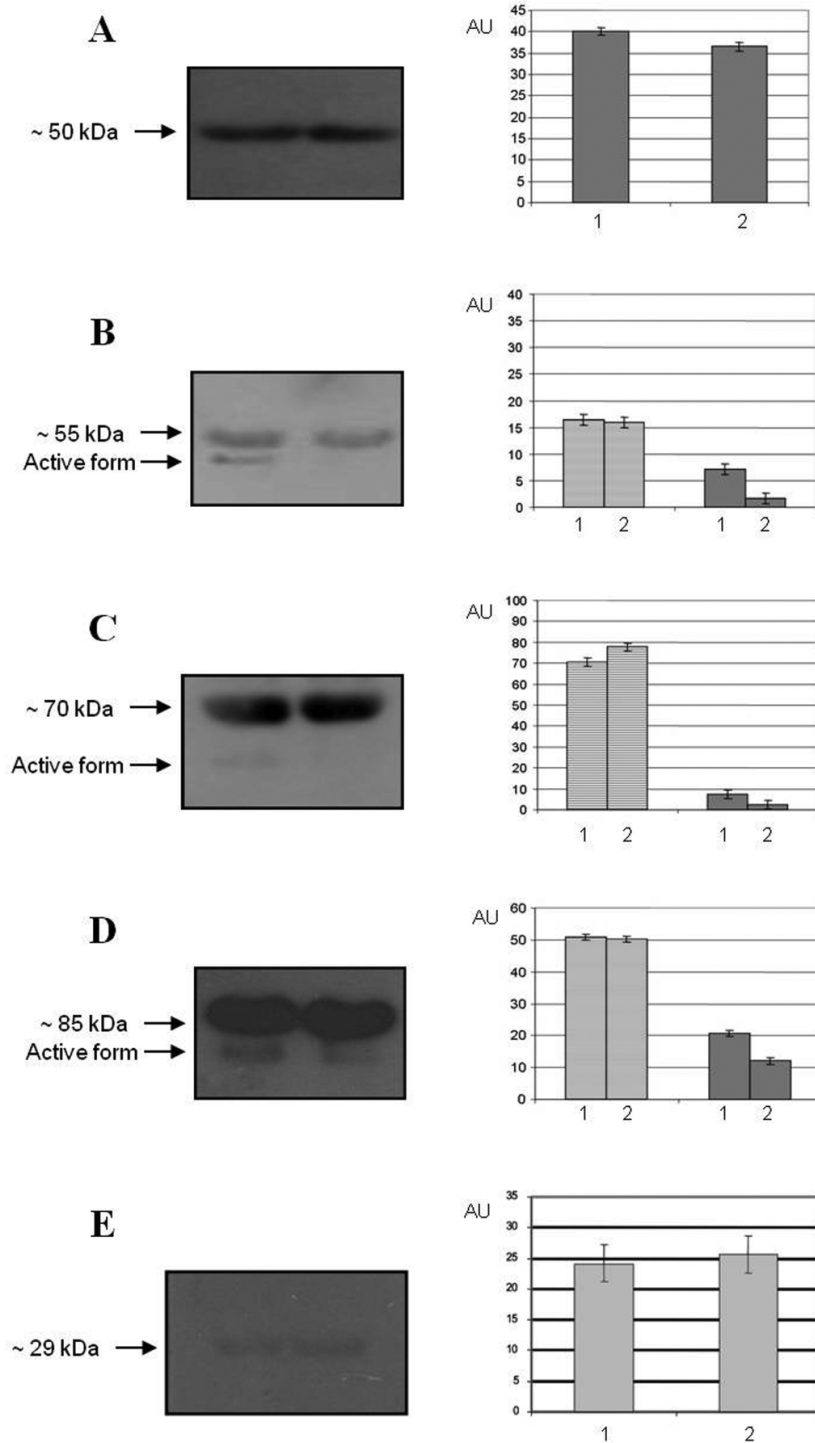


Fig. 2. Western blotting analysis of MMPs and TIMP-1 expression. 1. PVNS patient not treated 2. PVNS patient treated with nimesulide A. MMP-1 B. MMP-3 C. MMP-2 D. MMP-9 E. TIMP-1 All data are expressed as mean \pm S.D. Significance was set at $P < 0.05$. MMP-1, 2, 3, 9 and TIMP-1 were quantified as reported in panel A, B, C, D and E.

immunoreactive bands were visualized using the ECL chemiluminescent reagent (GE Healthcare, Little Chalfont, England). Molecular weight standard Chemicon western control, primary antibodies and HRP-coniugated antibodies were purchased by Sigma-Aldrich (Milan, Italy).

MMP-3 and MMP-13 ELISA determination

MMP-3 and MMP-13 content was measured using 50 µl of synovial fluids with the respective instant Elisa kit (Bender MedSystems, USA). Experiments were performed according to the manufacturer's protocol.

Statistical analysis

Statistical analysis of data was carried out by the Student's *t*-test. All numerical data are expressed as mean ± SD of at least three different experiments. Statistical significance was set at $p < 0.05$.

RESULTS

Zymographic analysis of MMP content, as reported in fig. 1, showed a complex pattern of MMP activities. Both MMP-2 and MMP-9 are present as zymogen and active form and an intense band corresponding to the activated MMP-1 is present in both samples and expressed at the same level. The active forms of MMP-2 and MMP-9 are present in the SF of the patient who did not undergo treatment but are scarcely represented in the one drawn from the patient treated with nimesulide.

Western blotting analysis, as reported in fig. 2, confirmed the presence of MMP-1, MMP-3, MMP-2, MMP-9 and TIMP-1. TIMP-1 (fig. 2, panel E) and MMP-1 (fig. 2, panel A) levels showed similar results for both samples, confirming, at least for MMP-1, the zymographic finding. Interestingly, in synovial fluid drawn from the treated patient, the absence of the active forms of MMP-2 and MMP-9 is confirmed (fig. 2, panels C and D); this behaviour seems well defined for the MMP-3 (fig. 2, panel B).

The different content of MMP-3, 350 and 270 ng/ml respectively in the untreated and the treated patient, was confirmed also by the ELISA technique; the same approach allowed the MMP-13 content of 140 ng/ml in the SF in the untreated patient, and undetectable levels in the sample drawn from the patient treated

with nimesulide, to be evaluated and estimated.

DISCUSSION

Synovial fluids from PVNS patients showed a very interesting aspect worthy of being investigated in order to establish the presence of different protease activities responsible for bone and cartilage degradation. Both fluids were characterised by the contemporaneous presence of matrix metalloproteinases able to destroy the fibrillar collagen as well as other components of the extracellular matrix; if we consider the probable presence of other proteolytic enzymes, such as cathepsins, it is quite evident that the aggressivity towards cartilage and subchondral bone of some PVNS forms is of fundamental importance. Moreover, the proteolytic potential showed a very different aspect between the two samples, surprisingly confirming that nimesulide, a nonsteroidal anti-inflammatory drug, could play a pivotal role in the modulation of MMP zymogen activation and in the regulation of the enzyme specific activity. In particular, the drug's ability to down-regulate the production of MMP-3 and MMP-13 that are involved in proMMP activation as well as in the digestion of different components of the extracellular matrix should be emphasized. This behaviour was previously reported by Barracchini et al. (14), whose studies evidenced the nimesulide ability to reduce MMP-3 activity and reverse the balance between IL-6 and IL-10 in synovial fluids drawn from patients suffering from osteoarthritis.

This finding could be the subject of more efforts to understand the relationship between NSAID specific treatment and the different proteolytic pattern observed in synovial fluids. The action of NSAIDs onto potential non-specific targets or their contribution to the discovery of new compounds with inhibitory activity is still to be ascertained.

ACKNOWLEDGEMENTS

We wish to thank the Italian Ministry of Instruction, University and Research (MIUR) for its support in this research.

REFERENCES

1. Durr HR, Stabler A, Maier M, Refior HJ. Pigmented

- villonodular synovitis, review of 20 cases. *J Rheumatol* 2001; 28:1620-1630.
2. Barile A, Sabatini M, Iannessi F, Di Cesare E, Splendiani A, Calvisi V, Masciocchi C. La sinovite pigmentaria villonodulare (PVNS) del ginocchio. Valutazione con Risonanza Magnetica (RM) ed impiego del mdc paramagnetico standard e dinamico di 52 casi. *Radiol Med* 2004; 107:356-366.
 3. Weiss SW, Goldblum JR. Malignant giant cell tumor of the tendon sheath/pigmented villonodular synovitis. In *Soft Tissue Tumors*. S.E. Weiss, J.R. Goldblum, eds. St Louis, Mosby 2001; 1046-1054.
 4. Berger I, Rieker R, Ehemann V, Schmitz W, Autschbach F, Weckauf H. Analysis of chromosomal imbalances by comparative genomic hybridisation of pigmented villonodular synovitis. *Cancer Letters* 2005; 220:231-236.
 5. Yoshihara Y, Nakamura H, Obata K, Yamada H, Hayakawa T, Fujikawa K, Okada Y. Matrix metalloproteinases and tissue inhibitors of metalloproteinases in synovial fluids from patients with rheumatoid arthritis or osteoarthritis. *Ann Rheum Dis* 2000; 59:455-456.
 6. Kontinen YT, Ainola M, Valleala H, Ma J, Ida H, Mandelin J, Kinne RW, Santavirta S, Sorsa T, Otin CL, Takagi M. Analysis of 16 different matrix metalloproteinases (MMP-1 to MMP-20) in the synovial membrane: different profiles in trauma and rheumatoid arthritis. *Ann Rheum Dis* 1999; 58:691-697.
 7. Uchibori M, Nishida Y, Tabata I, Sugiura H, Nakashima H, Yamada Y, Ishiguro N. Expression of matrix metalloproteinases and tissue inhibitors of metalloproteinases in pigmented villonodular synovitis suggests their potential role for joint destruction. *J Rheumatol* 2004; 31:110-119.
 8. Kroon EJ, Smeets TJ, Maas M, Tak PP, Wouters JM. Tumor necrosis factor alpha blockade in therapy-resistant pigmented villonodular synovitis. *Ann Rheum Dis* 2005; 64:497-499.
 9. Fiocco U, Sfriso P, Oliviero F, Sovran F, Scagliori E, Pagnin E, Vezzù M, Cozzi L, Botsios C, Nardacchione R, Di Maggio A, Rubaltelli L, Giacometti C, Calabrese F, Todesco S. Intra-articular etanercept treatment for severe diffuse pigmented villonodular knee synovitis. *Reumatismo* 2006; 58:268-274.
 10. Dieppe PA, Cawston T, Mercer E, Campion GV, Hornby J, Hutton CW, Doherty M, Watt I, Woolf AD, Hazleman B. Synovial fluid collagenase in patients with destructive arthritis of shoulder joint. *Arthritis Rheum* 1988; 31:882-890.
 11. Cawston TE, Mercer E, De Silva M, Hazleman BL. Metalloproteinases and collagenase inhibitors in rheumatoid synovial fluid. *Arthritis Rheum* 1984; 27:285-290.
 12. Tchvetnikov I, Ronday HK, Van El B, Kiers GH, Verzijl N, Tekoppele JM, Huizinga TWJ, DeGroot J, Hanemaaijer R. MMP profile in paired serum and synovial fluid samples of patients with rheumatoid arthritis. *Ann Rheum Dis* 2004; 63:881-883.
 13. Image Processing and Analysis in Java (Rasband W.S., ImageJ, National Institute of Health, Bethesda, Maryland, USA), <http://rsb.info.nih.gov/ij/> (1997-2004).
 14. Barracchini A, Minisola G, Amicosante G, Oratore A, Pantaleoni GC, Franceschini N. MMPs activities and cytokine expression during nimesulide therapy in a patient affected by osteoarthritis. *Curr Opin Clin Exp Res* 2001; 3:156-160.