

Review

CLINICAL AND RADIOLOGICAL RESULTS OF SEVERE ACETABULAR BONE DEFECTS IN REVISION TOTAL HIP ARTHROPLASTY USING MODULAR POROUS METAL COMPONENTS: A NARRATIVE REVIEW

S. Rizzo¹, M. Grasso¹, A. Benedetto¹, M. Smaldino¹, G. Solarino¹ and A. Panella²

¹University of Bari “Aldo Moro”- AOU Policlinico Consorziale, Department of Translational Biomedicine and Neuroscience, Orthopaedic and Trauma Unit, Bari, Italy;

²Orthopaedics Unit, Don Tonino Bello Hospital, Molfetta, Italy

Correspondence to:

Stefano Rizzo, MD

School of Medicine,

University of Bari “Aldo Moro”- AOU Policlinico Consorziale,

Department of Translational Biomedicine and Neuroscience,

Orthopaedic and Trauma Unit Policlinico,

Piazza Giulio Cesare 11,

Bari 70124, Italy

e-mail: dr.stefanorizzo@gmail.com

ABSTRACT

The incidence of total hip arthroplasty (THA) revisions is expected to rise significantly in the future, due to the population's greater life expectancy and the decreasing age of patients undergoing primary THA. Several alternative surgical techniques have been suggested depending on the extent and kind of acetabular bone loss. The aim of this review is to analyze the clinical and radiological mid-term and long-term outcomes of Paprosky II and III acetabular bone defects treated with modular porous metal components and their survivorship rate. We reviewed 15 articles in the literature based on the treatment of acetabular revisions. The literature review was conducted using electronic databases from their dates of inception. In severe acetabular bone defects, especially those classified as Paprosky II e III, metallic materials are proposed for their biomechanical properties to ensure primary fixation by a roughness effect. Modular porous metal components represent a promising type of implant, but the literature is controversial, and few articles show mid-term follow-up. The studies reviewed demonstrate an excellent result in follow-up but also reported complications and limitations; therefore, the use of certain implants and specific surgical techniques must be performed according to the severity of the bone loss and the patient's clinical conditions.

KEYWORDS: *total hip arthroplasty, revision, bone defect, trabecular metal, Paprosky*

INTRODUCTION

The incidence of total hip arthroplasty (THA) revisions is expected to rise significantly in the future, due to a greater life expectancy of the population and the age of patients undergoing primary THA. By 2030, there will be a 174% increase in THA procedures in the U.S. (1).

The most frequent cause of acetabular revisions is symptomatic aseptic loosening due to fixation failure and

Received: 15 June 2023
Accepted: 2 August 2023

Copyright © by LAB srl 2023

This publication and/or article is for individual use only and may not be further reproduced without written permission from the copyright holder. Unauthorized reproduction may result in financial and other penalties. Disclosure: All authors report no conflicts of interest relevant to this article.

osteolysis; infection and instability represent less frequent reasons (2). Acetabular bone defects are the most popular reasons for revision THA and could be a technically demanding and surgical challenge for orthopaedic surgeons.

Depending on the extent and type of acetabular bone loss, several alternative therapeutic methods have been suggested: uncemented hemispherical cups, structural allografts, impaction bone grafting (IBG), antiprostusio cages, reinforcement rings or cages with allograft, oblong cups, trabecular metal (T.M.) augments and shells, titanium porous-coated acetabular shell, cup-cage constructs, saddle prosthesis, and custom-made triflange components (3, 4). In several recent studies, some authors prove the effectiveness of managing major acetabular bone loss with custom-made options and modular solutions characterized by the combination of T.M. or titanium prosthetic components (5). T.M., like titanium, is safe in terms of biocompatibility, shares native bone's biomechanical properties, and both facilitate bone ingrowth (6, 7).

This review of the current literature aims to analyze the clinical and radiological mid-term and long-term outcomes of Paprosky II and III acetabular bone defects treated with modular porous metal components and their survivorship rate. Consequently, we reviewed 15 articles of the literature on the treatment of revision THA.

METHODS

Because of the rarity of the case reported here, this article begins with a review of the literature focusing on revision THA in Paprosky type II and III acetabular bone defects using modular porous metal components. The preferred reporting items for systematic reviews and meta-analyses (PRISMA) guidelines were followed (8).

Literature and database searches

Two researchers (S.R. and M.S.) independently searched three databases – PubMed, the Cochrane Library, and Google Scholar – for the keywords “total hip arthroplasty”, “revision”, “bone defect”, and “trabecular metal”. A third researcher (M.G.) independently verified the number of articles identified to avoid potential discrepancies (Table I).

Table I. *The search strategy summary*

Items	Specification
Date of Search (specified to date, month and year)	January 2 nd 2023
Databases and other sources searched	PubMed, the Cochrane Library, and Google Scholar
Search terms used	total hip arthroplasty; revision; bone defect; trabecular metal; Paprosky
Timeframe	From January 2005 until January 2022
Inclusion and exclusion criteria	<p>The inclusion criteria were:</p> <ul style="list-style-type: none"> • Human studies that considered different postoperative complications; • Studies written in English. The <p>Exclusion criteria were:</p> <ul style="list-style-type: none"> • Articles published before 2004 or after the end of 2022; • Cadaveric and biomechanical studies; • Paprosky Type I bone defects • Paprosky Type IV bone defects and/or pelvic discontinuity; • Non porous metal implants; • Studies that did not report complications.
Selection process	<p>Two non-blinded authors reviewed the titles and abstracts of each article identified in the literature search. If a study met all the criteria or the abstract did not provide enough information to include or exclude the report, full texts were obtained, reviewed and considered for data extraction.</p> <p>Whenever an agreement about study inclusion could not be resolved by consensus between the two reviewers, a third author decided about the inclusion</p>

Data extraction

Several articles were excluded after reviewing the titles and abstracts. The remaining articles extracted data regarding Paprosky type II and III acetabular bone defects and use of modular porous metal components. The following data were

extracted (when reported): authors and year of publication, type of study and level of evidence, number of patients enrolled and mean follow-up, type and timing of complications, surgery technique, clinical and radiological outcomes, and percentage of survivorship of the implants.

RESULTS

A total of 3482 articles were identified in the following databases: PubMed (92), Cochrane (0) and Google Scholar (3390). Titles and abstracts were screened, 3462 articles were excluded, including 86 duplicates and 3376 articles that did not meet the inclusion criteria. The full text of 20 articles was reviewed, and 15 studies were included in the final meta-analysis (Fig. 1). These articles were published between 2015 and 2021. The characteristics of the included studies are summarized in Table II.

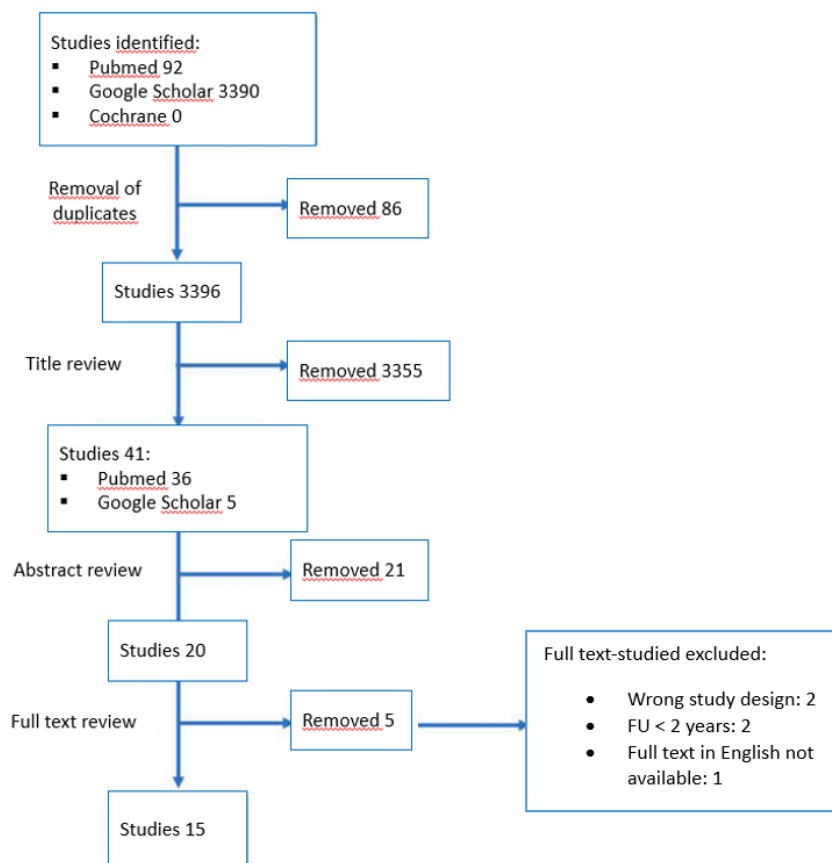


Fig. 1. Prisma flow chart.

Table II. Characteristics of the included studies.

Authors	Year	Material of implants	N of Patients Enrolled	Type of defect (Paprosky)	Mean follow-up (months)
Russell et al.	2020	Tantalum	38	29 (76.3%) Type IIIA 9 (23.7%) Type IIIB	87,6 (range 64,8-129,6)
Perticarini et al.	2021	Trabecular Titanium	95	23 (24,2%) Type IIA 17 (17,9%) Type IIB 13 (13,8%) Type IIC 22 (23,1%) Type IIIA 20 (21,0%) Type IIIB	91 (range 24–146)
Loppini et al.	2018	Tantalum	16	7 (43,75%) Type IIIA 9 (56,25%) Type IIIB	34 (range 24–72)
Grappiolo et al.	2015	Tantalum	54 (55 hips)	42 (76,36%) Type IIIA 13 (23,63%) Type IIIB	53.7 (range 36–91)

Eachempati et al.	2018	Tantalum	41	36 Type IIIA (87.8%), 5 Type IIIB (12.2%)	39.4 (range 24–96)
De Meo et al.	2018	Trabecular Titanium	58	25 Type IIB (39%), 15 Type IIC (23.4%), 15 Type IIIA (23.4%) 9 Type IIIB (14.1%)	48.3 (range 38–82)
Jenkins et al.	2017	Tantalum	57 (58 hips)	28 Type IIIA (48%) 22 Type IIIB (38%) 4 Type IIA (7%) 3 Type IIB (5%) 1 Type IIC (2%) 11 Pelvic Discontinuity (19%)	105 (range 60-150)
Konan et al.	2016	Tantalum	46	20 Type IIA 4 Type IIB 9 Type IIC 6 Type IIIA 4 Type IIIB.	120 (range 120-144)
O' Neill et al.	2018	Tantalum	38	29 Type IIIA 9 Type IIIB	36 (range 18-74)
Zhang et al.	2020	Tantalum	18	11 Type IIIA (61.1%) 7 Type IIIB (38.9%)	61 (range 56--65.8)
Prieto et al.	2017	Tantalum	56 (58 hips)	6 Type IIA (10%) 12 Type IIB (21%) 12 Type IIC (21%) 11 Type IIIA (19%), 17 Type IIIB (29%)	64,8 (range 24-144)
Rowan et al.	2016	Tantalum	15 (17 hips)	3 Type IIB 6 Type IIC 7 Type IIIA 1 Type IIIB	64,8 (range 9,6-124,8)
Ji et al.	2021	Tantalum	21	9 Type IIC 12 Type IIIB	31 (range 18–57)
Webb et al.	2017	Tantalum	20	11 Type IIIA 8 Type IIIB	28,8
Clement et al.	2016	Tantalum	52 (55 hips)	2 Type IIA 7 Type IIB 21 Type IIC 15 Type IIIA 10 Type IIIB	63 (range 34- 105)

The published articles consist of studies describing the use of porous metal in revision THA in patients with the preoperative classification of Paprosky type II and III. Only two of these were prospectively performed (9, 10). The remaining studies were conducted retrospectively. The main indication for revision surgery was aseptic loosening. In general, revision was performed based on clinical symptoms and radiological findings. The outcome measures are summarized in Table III.

Table III. Outcome measures.

Authors	Survival or reoperation rate	Complications	Clinical outcomes (Pre-operative / Final Follow Up)	Radiological evaluations
Russell et al.	mean survivorship of 8.99 years (\pm 0.56, 95%; CI: 7.89-10.09).	Early postoperative - 1 (2.6%) Early infection recurrence (Washout, debridement, implant retention) - 1 (2.6%) Allograft resorption (Revised) - 1 (2.6%) Transient sciatic neuropraxia (No) Late postoperative - 3 (7.9%) Late infection recurrence (Revised) -2 (5.3%) Aseptic loosening (with augment failure) (Revised)	WOMAC 49.15 (range: 3.1 to 98.4) / 22.75 (range: 0 to 89.6)	- Well integrated in 29 of 31 (93.5%) non revised cases. -28 of 31 (90.0%) well osseointegrated (97%) (3 or more signs of osseointegration according to Moore's Criteria)

		-1 (2.6%) Dislocation from constrained liner (Revised) -1 (2.6%) Recurrent dislocations due to greater trochanter nonunion (No)			
Perticarini et al.	88.54% (95% CI 80.18–93.52%) at 71 months,	Late postoperative - 7 (7.3%) patients suffered of deep infection at a mean time of 35.85 months after surgery. (Revised) - 7 (7.3%) patients underwent dislocation - 2 (2.1%) periprosthetic femoral shaft fractures - 1 (1.05%) case of trochanteric bursitis.	HHS 25–70) / 46–99)	43.7 (range 84.4 (range	- 1 case of reabsorption of the graft, resulting in cup loosening 1 year after surgery (1.05%) - In all other acetabular components evident signs of osseointegration, without any radiolucent lines, sclerotic areas, or periprosthetic osteolysis.
Loppini et al.	100% at 34 months	3 (6.3%) patients: - 1 deep venous thrombosis - 1 femoral artery occlusion - 1 postoperative haematoma	HHS 14–26) / 62–88)	19.38 (range: 77.2 (range: 34.4 (range: 28.6–40.5) / 82.3 (range:	Radiolucent lines: 1 of the 16 (6.3%) of the 16 hips was noted a radiolucent line in zone 1 which was not progressive at the latest follow-up.
Grappiolo et al.	The survival rate at 2 and 5 years was 96.4% and 92.8%, respectively. The mean implant survival was 85.8 months (95% CI: 80.9–90.8).	Early postoperative 1 (1.8%) recurrent instability Late postoperative 3 (5.4%) aseptic loosening of the cup (in 2 cases cup + augment)	HHS 27–52) / 61–91)	40 (range: 87,1 (range:	Radiolucent lines: 3 of the 55 (5.4%) of the 16 hips (not progressive)
Eachempati et al.	The survival rate at 8 years was 100%	Overall complications in 2/41 patients (4.87%) 1 persistent wound discharge (Washout, debridement, implant retention)	HHS 14–34) / 61–100)	26,5 (range: 90.5 (range:	No radiological failures at the time of latest follow-up
De Meo et al.	The survival rate at 48.3months was 89.7% for revision and of 94.8% for acetabular cup removal	In 6 cases (10.3%) reoperation was necessary: - 3 recurrent dislocations (5.2%); - 2 deep infections (3.4%); - 1 suspected aseptic loosening	HHS 58,9-91,3)	36,5 / 83,7 (range:	No radiolucent lines or other sign of migration were observed.
Jenkins et al.	rate of survivorship free of any re-revision of 100% at 5 years and 97% at 10 years.	2 of the 58 constructs (3%) failed because of aseptic loosening.	MAYO Hip Score 35.7 (range: 6 to 72; n = 19) / 61.7 (range: 33 to 80; n = 42)		- No lucencies of >1 mm were identified immediately postoperatively - 6 of 58 hips (10%) clear radiographic evidence of separation (>2 mm) in zone 3 (risk for future failure)
Konan et al.	The survivorship for further revision of the acetabular component as the end point. was 96% at 11 years (95% CI 92.7 to 98.7) The survivorship for any reason as the end point, was 92% at 11 years (95% CI 90.2 to 94.8).	2 of the 46 failed because of aseptic loosening 2 recurrent hip dislocations within two years	WOMAC 33.3 to 100) UCLA to 10) Oxford Hip Score* 91.2 (range: 31.8 to 100)	91.1 (range: 5.5 (range: 2	Radiographs follow-up at a mean of 30.9 months (24 to 51): In 39 of 40 hips (40 patients) there was radiological evidence of osseointegration (Moore's criteria) Radiographs follow-up at the time of review: 32 of the 38 patients who remained alive showed evidence of osseointegration

O' Neill et al.	3-year survival rate with revision due to any cause 92.1% (83-101) with 35 patients at risk 3-year survival rate with revision due to aseptic loosening was 94.7% 87-102)	2 radiographic metal debris at the shell-augment interface. 8 Brooker grade 1 HO 3 grade 2 HO 3 grade 3 HO 2 deep infections. 1 trochanteric nonunion 1 transient sciatic nerve palsy In 4 patients bone graft resorption and medial migration of the shell	WOMAC 53 / 78.8 SHORT FORM 12 (SF-12) 27.7 / 30.1		31 of 38 patients: shell-augment construct satisfied the criteria for osseointegration (Moore's criteria)
Zhang et al.	Survivorship of the last follow-up: No failure	Complication incidence (33.3%), - dislocation (16.7%), - delay wound healing (16.7%) - Trendelenburg-positive in 2 hips (11.1%) - Asymptomatic grade-1 HO in 3 (16.7%) No patients underwent re-revision surgery for any reasons at the last follow-up	HHS 35 to 50) / 68 to 85) UCLA score 2.6 (range: 2 to 4) / 7.3 (range 7 to 8)	44.1 (range: 35 to 50) / 73.7 (range: 68 to 85) 2.6 (range: 2 to 4) / 7.3 (range 7 to 8)	Bone graft incorporation in all hips one year after the revision operation
Prieto et al.	5-10 year survival rate with revision due to any cause 90% and 88%, respectively 5-10 year survival rate with revision due to aseptic loosening: 94%	8 complications in 7 patients in the entire cohort: 1 periprosthetic infection 1 periprosthetic femoral fracture 1 femoral stem loosening 2 sciatic neuropraxias 3 patients with recurrent dislocations.	HHS 80) / 100)	47 (range: 29-79) (range: 45-100)	Average allograft coverage was 42% of the acetabular component (28%-70%): 12 hips >50% of graft coverage 36 hips between 30% and 50% 7 hips <30% Allograft resorption < 25% in 14 hips (26%) >35% in 3 hips
Rowan et al.		1 dislocation Reconstruction failure requiring revision 0%	HHS 58,9 - 91,3)	52.2 / 83,3 (range: 58,9 - 91,3)	
Ji et al.	Survivorship free from re-revision for acetabular loosening after 2 years was 100 %.	2 deep venous thrombosis (10 %)	HHS (range: 24,3–47,7) / 9,0(range: 55,1–90,1).	37,0 ± 7,1 76,4 ± 9,0	- All acetabular components were all stable without migration - Non-progressive acetabular radiolucencies in no more than two zones in 2 patients. - A total of 18 patients (86 %) satisfied at least ⅓ Moore's criteria
Webb et al.	100% survivorship for aseptic loosening and an 80% survivorship from revision for any cause of the double cup constructs	12 (60%) of recorded complications were in 8 patients. - 6 total dislocations (30%) - 4 deep infection (20%)	HHS 14-45) / 19 -89)	28,2 (range: 14-45) / 28,7 (range: 19 -89)	- No radiographic evidence of failure based on Moore's criteria
Clement et al.	implant survival was 92% (95% confidence interval: 80,2-96,9%) at 5 years	- 2 Early infections (1 and 7 Months to Failure) - 2 recurrent hip dislocations (15 and 28 Months to Failure) - 1 quadriceps palsy - 1 abductor weakness	*follow-up rate of 78%. OHS 48)	34 (range, 5-48)	-All cases involving the use of bone grafts had radiographic evidence of incorporation - No progressive radiolucent lines or component migration - All acetabular components: Moore score >3

All studies included post-operative hip scores. In the studies in which preoperative hip scores were reported, the scores improved postoperatively. The review of 634 revision THA described in these articles has a mean follow-up period

of 61.9 months and a mean survival rate with revision due to aseptic loosening of 95.7%. We found different treatment options for large acetabular defects. The TM Augment was the most widely used method in the included studies (7 studies, 331 hips). Trabecular titanium cups were used only in 2 studies (153 hips) (10, 11). Three studies (93 hips) involved using either a bone graft and/or a T.M. augment to provide stability for the acetabular component, with different goals. Prieto et al. (12) wanted to demonstrate excellent midterm survival, with 94% of acetabular components obtaining stable union onto host bone at 5 years, with Trabecular metal shells combined with structural bone allograft in revision THA.

Allograft restored bone stock with minimal resorption, and when it occurred, it did not alter the acetabular component's survivorship. Rowan et al. (13) compared IBG and trabecular metal for revision THA achieving good clinical outcomes for both, but there is greater success with T.M. in higher grades of acetabular deficiency regardless of prior infection. The purpose of Zhang et al. (14) study was to compare and analyze the clinical and radiological outcomes of the use of double T.M. cups alone or combined with IBG for revision surgery in complex acetabular defects, hypothesizing that these two methods were dependable techniques to manage Paprosky III acetabular defects without pelvic discontinuity. In addition to Zhang's paper, three other studies use the Double TM cup technique (75 hips) to manage Paprosky type III defects. The results of the present review should not be considered conclusive but rather, hypothesis-generating.

DISCUSSION

Acetabular revisions in complex bone defects are challenging procedures that often require an expert surgeon. There are many different options of reconstruction in literature, such as the Jumbo cup component, IBG combined with a cemented cup, metal mesh, bulk autograft or allograft combined with hemispherical cups, and cup cage construct (14). Although there are different surgical options, the literature remains controversial, showing complications and mid-term failures (15).

Reconstruction rings and cages are usually used in acetabular revisions where residual bone stock is available to gain fixation (16-18). However, literature has shown that off-the-shelf cages have no osteoinduction and osteoconduction potential and may loosen within seven to ten years, especially when morselized allograft is used (19, 20).

Using Jumbo uncemented acetabular component may require reaming the anterior column because most superior defects are elliptical (21). The surgical technique that uses a smaller hemispherical component at a high hip centre (17, 22) may alter the hip biomechanics and can cause a high dislocation rate (11%, five of 46 hips) and loosening rate (6%, two of 36 hips) (23, 24). Another promising surgery technique is custom tri-flange components, which have a high dislocation rate and require up to six weeks to create and achieve the component from a C.T. scan (25, 26). Custom-made implants are one way to manage large bone defects in revision surgery, adequately filling the bone gap and increasing interaction with native bone (14).

Most recently, modular trabecular titanium or tantalum implants like T.M. (Zimmer, Warsaw, IN, USA) have become popular in large acetabular bone defects. T.M. is made from elemental Tantalum on a uniform porous carbon skeleton and has several advantages, such as high porosity (75-85%), a high friction coefficient, and a similar modulus of elasticity (175 GPa for Tantalum vs 113 GPa for titanium) to the cancellous bone (350 MPa–15 GPa) (14). Those characteristics increase the shear strength at the bony interface, minimize stress shielding, promote an adequate grip where bone loss is present and consequently reduce implant failure rate (27).

Also, highly porous titanium cups recently developed, with a high porosity (>60%), a large pore size (>200 μm), a low elastic modulus (0.01–30 GPa), and a high coefficient of friction have demonstrated, in the same way, good results in acetabular replacement in acetabular bone loss defect despite some concerns about osseointegration and radiolucency that had developed (28).

The literature shows that the use of Tantalum represents the most elected type of implant in complicated THA revision: in the 15 articles analyzed, only in 2 papers did the surgeons use porous titanium. Peticarini et al. (10) and De Meo et al. (11) analyzed 95 and 58 hips treated with trabecular titanium revision cups, respectively; the choice of implant is based on surgeon experience. One study did not report significant differences in implant survival and complication rate reduction when used for acetabular revision surgery (7). Unfortunately, this study presents different limitations: it is a retrospective review of prospectively entered data with no control group for comparison. Furthermore, there may be variations in the data due to different surgical techniques performed by different surgeons, even though all the surgeons are experts in revision hip surgery and follow the surgical technique described in the literature.

All the lectures analyzed in our review have shown similar excellent results at midterm follow-up, demonstrating that the acetabular augment used for structural support and cemented to the acetabular shell promotes bone ingrowth, a good fixation of the acetabular component and adequate midterm results in revision cases. From a clinical point of view,

patients of our review improved at mid-term follow-up. Clinical outcomes are described in all the studies: Harris Hip Score (HHS), Mayo Hip Score, WOMAC, UCLA and Oxford Hip Score.

Eachempati et al. (29) noted a good functional outcome in their series [preoperative HHS 26,5 (range: 14-34) to 90.5 (range: 61-100) at 39.4 months of mean follow-up]; these results are in line with the series of the other authors (12-15, 29-34). The clinical results of the other authors who evaluated different scores are also satisfactory. Table III shows raw data from WOMAC, Oxford scores, and Mayo hip score of the other series.

Few studies have evaluated the results of modular porous metal components in patients with Paprosky IIIA and IIIB defects. Russell et al. (9) reported an estimated mean implant survivorship of 8.99 years with an overall complication rate of 34% (13 of 38) inclusive of an 18.4% (8 of 38) repeat surgery rate (1 washout, debridement, and implant retention and 7 revision THA procedures) at a mean follow-up of 87-6 months. Grappiolo et al. (35) described 55 revisions in 54 patients with Paprosky IIIA (42) and IIIB (13) defects and reported a lower overall complication rate (9,1%). Four acetabular component revisions were made for aseptic loosening (5,4%) at a mean follow-up of 25 months (17 to 38 months). There was no description of the preoperative bone defects in the hips revised for aseptic loosening. The survival rate at two years was 96.4%, and 92.8% at five years. O'Neill et al. (36) evaluated 38 patients with Paprosky IIIA (29), Paprosky IIIB (9) defects, and four patients with pelvic discontinuity. They described a 94.7% survivorship with aseptic loosening in a follow-up of three years. Perticarini et al. reported a mean survivorship of 88.54% (95% CI 80.18-93.52%) at 91 months follow-up (maximum 146 months) in 95 patients treated with trabecular titanium cups (10). These results align with those presented by De Meo et al. in a recent article where they used trabecular titanium in hip revision with an overall survivorship of the cup of 94.8% at a follow-up of 48.3 months. The authors reported a rate of aseptic loosening of 1.5% at 48.3 months (11).

Other series with Paprosky IIIA and IIIB defects managed with tantalum augments and T.M. acetabular components ranging from 16 to 58 hips with follow-up ranging from 28.8 to 120 months have reported low failure rates related to aseptic loosening(12-15, 29-34).

Complications related to surgery were also described despite the significant survival rates reported in the studies. Five authors describe deep infections in post-operative follow-up: Russell et al. (9) showed one early infection recurrence, successfully treated with washout, debridement, and implant retention, and 3 (7.9%) Late deep infections that required a two-stage revision; in Perticarini et al. seven (7.3%) patients had a deep prosthetic infection at a mean time of 35.85 months post-surgery. Two had a history of periprosthetic joint infection sustained by *Pseudomonas Aeruginosa* and *Staphylococcus Aureus*. All of them required two-stage revision surgery (10). Webb et al. described four hips (20%) with a deep infection within one year. They undergo chronic suppression and irrigation/debridement with an exchange of modular components. One of these patients developed sepsis, and the components were removed (33). At least Clement et al. reported two cases of patients with deep infections treated with removal of all components at 1 and 7 months to failure, respectively (34).

Although the excellent bone-implant osseointegration has been described in the literature, several studies have described cases of aseptic loosening. Russell et al. reported 2 patients revised for augment hardware failure, one of which had extensive acetabular resorption after radiotherapy for bowel cancer (9). In Grappiolo et al. (35), 4 patients underwent acetabular component revision surgery: in one patient, the augment was still integrated into the bone, and a revision shell with a cemented liner without the removal of the augment was performed. Instead, another patient had an aseptic loosening 17 months post-surgery, and a revision with both shell and augment change was performed. After 16 months, he developed another aseptic loosening of the cup and underwent a third revision with Ganz's cage and tantalum-coated cup used as augmentation. Jenkins et al. (31) reported 2 cases of failure because of aseptic loosening. In one of these, the porous tantalum augment was not paired with a porous tantalum revision shell using their standard reconstructive technique with screws and methacrylate cement between augment, stressing the importance of creating a monolithic construct to reduce micromovements at the interface of the components and increase the stability of the implant.

Konan et al. reported a case where a patient needed another revision to a porous tantalum component with an augment after one year from the first revision surgery because the allograft used had been resorbed and the tantalum acetabular component migrated superiorly (15). Also, O'Neill et al. showed the same condition in the other 4 patients. These cases show how bone grafting coupled to augments is still debated in literature to improve osteointegration (36).

Another major complication in numerous studies is prosthetic dislocation: Webb et al. described a dislocation rate of up to 30% (6 hips). They treated those patients using closed reduction and bracing. One patient dislocated after one year post-surgery and was treated with revision to a constrained liner (33). Similar results are reported in the other revised articles.

The assumption is that a high rate of dislocation may depend on the severity of bone loss at the acetabular level, which prevents an optimal orientation of the cup; an interesting technique is described by Ji et al. that used a "multi-cup

reconstruction technique” to achieve the desired cup anteversion and abduction based on the re-evaluated anatomic hip centre. They reported no cases of displacement in the follow-up with the use of this surgical technique (32).

The studies also reviewed a radiological evaluation to evaluate the stability of the components. The most used criteria are the radiolucent line and radiographic signs of osseointegration in porous-coated acetabular components according to Moore’s criteria (37).

Russel et al. evaluated 31 THA and described well-osseointegrated components in 28 revisions with 3 or more signs of osseointegration according to Moore’s Criteria (9). Perticarini et al. reported 1.05% reabsorption of the graft, resulting in a cup loosening 1 year after surgery (10). Loppini et al. (30) noted a radiolucent line in 6.3% of 16 hips in zone 1, which was not progressive at least follow-up; meanwhile, Grappiolo et al. (35) describe a non-progressive radiolucent line in 5.4% of the 16 hips, Ji et al. non-progressive radiolucencies in no more than 2 zone in 2 patients (32); Jenkins et al. quote no lucencies of > 1 mm were identified immediately postoperatively and 10% of hip ha clear radiographic evidence of separation (>2mm) in zone 3 (risk for future failure) (31). Non-progressive radiolucent lines or component migration have been described by De Meo et al. and Clement et al. (11, 34).

Konan et al. describe radiological proof of osseointegration in 39 of 40 hips (40 patients) (15), O’Neil reports 31 of 38 patients: shell-augment design met the requirements for osseointegration (36), and Webb et al. demonstrated no radiological failure according to Moore criteria (33). Moore’s Criteria are based on the radiographic findings of these reviews by Ji et al. and Clement et al. in the papers.

CONCLUSIONS

The modular porous metal components have become the most promising treatment of Paprosky II and III acetabular bone defects, demonstrating excellent results regarding midterm follow-up survivorship and clinical outcomes. Although the good results were reported in the articles reviewed, few articles are still focusing on this argument and with a limited follow-up. The studies reviewed also reported complications and limitations in using this technique, which must, therefore, be customized according to the bone loss severity and the patient’s clinical conditions.

REFERENCES

1. Kurtz S, Ong K, Lau E, Mowat F, Halpern M. Projections of primary and revision hip and knee arthroplasty in the United States from 2005 to 2030. *J Bone Joint Surg Am.* 2007;89(4):780-785. doi:<https://doi.org/10.2106/JBJS.F.00222>
2. Pulido L, Rachala SR, Cabanela ME. Cementless acetabular revision: past, present, and future. *Revision total hip arthroplasty: the acetabular side using cementless implants.* *Int Orthop.* 2011;35(2):289-298. doi:<https://doi.org/10.1007/s00264-010-1198-y>
3. Baauf M, van Hooff ML, Spruit M. Current construct options for revision of large acetabular defects: a systematic review. *JBJS Rev* 2016;4(11):
4. Shon WY, Santhanam SS, Choi JW. Acetabular Reconstruction in Total Hip Arthroplasty. *Hip Pelvis.* 2016;28(1):1-14. doi:<https://doi.org/10.5371/hp.2016.28.1.1>
5. Meneghini RM, Meyer C, Buckley CA, Hanssen AD, Lewallen DG. Mechanical stability of novel highly porous metal acetabular components in revision total hip arthroplasty. *J Arthroplasty.* 2010;25(3):337-341. doi:<https://doi.org/10.1016/j.arth.2009.03.003>
6. Bobyn JD, Stackpool GJ, Hacking SA, Tanzer M, Krygier JJ. Characteristics of bone ingrowth and interface mechanics of a new porous tantalum biomaterial. *J Bone Joint Surg Br.* 1999;81(5):907-914. doi:<https://doi.org/10.1302/0301-620x.81b5.9283>
7. Cruz-Pardos A, Garcia-Rey E, Fernandez-Fernandez R, Ortega-Chamarro J. Do trabecular metal cups achieve better results when compared to hemispherical porous titanium cups in acetabular revision surgery? *Hip Int.* 2021;31(6):774-781. doi:<https://doi.org/10.1177/1120700020919943>
8. Moher D, Liberati A, Tetzlaff J, Altman DG, Group P. Preferred reporting items for systematic reviews and meta-analyses: the PRISMA statement. *PLoS Med.* 2009;6(7):e1000097. doi:<https://doi.org/10.1371/journal.pmed.1000097>
9. Russell SP, O’Neill CJ, Fahey EJ, Guerin S, Gul R, Harty JA. Trabecular Metal Augments for Severe Acetabular Defects in Revision Hip Arthroplasty: A Long-Term Follow-Up. *J Arthroplasty.* 2021;36(5):1740-1745. doi:<https://doi.org/10.1016/j.arth.2020.12.033>
10. Perticarini L, Rossi SMP, Medetti M, Benazzo F. Clinical and radiological outcomes of acetabular revision surgery with trabecular titanium cups in Paprosky type II and III bone defects. *J Orthop Traumatol.* 2021;22(1):9. doi:<https://doi.org/10.1186/s10195-021-00571-1>
11. De Meo F, Cacciola G, Bellotti V, Bruschetta A, Cavaliere P. Trabecular Titanium acetabular cups in hip revision surgery: mid-term clinical and radiological outcomes. *Hip Int.* 2018;28(2_suppl):61-65. doi:<https://doi.org/10.1177/1120700018812992>

12. Prieto HA, Kralovec ME, Berry DJ, Trousdale RT, Sierra RJ, Cabanela ME. Structural Allograft Supporting a Trabecular Metal Cup Provides Durable Results in Complex Revision Arthroplasty. *J Arthroplasty*. 2017;32(11):3488-3494. doi:<https://doi.org/10.1016/j.arth.2017.05.051>
13. Rowan FE, Gorenchtein M, Aslam S, Condon F, Masterson EL. A comparison of acetabular impaction grafting and trabecular metal for revision arthroplasty. *Hip Int*. 2016;26(4):350-354. doi:<https://doi.org/10.5301/hipint.5000362>
14. Zhang X, Li Z, Wang W, Liu T, Peng W. Mid-term results of revision surgery using double-trabecular metal cups alone or combined with impaction bone grafting for complex acetabular defects. *J Orthop Surg Res*. 2020;15(1):301. doi:<https://doi.org/10.1186/s13018-020-01828-x>
15. Konan S, Duncan CP, Masri BA, Garbuz DS. Porous Tantalum uncemented acetabular components in revision total hip arthroplasty: a minimum ten-year clinical, radiological and quality of life outcome study. *Bone Joint J*. 2016;98-B(6):767-771. doi:<https://doi.org/10.1302/0301-620X.98B6.37183>
16. Goodman S, Saastamoinen H, Shasha N, Gross A. Complications of ilioischial reconstruction rings in revision total hip arthroplasty. *J Arthroplasty*. 2004;19(4):436-446. doi:<https://doi.org/10.1016/j.arth.2003.11.015>
17. Issack PS, Nousiainen M, Beksac B, Helfet DL, Sculco TP, Buly RL. Acetabular component revision in total hip arthroplasty. Part I: cementless shells. *Am J Orthop (Belle Mead NJ)*. 2009;38(10):509-514.
18. Issack PS, Nousiainen M, Beksac B, Helfet DL, Sculco TP, Buly RL. Acetabular component revision in total hip arthroplasty. Part II: management of major bone loss and pelvic discontinuity. *Am J Orthop (Belle Mead NJ)*. 2009;38(11):550-556.
19. Bostrom MP, Lehman AP, Buly RL, Lyman S, Nestor BJ. Acetabular revision with the Contour antiprotrusion cage: 2- to 5-year follow-up. *Clin Orthop Relat Res*. 2006;453(188-194). doi:<https://doi.org/10.1097/01.blo.0000246533.37006.b0>
20. Whaley AL, Berry DJ, Harmsen WS. Extra-large uncemented hemispherical acetabular components for revision total hip arthroplasty. *J Bone Joint Surg Am*. 2001;83(9):1352-1357. doi:<https://doi.org/10.2106/00004623-200109000-00010>
21. Berry DJ, Sutherland CJ, Trousdale RT, et al. Bilobed oblong porous coated acetabular components in revision total hip arthroplasty. *Clin Orthop Relat Res*. 2000;371(1):154-160. doi:<https://doi.org/10.1097/00003086-200002000-00019>
22. Pagnano W, Hanssen AD, Lewallen DG, Shaughnessy WJ. The effect of superior placement of the acetabular component on the rate of loosening after total hip arthroplasty. *J Bone Joint Surg Am*. 1996;78(7):1004-1014. doi:<https://doi.org/10.2106/00004623-199607000-00004>
23. Dearborn JT, Harris WH. High placement of an acetabular component inserted without cement in a revision total hip arthroplasty. Results after a mean of ten years. *J Bone Joint Surg Am*. 1999;81(4):469-480. doi:<https://doi.org/10.2106/00004623-199904000-00004>
24. DeBoer DK, Christie MJ, Brinson MF, Morrison JC. Revision total hip arthroplasty for pelvic discontinuity. *J Bone Joint Surg Am*. 2007;89(4):835-840. doi:<https://doi.org/10.2106/JBJS.F.00313>
25. Holt GE, Dennis DA. Use of custom triflanged acetabular components in revision total hip arthroplasty. *Clin Orthop Relat Res*. 2004;429(2):209-214. doi:<https://doi.org/10.1097/01.blo.0000150252.19780.74>
26. Beckmann NA, Weiss S, Klotz MC, Gondan M, Jaeger S, Bitsch RG. Loosening after acetabular revision: comparison of trabecular metal and reinforcement rings. A systematic review. *J Arthroplasty*. 2014;29(1):229-235. doi:<https://doi.org/10.1016/j.arth.2013.04.035>
27. Goriainov V, Jones A, Briscoe A, New A, Dunlop D. Do the cup surface properties influence the initial stability? *J Arthroplasty*. 2014;29(4):757-762. doi:<https://doi.org/10.1016/j.arth.2013.07.007>
28. Jauregui JJ, Banerjee S, Cherian JJ, Elmallah RK, Pierce TP, Mont MA. Early Outcomes of Titanium-Based Highly-Porous Acetabular Components in Revision Total Hip Arthroplasty. *J Arthroplasty*. 2015;30(7):1187-1190. doi:<https://doi.org/10.1016/j.arth.2015.02.013>
29. Eachempati KK, Malhotra R, Pichai S, et al. Results of trabecular metal augments in Paprosky IIIA and IIIB defects: A multicentre study. *Bone Joint J*. 2018;100-B(7):903-908. doi:<https://doi.org/10.1302/0301-620X.100B7.BJJ-2017-1604.R1>
30. Loppini M, Schiavi P, Rocca AD, et al. Double-trabecular metal cup technique for the management of Paprosky type III defects without pelvic discontinuity. *Hip Int*. 2018;28(2_suppl):66-72. doi:<https://doi.org/10.1177/1120700018813208>
31. Jenkins DR, Odland AN, Sierra RJ, Hanssen AD, Lewallen DG. Minimum Five-Year Outcomes with Porous Tantalum Acetabular Cup and Augment Construct in Complex Revision Total Hip Arthroplasty. *J Bone Joint Surg Am*. 2017;99(10):e49. doi:<https://doi.org/10.2106/JBJS.16.00125>
32. Ji B, Li G, Zhang X, Wang Y, Mu W, Cao L. Multicup reconstruction technique for the management of severe protrusion acetabular defects. *Arthroplasty*. 2021;3(1):26. doi:<https://doi.org/10.1186/s42836-021-00081-9>
33. Webb JE, McGill RJ, Palumbo BT, Moschetti WE, Estok DM. The Double-Cup Construct: A Novel Treatment Strategy for the Management of Paprosky IIIA and IIIB Acetabular Defects. *J Arthroplasty*. 2017;32(9S):S225-S231. doi:<https://doi.org/10.1016/j.arth.2017.04.017>
34. Clement RG, Ray AG, MacDonald DJ, Wade FA, Burnett R, Moran M. Trabecular Metal Use in Paprosky Type 2 and 3 Acetabular Defects: 5-Year Follow-Up. *J Arthroplasty*. 2016;31(4):863-867.

-
- doi:<https://doi.org/10.1016/j.arth.2015.10.033>
35. Grappiolo G, Loppini M, Longo UG, Traverso F, Mazziotta G, Denaro V. Trabecular Metal Augments for the Management of Paprosky Type III Defects Without Pelvic Discontinuity. *J Arthroplasty*. 2015;30(6):1024-1029. doi:<https://doi.org/10.1016/j.arth.2015.01.001>
36. O'Neill CJ, Creedon SB, Brennan SA, et al. Acetabular Revision Using Trabecular Metal Augments for Paprosky Type 3 Defects. *J Arthroplasty*. 2018;33(3):823-828. doi:<https://doi.org/10.1016/j.arth.2017.10.031>
37. Moore MS, McAuley JP, Young AM, Engh CA, Sr. Radiographic signs of osseointegration in porous-coated acetabular components. *Clin Orthop Relat Res*. 2006;444(176-183. doi:<https://doi.org/10.1097/01.blo.0000201149.14078.50>

Evaluation study

THE TREATMENT WITH OXYGEN-OZONE THERAPY OF FIRST-DEGREE SPONDYLOLISTHESIS SECONDARY TO SPONDYLOLYSIS. OBSERVATIONAL STUDY ON 168 PATIENTS

M. Bonetti^{1*}, M. Frigerio¹, G.M. Ottaviani², G. Pellicanò³ and M. Muto⁴

¹Department of Neuroradiology, Istituto Clinico Città di Brescia, Brescia, Italy;

²Department of Emergency, Spedali Civili di Brescia, Brescia, Italy;

³Department of Neuroradiology, Azienda Ospedaliera, Universitaria Careggi, Firenze, Italy;

⁴Department of Neuroradiology, Ospedale Cardarelli Napoli, Napoli, Italy

*Correspondence to:

Matteo Bonetti, MD

Department of Neuroradiology,

Istituto Clinico Città di Brescia,

Via Bartolomeo Gualla 15,

25128 Brescia, Italy

e-mail: dottorbonetti@gmail.com

ABSTRACT

In recent years several studies have demonstrated the utility of oxygen-ozone therapy in the treatment of herniated discs with the result of herniated discs reduced in size. In this study the authors evaluate the therapeutic results obtained in the treatment of 168 patients suffering from non-discogenic low back pain caused by pathology of the posterior vertebral compartment afflicted by spondylolisthesis secondary to spondylolysis. The patients recruited into the study were evaluated in the short, medium and long term (one week, three months and six months) and were clinically assessed using a modified version of McNab's method.

KEYWORDS: *oxygen, ozone, ozone therapy, spondylolysis, spondylolisthesis*

INTRODUCTION

Oxygen-ozone therapy for the treatment of herniated discs was introduced for the first time in 1985. Over the years, numerous case studies have been presented in the literature reporting positive results ranging from 75% to almost 90% in the treatment of low back pain complicated or not by sciatica due to disc-radicular impingement caused by disc herniation (1-22).

Low back pain and lumbosciatica are highly disabling pathologies, increasingly widespread in every social category and at an increasingly earlier age. They arise acutely following efforts or unusual movements or slowly, often with progressive aggravation. They can have numerous etiologies related to spinal pathology: disc disease, facet joint disease, spondylolysis olisthesis, spinal canal stenosis, radicular cysts, meningiomas, primary or metastatic tumor pathology, etc. (23-29). It is therefore essential to come to a precise diagnosis formulated after a careful objective examination and supported by suitable instrumental tests, such as – in addition to standard radiographs of the spine – Computerized Axial Tomography (CT) and/or Nuclear Magnetic Resonance (MRI) (11, 13).

We have been carrying out oxygen-ozone therapy in our clinics for over twenty-five years for the treatment of low back pain and lumbosciatica due to disc-radicular conflict.

Received: 4 April 2023
Accepted: 10 May 2023

Copyright © by LAB srl 2023

This publication and/or article is for individual use only and may not be further reproduced without written permission from the copyright holder. Unauthorized reproduction may result in financial and other penalties. Disclosure: All authors report no conflicts of interest relevant to this article.

In this article, we report the results obtained in the selected treatment of patients with low back pain and/or sciatica not due to herniated and/or disc protrusions.

In particular, we focused our attention on cases of 1st degree spondylolisthesis secondary to spondylolysis, possibly responsible for the described symptomatology (27).

The treated patients were clinically evaluated in the short term (one week), medium term (three months) and long term (6 months).

Spondylolysis - spondylolisthesis

Spondylolysis (a term coined by Kilian in 1854) is a bony defect of the neural arch that consists of a forward shift of one vertebral body on another.

Spondylolistheses are classified according to the Meyerding classification in relation to the degree of slippage of the vertebral body above compared to the one below (Fig. 1).

MEYERDING'S CLASSIFICATION

The degree of forward shift of one vertebral body on another is measured as a percentage according to Meyerding's classification:

Grade I 0-33%

Grade II 34-66%

Grade III 67-99%

Grade IV 100% and spondyloptosis

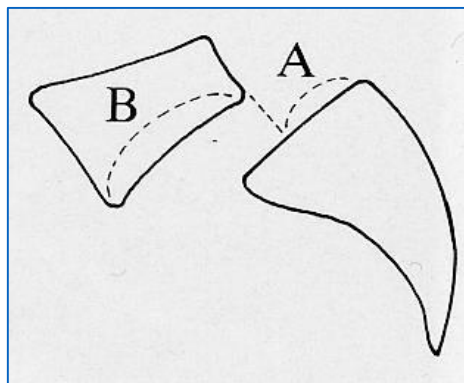


Fig. 1. Schematic representation of L5 listhesis on S1 first degree of Meyerding.

In the majority of cases, first degree spondylolisthesis is asymptomatic and is often an occasional finding, however it can manifest itself with low back pain complicated or not by sciatica, in a small percentage of patients.

The majority of patients with symptomatic first degree spondylolisthesis and spondylolysis do not require surgery and the proposed therapeutic approach is often physiotherapy. However, when the symptoms are not resolved with physical therapy, they may require vertebral surgery stabilization.

MATERIALS AND METHODS

In light of the therapeutic success found with oxygen-ozone therapy in the treatment of disc-radicular conflicts due to disc herniation, it was intended to evaluate the effectiveness of this therapy in patients suffering from 1st degree spondylolisthesis (antelisthesis less than 33%), bilateral isthmic lysis (Fig. 2 A-C) and associated disc disease (herniated disc or protrusion).

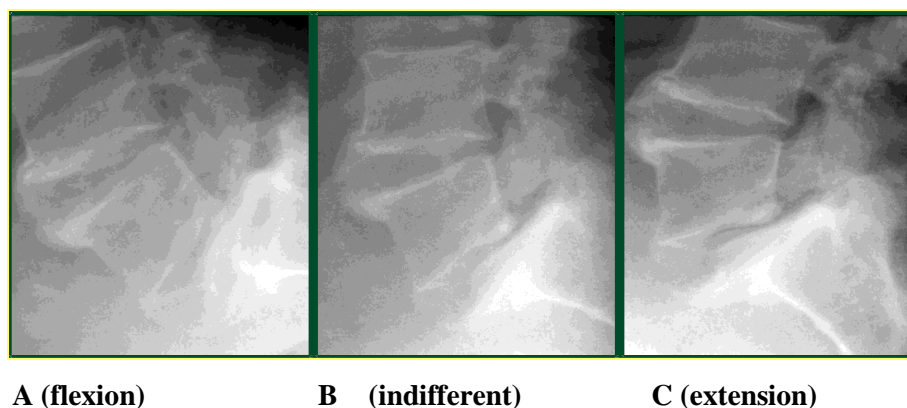


Fig. 2. Meyerding's first degree spondylolisthesis radiographic control of the degree of stability in flexion- extension. A) flexion, B) indifferent, C) extension.

In our sample, 169 patients (93 females and 75 males, aged between 24- and 69-years-old median age 43.6) were included. Inclusion criteria were: presence of listhesis, isthmic lysis and associated disc disease, symptoms characterized by low back pain complicated or not by sciatica. In total, we enrolled 106 cases of listhesis L5 on SI and 62 cases L4 on L5; 119 protrusions in the bilateral median-paramedian area and 49 contained lateralized disc herniations.

In all cases the pathology was documented with standard radiograms completed with dynamic-morfal tests. In all patients, the diagnosis of the pathology of the posterior compartment to be treated was confirmed with Magnetic Resonance Imaging (MRI), all MRI investigations were carried out with Siemens Magnetom AERA 1.5 T equipment, SYNGO MR D13 software, using standard sequences and then completing the examination using Fat/Sat sequences without administration of contrast medium (Table I).

Table I. MRI scan protocol.

T2 SAG	(Thickness 3 mm, Gap 20%, TR 3500, TE 100, Fov 300 mm, Matrix 384 Pd HF)
T1 SAG	(Thickness 3 mm, Gap 20%, TR 550, TE 9.7, Fov 300 mm, Matrix 384 Pd HF)
T2 AX	(Thickness 3 mm, Gap 10%, TR 4280, TE 100, Fov 220 mm, Matrix 384 Pd AP)
T2 SAG pair	(Thickness 3 mm, Gap 20%, TR 3900, TE 100, Fov 300 mm, Matrix 384 Pd HF)
T1 COR	(Thickness 3 mm, Gap 15%, TR 420, TE 9.1, Fov 300 mm, Matrix 384 Pd RL)
T1 FS SAG	(Thickness 3 mm, Gap 20%, TR 2500, TE 39, Fov 300 mm, Matrix 384 Pd HF, Fat/Sat)
T1 FS AX	(Thickness 3 mm, Gap 20%, TR 3500, TE 39, Fov 220 mm, Matrix 384 Pd AP, Fat/Sat)

The infiltrative treatment was performed using Hitachi model Supria 16/32 Computed Tomography (CT) equipment. All patients were treated by CT-guided bilateral periganglionic infiltration of O₂-O₃ and O₂-O₃ injection into the lysis points in the neural arch.

To produce the oxygen-ozone mixture, a "Maxi Ozon Active International produced by Medica S.r.l. CE" generator device was used, equipped with a digital photometer for the regulation of ozone concentrations, with check valves for the collection of the gaseous mixture in absolute sterility.

Infiltration technique

After receiving written informed consent from the patients, the injection level was established based on neuroradiological findings and clinical symptoms. The level was confirmed by preliminary CT scans with patient in a prone position to determine the point of needle entry (Fig. 3).

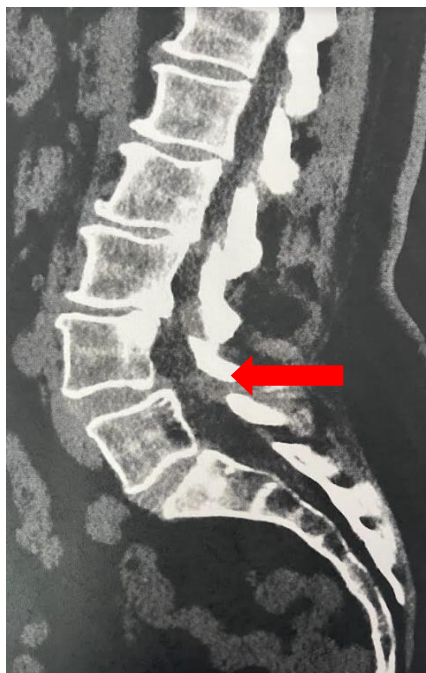

Fig. 3. CT study preliminary to the treatment documenting first degree Meyerding's listhesis of L4 on L5 (arrow).

The skin was disinfected using a polyvinylpyrrolidone iodine solution after local anesthetic with ethyl chloride spray. CT-guided puncture was then performed using needles with a caliber 22 G. CT guidance also served to check the correct position of the needle (Fig. 4).

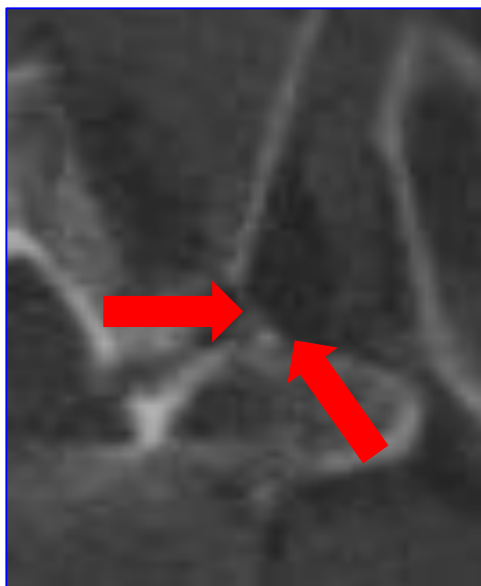

Fig. 4. CT scan with bone algorithms: verification of the correct positioning of the needle at the lysis point (arrows).

An aseptic technique was used to fill a 10 ml polyethylene syringe with a gas mixture of oxygen-ozone 3 ml at a concentration of 25 $\mu\text{g/ml}$ and was injected using a microporous filter to minimize the risk of contamination. Further CT scans were done after infiltration to confirm the correct distribution of the gas mixture in the treatment site (Fig. 5 A-B).

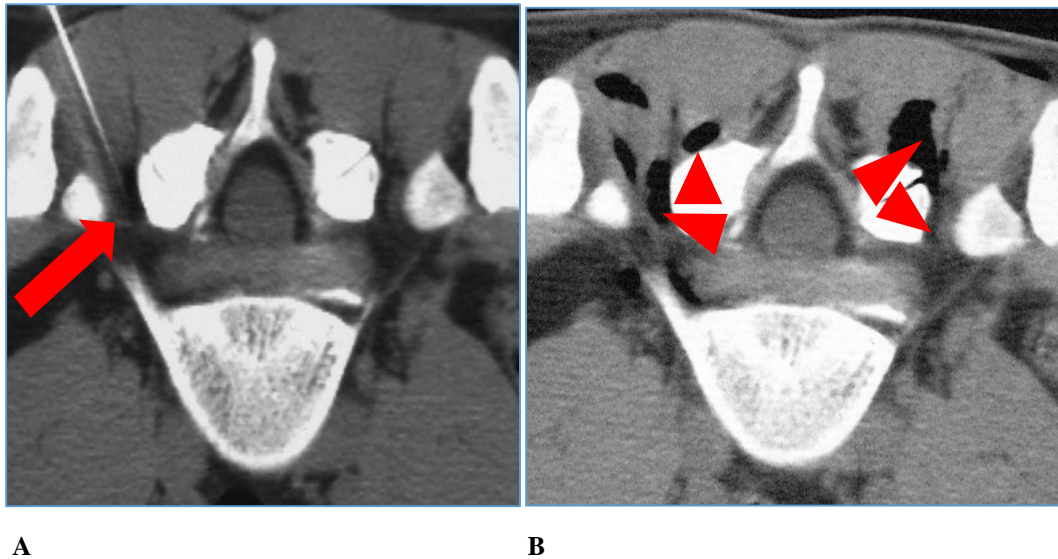


Fig. 5. **A)** correct positioning of the needle at the level of the periganglionic region (arrow); **B)** CT control of the distribution of the oxygen-ozone gas mixture at the level of the foraminal region (arrowheads) and in correspondence with the articular masses (arrowheads).

Patient was then kept under observation for around 30 min and subsequently discharged. Clinical outcome was assessed in all patients by short (one week), medium (3 months) and long-term (6 months) follow-up using a modified version of McNab's method:

- a) excellent: resolution of pain and return to normal activity carried out prior to pain onset;
- b) good or satisfactory: more than 50% reduction of pain;
- c) poor: partial reduction of pain below 70%.

DISCUSSION

In this study we propose the treatment of the posterior compartment with injections of a gaseous mixture of oxygen and ozone, carried out through targeted infiltrations.

All treated patients with spondylolysis and spondylolisthesis were evaluated in a short-term (one week), medium (three months) and long-term (six months) period using the modified McNab's method as an evaluation tool. In 114 patients (114/168, equal to 67.9%), a total resolution of the painful symptoms was obtained, in 21 (12.5%) we obtained a result considered satisfactory by the patient, while in 33 patients no therapeutic benefit was obtained. At the subsequent three-month check-up (medium term), 106 (63%) reported that the benefit of the treatment had remained constant while 44 (26.2%) were in patients for whom the situation had not substantially changed with the therapy. In the long term (clinical follow-up at 6 months), 98 patients (58.3%) continued to report an excellent clinical result obtained with the therapy, while 16 (9.5%) reported a satisfactory result, while 54 (32.2%) were patients who had not experienced substantial benefits (Fig. 6 A-B).

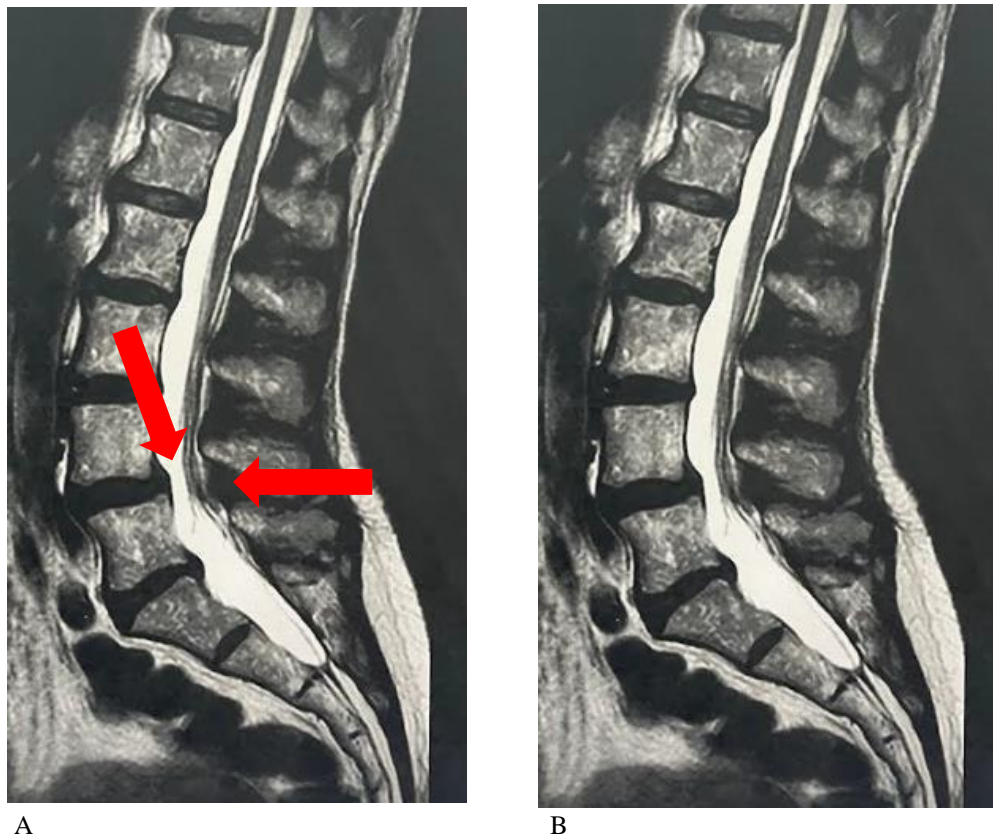


Fig 6. *A) Sagittal MRI before treatment documenting first degree Meyerding listhesis of L4 on L5 (arrows). B) MRI check at six months, from the iconographic point of view there are no substantial changes in the picture compared to a clear clinical benefit obtained with the therapy performed.*

In particular, control CT in patients who, in addition to listhesis, had a herniated disc (49 patients, 29.1%) documented complete dehydration of the hernia (in 29 out of 49, 59.1%), obviously without any modification in the degree of listhesis (Fig. 7 A-B).

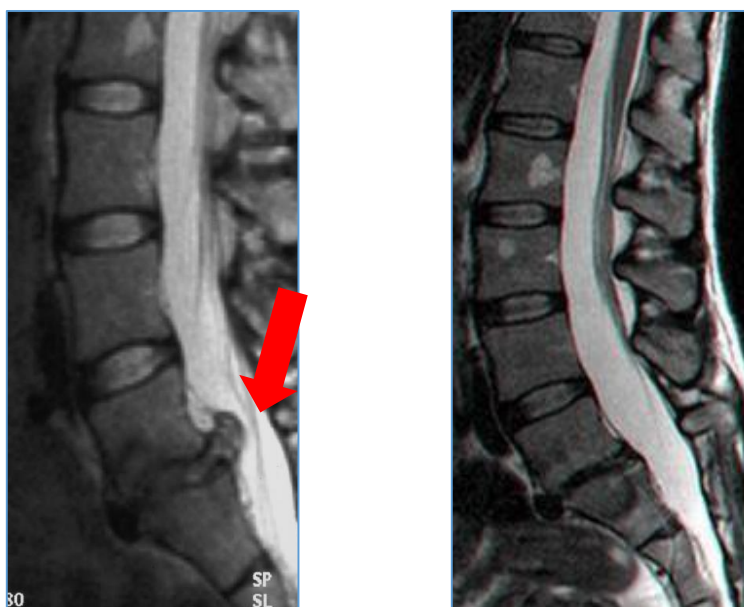

Fig. 7. *Large right paramedian herniated (arrow) disc treated by oxygen-ozone therapy in patients with spondylolysis and spondylolisthesis. Complete dehydration after treatment.*

In the 54 patients re-evaluated in the long term (6 months) we requested a neurosurgical evaluation of the situation and in 11 cases (6,5%) the neurosurgeon opted for spinal stabilization surgery, while in the remaining 43 the patient continued exclusively a physiotherapy rehabilitation program.

At the six-month clinical follow-up, the therapy therefore proved to be effective from an exclusively analgesic point of view in 98 patients (58.3%) (Table II).

Table II. *O₂-O₃ treatment in 168 patients.*

Outcome	excellent	good	poor
At 1 week	114 (67.9%)	21 (12,5%)	33 (19.6%)
At 3 months	106 (63,0%)	18 (10.8%)	44 (26,2%)
At 6 months	98 (58,3%)	16 (9.5%)	54 (32.2%)

Based on the acquired experience, we therefore believe that this therapeutic option can be offered to patients with Meyerding's first degree listhesis. We also consider that, to achieve a satisfactory clinical result, a multidisciplinary therapeutic approach to this problem is indispensable and that the support of your physiatrist colleague is fundamental to plan a subsequent postural re-education intervention aimed at maintaining the acquired therapeutic result over time.

On the other hand, in cases where the therapeutic result has been poor or unsatisfactory, in addition to the intervention of the physiatrist colleague, a neurosurgical re-evaluation of the situation is essential to decide whether or not spinal stabilization surgery is essential.

CONCLUSIONS

In recent years, several studies have demonstrated the utility of oxygen-ozone therapy in the treatment of herniated discs (1-22). In light of the well-known mechanisms of action of the oxygen-ozone mixture (7-10), in this study we evaluated the therapeutic results obtained in the treatment of 168 patients suffering from non-discogenic low back pain caused by pathology of the posterior vertebral compartment afflicted by spondylolisthesis secondary to spondylolysis (28).

In most cases, good patient selection allows for striking clinical results; in reference to our case series, we found optimal therapeutic results in a percentage of approximately 58.3% and satisfactory in 9.5% of the cases treated considering the various pathologies.

We believe, in this regard, that the administration of deep paravertebral CT-guided oxygen-ozone therapy has precise control of needle tract, permitting the curative properties of the gas mixture, which improves local circulation and allows eutrophication in proximity of the compression of the nerve root during the experience of muscle spasms. It normalizes the level of cytokines and prostaglandins, acting as an anti-inflammatory and a pain reliever; it also increases the production of superoxide dismutase (SOD) with minimization of oxidizing reagents (ROS). Finally, the close proximity to the herniated material which causes accelerated dehydration or destruction of a non-vascularized tissue justify the satisfactory end result (7-10, 14, 17, 21-23).

The rapid resolution of pain with no complications, the ease of performing the method and the complete control of infiltration thanks to the use of CT scan allow today to propose CT-guided oxygen-ozone therapy as a viable therapeutic alternative to other infiltrative or surgical treatment, also underlining how this type of therapy does not present contraindications that can hinder the success of the procedure itself.

REFERENCES

1. Gualandi G, Bonetti M. Ossigeno-ozonoterapia nel trattamento della patologia dolorosa del rachide lombare: esperienza preliminare. *Acta Toxic Therap.* 1996;17(261-264).
2. Magalhaes FN, Dotta L, Sasse A, Teixeira MJ, Fonoff ET. Ozone therapy as a treatment for low back pain secondary to herniated disc: a systematic review and meta-analysis of randomized controlled trials. *Pain Physician.* 2012;15(2):E115-129.
3. Rimeika G, Saba L, Arthimulam G, et al. Metanalysis on the effectiveness of low back pain treatment with oxygen-ozone mixture: Comparison between image-guided and non-image-guided injection techniques. *Eur J Radiol Open.* 2021;8(100389). doi:https://doi.org/10.1016/j.ejro.2021.100389

4. Steppan J, Meaders T, Muto M, Murphy KJ. A metaanalysis of the effectiveness and safety of ozone treatments for herniated lumbar discs. *J Vasc Interv Radiol*. 2010;21(4):534-548. doi:https://doi.org/10.1016/j.jvir.2009.12.393
5. Andreula CF, Simonetti L, De Santis F, Agati R, Ricci R, Leonardi M. Minimally invasive oxygen-ozone therapy for lumbar disk herniation. *AJNR Am J Neuroradiol*. 2003;24(5):996-1000.
6. Muto M, Andreula C, Leonardi M. Treatment of herniated lumbar disc by intradiscal and intraforaminal oxygen-ozone (O2-O3) injection. *J Neuroradiol*. 2004;31(3):183-189. doi:https://doi.org/10.1016/s0150-9861(04)96989-1
7. Iliakis E. Ozone treatment in low back pain. *Orthopaedics*. 1995;19(29-33).
8. Iliakis E, Valadakis V, Vynios DH, Tsiganos CP, Agapitos E. Rationalization of the activity of medical ozone on intervertebral disc a histological and biochemical study. *Rivista di Neuroradiologia*. 2001;14(1):23-30.
9. Rahimi-Movaghar V, Eslami V. The major efficient mechanisms of ozone therapy are obtained in intradiscal procedures. *Pain Physician*. 2012;15(6):E1007-1008.
10. Lehnert T, Naguib NN, Wutzler S, et al. Analysis of disk volume before and after CT-guided intradiscal and periganglionic ozone-oxygen injection for the treatment of lumbar disk herniation. *J Vasc Interv Radiol*. 2012;23(11):1430-1436. doi:https://doi.org/10.1016/j.jvir.2012.07.029
11. Splendiani A, Perri M, Conchiglia A, et al. MR assessment of lumbar disk herniation treated with oxygen-ozone diskolysis: the role of DWI and related ADC versus intervertebral disk volumetric analysis for detecting treatment response. *Neuroradiol J*. 2013;26(3):347-356. doi:https://doi.org/10.1177/197140091302600316
12. Gallucci M, Limbucci N, Zugaro L, et al. Sciatica: treatment with intradiscal and intraforaminal injections of steroid and oxygen-ozone versus steroid only. *Radiology*. 2007;242(3):907-913. doi:https://doi.org/10.1148/radiol.2423051934
13. Perri M, Grattacaso G, Di Tunno V, et al. MRI DWI/ADC signal predicts shrinkage of lumbar disc herniation after O2-O3 diskolysis. *Neuroradiol J*. 2015;28(2):198-204. doi:https://doi.org/10.1177/1971400915576658
14. Leonardi M, Simonetti L, Barbara C. The effects of the ozone on the nucleous pulposus: pathological data on one surgical specimen. *Rivista di Neuroradiologia* 2001 14(57-61).
15. Leonardi M, Andreula C, Simonetti L. Percutaneous techniques for treating disc disease. *Functional Neurology* 2003 18(242-244).
16. Leonardi M, Simonetti L, Raffi L, Cenni P, Barbara C. Mini-invasive treatment of herniated disc by oxygen-ozone injection. *Interv Neuroradiol*. 2003;9(Suppl 2):75. doi:https://doi.org/10.1177/15910199030090S211
17. Dall'Olio M, Princiotta C, Cirillo L, et al. Oxygen-ozone therapy for herniated lumbar disc in patients with subacute partial motor weakness due to nerve root compression. *Interv Neuroradiol*. 2014;20(5):547-554. doi:https://doi.org/10.15274/INR-2014-10078
18. Pellicanò F, Martinelli F, Tavanti V, et al. The Italian Oxygen-Ozone Therapy Federation (FIO) study on oxygen-ozone treatment of herniated disc. *International Journal of Ozone Therapy*. 2007;6(7-15).
19. Xu L, Li ZL, He XF, et al. Evaluation of the Clinical Curative Effect of an O(2)-O(3) mixture to Treat Lumbar Disc Herniation with Different Treatment Sessions. *Interv Neuroradiol*. 2009;15(2):159-163. doi:https://doi.org/10.1177/159101990901500204
20. M. B, Cotticelli B, Raimondi D, Valdenassi L, Richelmi P, Bertè FA. Ossigeno-ozono terapia vs infiltrazioni epidurali cortisoniche. *Rivista di Neuroradiologia*. 2005;13(203-206).
21. Bonetti M, Zambello A, Leonardi M, Princiotta C. Herniated disks unchanged over time: Size reduced after oxygen-ozone therapy. *Interv Neuroradiol*. 2016;22(4):466-472. doi:https://doi.org/10.1177/1591019916637356
22. Bonetti M, Fontana A, Cotticelli B, Volta GD, Guindani M, Leonardi M. Intraforaminal O(2)-O(3) versus periradicular steroidal infiltrations in lower back pain: randomized controlled study. *AJNR Am J Neuroradiol*. 2005;26(5):996-1000.
23. Oder B, Loewe M, Reisegger M, Lang W, Ilias W, Thurnher SA. CT-guided ozone/steroid therapy for the treatment of degenerative spinal disease--effect of age, gender, disc pathology and multi-segmental changes. *Neuroradiology*. 2008;50(9):777-785. doi:https://doi.org/10.1007/s00234-008-0398-2
24. Bonetti M, Zambello A, Princiotta C, Pellicano G, Della Gatta L, Muto M. Non-discogenic low back pain treated with oxygen-ozone: outcome in selected applications. *J Biol Regul Homeost Agents*. 2020;34(4 Suppl. 1):21-30 SPECIAL ISSUE: OZONE THERAPY.
25. Bonetti M, Bragaglio G, Guarino G, Marchina I, Ottaviani GM, Moretti M. Calcific post-epidural steroid infiltration epiduritis, when and if to treat with ozone therapy. *European Journal of Musculoskeletal Diseases* 2022;11(2):
26. Zhang Y, Ma Y, Jiang J, Ding T, Wang J. Treatment of the lumbar disc herniation with intradiscal and intraforaminal injection of oxygen-ozone. *J Back Musculoskelet Rehabil*. 2013;26(3):317-322. doi:https://doi.org/10.3233/BMR-130386
27. Bonetti M, Fontana A, Albertini F. CT-guided oxygen-ozone treatment for first degree spondylolisthesis and spondylolysis. *Acta Neurochir Suppl*. 2005;92(87-92). doi:https://doi.org/10.1007/3-211-27458-8_19

28. Bonetti M, Ottaviani GM, Fontana A, Pellicanò G, Della Gatta L, Muto M. Diagnosis and subsequent treatment with oxygen-ozone therapy of Baastrup's disease. *European Journal of Musculoskeletal Diseases* 2020;9
29. Krahulik D, Vaverka M, Hrabalek L, et al. Periradicular corticosteroid infiltration for radicular pain - comparison of Diprophos and Depomedrone and ozone effects. *Biomed Pap Med Fac Univ Palacky Olomouc Czech Repub.* 2023;167(1):80-84. doi:<https://doi.org/10.5507/bp.2021.061>

Comparative Study

THE TRANSOSSEUS PULL-OUT AND SUTURE ANCHOR REPAIRING TECHNIQUE IN THE TREATMENT OF ACUTE ULNAR COLLATERAL LIGAMENT INJURIES OF THE THUMB A COMPARISON OF TWO DIFFERENT SURGICAL APPROACHES

F. Rifino, F. Albano, T. Ladogana, A. Massari, M. Balducci, B. Moretti and G. Solarino

School of Medicine University of Bari “Aldo Moro” - AOU Consorziiale - “Policlinico” – Department of Basic Medical Sciences; Neuroscience and Sense Organs, Orthopaedic and Trauma Unit, Bari, Italy

**Correspondence to:*

Francesco Rifino, MD
School of Medicine, AOU Consorziiale Policlinico,
Department of Basic Medical Sciences,
Neuroscience and Sense Organs,
Orthopaedic and Trauma Unit,
University of Bari Aldo Moro,
Piazza Giulio Cesare 11,
70124, Bari, Italy
e-mail: rifinofrancesco@gmail.com

ABSTRACT

Injury of the ulnar collateral ligament (UCL) of the thumb represents a common condition that has frequently been described in athletes like skiers but also may occur in other sports such as soccer, volleyball, basketball and rugby. Many treatment choices exist; it depends on the severity of injury, timing of presentation, patient's comorbidity and associated soft tissue lesion. Grade I and II injuries may benefit from conservative treatment; a surgical approach is mandatory in case of a complete tear. The most used repair methods include the transosseous pull-out suture technique and reinsertion with a mini-anchor. This study aims to evaluate and compare the two surgical techniques in terms of functional and rehabilitative outcomes. From September 2020 to February 2022, 29 patients with a clinical and instrumental confirmed diagnosis of LCU injury of the thumb were recruited from the Orthopedics and Traumatology Unit of Policlinico of Bari. Sixteen patients underwent surgery with anchor repair; instead, 13 patients were treated with the pull-out technique. In the postoperative period, the patients were followed at first monthly, then at 6 months and at least 12 months. Sixteen patients (11 men, 5 women) underwent repair with an anchor; 13 patients (9 men, 4 women) underwent surgery with a pull-out technique. The anchor-treated cohort showed faster recovery of range of motion in flexion than the second group (P-value 0.046668). In contrast, no statistically significant difference was found in the extension recovery. At 6 months follow-up, the strange recovery was 94.4% for patients treated with anchors compared with 95.33% in patients operated with transosseous pull-out. The improvement of the pincer grip at 6 months in the anchor-treated cohort was 96.4%, while it was 94.96% in the other group. At least stability tests showed overlapping results. The two methods are found to be safe and effective for treating acute LCU injuries of the thumb. However, sutures with anchors allow earlier rehabilitation, which could eventually explain the better range of motion achieved by the patient treated with anchors 6 months after surgery compared with patients undergoing pull-out surgery. Despite the better functional and strength outcomes observed in the group of patients undergoing anchor repair, there is no significant

Received: 28 May 2023
Accepted: 02 July 2023

Copyright © by LAB srl 2023
This publication and/or article is for individual use only and may not be further reproduced without written permission from the copyright holder. Unauthorized reproduction may result in financial and other penalties. Disclosure: All authors report no conflicts of interest relevant to this article.

difference between the two groups to justify the superiority of one technique over the other from a prognostic point of view.

KEYWORDS: *ulnar collateral ligament, thumb, free tendon graft, rupture, avulsion fracture, surgery*

INTRODUCTION

The injury of the ulnar collateral ligament (UCL) of the thumb, also known as the skier's thumb, may occur due to a sharp joint sprain following trauma in violent hyperabduction. This sudden movement causes the ligament to rupture. The most common site of injury is the base of the proximal phalanx of the thumb, but in some cases, the injury may affect the head of the metacarpal or its intermediate tract (1, 2). In 1962, Stener pointed out that in the case of a complete laceration of the ulnar collateral ligament, the main problem was the absence of spontaneous scarring due to the interposition of adductor aponeurosis. Also referred to as Stener's injury, it is believed that this soft tissue interposition precludes healing (1, 2). That is why Stener's injury often requires surgery. It is now widely accepted that a complete lesion of the ulnar collateral ligament must be repaired to avoid laxity, weakness and chronic pain regardless of the presence or absence of a Stener injury (1, 3).

Different surgical techniques have been used for UCL rupture, such as the dynamic transfer of the adductor pollicis tendon, ligament reconstruction with tendon graft, MCP fusion or adductor advancement (4, 5).

The aim of the current study is to compare the functional outcomes of two different surgical techniques in two cohorts of patients with complete ulnar collateral ligament rupture of the metacarpophalangeal joint of the thumb after treatment with two different surgical techniques. The first group underwent surgery with anchor repair, while the second group was treated with an intraosseus pull-out suture technique. Afterwards, in both cases, the limb was immobilized in plaster.

Anatomy

The stability of the first metacarpophalangeal joint is provided by static and dynamic stabilizers and by the articular surface itself. The MCP is a diarthrodial joint that allows six degrees of movement: flexion-extension, abduction-adduction and rotation are enabled. Static stability is provided by bony anatomy, collateral ligaments, volar plate and dorsal capsule; dynamic stability is provided by extrinsic (extensor pollicis longus, extensor pollicis brevis, flexor pollicis longus) and intrinsic (abductor pollicis brevis, flexor pollicis brevis, adductor pollicis) muscle groups.

The ulnar collateral ligament (UCL) is composed of two distinct bundles: the proper ulnar and the collateral ligament accessory (6).

The proper bundle of UCL originates below the metacarpal head and inserts at the base of the proximal phalanx. The accessory is more superficial, fused with the volar plate, and inserted at the proximal phalanx's base. The main function of the UCL is to provide resistance to stress in valgus and volar subluxation.

During extension, the accessory ulnar collateral ligament is in tension, while the proper bundle is lax. At about 30 degrees of flexion, the proper ulnar collateral ligament tightens up while the accessory bundle becomes lax (Fig. 1a, b).

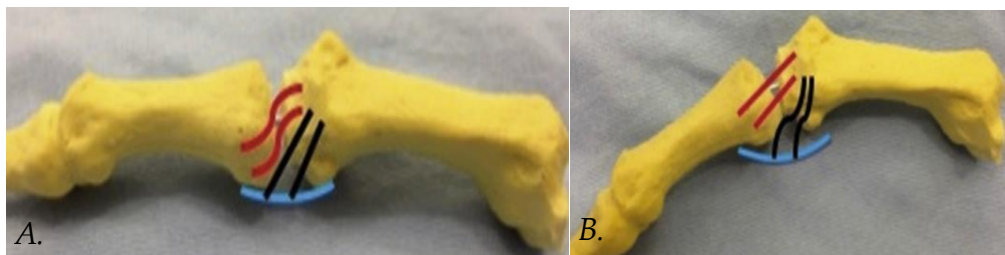


Fig. 1. *A and B*): The proper ulnar collateral ligament tightens up while the accessory bundle becomes lax.

Tolerable grades of laxity in physiological valgus are about 6 degrees in extension and 12 degrees in flexion (7-9) The UCL's primary function is to resist radial stress and volar subluxation (10, 11) (Fig. 2).

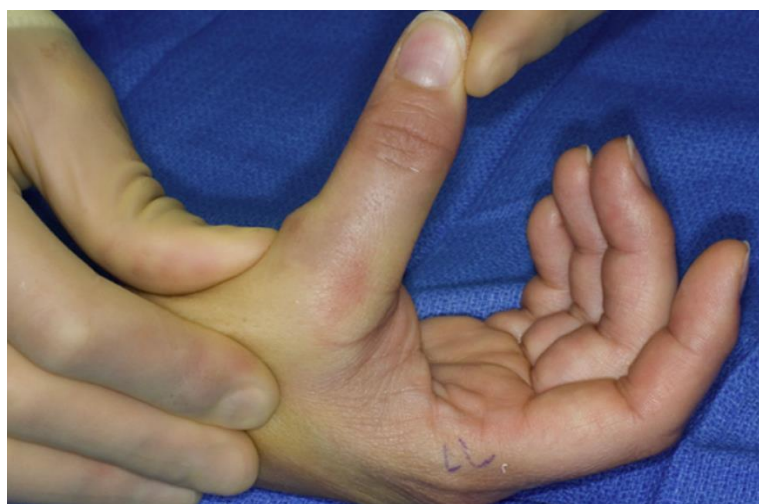

Fig. 2. UCL's primary function is to resist radial stress and volar subluxation.

Clinical presentation and imaging

The first assessment consists of an inspection of the joint. Ecchymosis, swelling, and oedema may be found; on palpation, the patient will experience pain as well as during extension and flexion of the thumb and weakness in the movement of prehension.

Radiographs should always be requested if patients have a history and clinical presentation suggestive of UCL injury. It may be useful to undergo stress views X-rays to evaluate the degree of laxity better.

Ultrasound (US) represents an additional noninvasive and inexpensive modality for the study of the UCL. This method shows accuracy ranging from 40% to 92%. A review of the literature on ultrasound examination of the UCL lesion shows a sensitivity of 76%, specificity of 81%, accuracy of 81%, positive predictive value of 74%, and negative predictive value of 87% (12).

Magnetic resonance imaging (MRI) can be very helpful in pursuing UCL injury, especially when ultrasound examination is not diriment or of unambiguous interpretation. Another method is arthrography, which is even more accurate than MRI alone. A sensitivity and specificity of 100% has been reported with MRI compared with 88% and 83% of ultrasound, respectively (13, 14). In order to describe the extent of the lesion, a UCL Instability Grading System is used:

- Grade 1: incomplete tear, sprain without instability
- Grade 2: incomplete tear with asymmetric joint laxity but endpoint present
- Grade 3: complete tear with joint instability without endpoint with more than 30-35° of joint space opening or 10-15° more than the contralateral thumb

Non-operative treatment

Immobilization in a splint or cast for 4 to 6 weeks could be considered a valid option in patients with Grade 1 and Grade 2 since these are partial injuries (4). Between the second and fourth week, physiotherapy can be started to recover movement while trying to avoid the valgus stresses of the MCF. In some cases, nonsurgical treatment has also been used with good outcomes in Grade III injuries. Some studies showed a good recovery of MCP function that appeared stable and pain-free in 85% to 90% of patients; however, the remaining patients continued to have pain and instability, eventually requiring surgical intervention. Therefore, nonsurgical treatment of grade III injuries should be considered cautiously (15, 16).

Regarding UCL lesions with an avulsion fracture, the literature appears quite conflicting. In cases of absence or minimal fragment displacement, conservative treatment with immobilization may be considered. The results, however, are very discordant: some studies show a recovery rate of 20% to 60% of cases, with total satisfaction of all patients not surgically treated; in other studies, however, patients reported persistent pain and instability after immobilization (17-19). Therefore, careful instrumental examination (X-ray and CT) is necessary to avoid misclassifying these fractures, leading to pseudoarthrosis and post-traumatic arthrosis with pain and stiffness (19).

Operative treatment

Surgical treatment is mandatory in case of acute Grade 3 injuries with more than 15° side to side variations of varus/valgus instability, more than >30-35° of opening and Stener lesion.

PATIENTS AND METHODS

Patients

From September 2020 until February 2022, 29 patients with a diagnosed lesion of the ulnar metacarpophalangeal collateral ligament (UCL) of the thumb were referred to the Orthopedics and Traumatology Unit of Policlinico di Bari. The patients mentioned above underwent surgical treatment for the repair of the injury. They were randomly divided into two groups: 16 patients underwent repair of the ULC with anchors, while the remaining 13 underwent repair by pull-out technique. After surgery, patients were followed up monthly for the first three months, then after six months, and at least annually. Follow-up data of the 29 patients included in the study were collected with a minimum latency of 6 months after surgery. This study did not consider patients with a follow-up of less than 6 months.

Methods

The same surgical team performed the postoperative evaluations in a dedicated clinic at each check. The surgical results were evaluated objectively, subjectively and radiographically. The objective evaluation consisted of stability by stressing the joint radically and ulnarly, range of motion of both extensor and flexor components of the thumb, and grip strength first of all fingers and then of the thumb individually. In our study, all patients underwent the Hand Grip Test, a specific test for hand grip strength. Patients were then objectively evaluated using a hand-held dynamometer n. EH101. These results were compared to the contralateral healthy hand. Subjective data consisted of pain and limitation of activity. For the first three months, patients were required to follow up radiographically with X-rays in two projections of the wrist and hand.

Statistic evaluation

Continuous variables were reported as means and standard deviations (SD); categorical variables, on the other hand, as numbers and percentages. A p-value <0.05 was statistically significant; analyses were performed using SPSS 22.0 (IBM Corp., Armonk, NY, USA).

Surgical technique

Twenty-nine patients in our study were divided into two groups according to the surgical technique they underwent: 13 patients treated with transosseous pull-out sutures and 16 patients treated with mini anchors.

Transosseus pull-out suture

A curvilinear cutaneous incision was made for access to the ulnar side of the first metacarpophalangeal joint, and then an incision of the aponeurosis of the adductors was made. Firstly, a capsulotomy and exploration of the ulnar collateral ligament of the first metacarpal phalange joint was performed, and the same joint was temporarily stabilized with transosseous K-wire (size 1.2 mm). Secondly, two transosseous tunnels were created in the proximal phalanx, and a pull-out of the UCL's accessory bundles was made. All patients underwent a fluoroscopic check. Then, the aponeurosis of the adductors and the overlying planes were sutured. At the end of the surgery, the limb was immobilized in a splint cast, and a postoperative X-ray was performed. The removal of the button in support of the suture was then carried out about 40 days after surgery after joint stability was assessed clinically, with specific tests, and radiographically.

Reinsertion with mini anchor

A curvilinear incision was made dorsally for access to the ulnar side of the first ray metacarpophalangeal joint. Then, an incision of the aponeurosis of the adductors was run. A capsulotomy and exploration of the ulnar collateral ligament of the first metacarpal phalange joint was performed, and the same joint was temporarily stabilized with transosseous K-wire (size 1.2 mm). At this point, with the aid of intraoperative fluoroscopy and after having assessed the joint instability in radial stress deviation, a 2.4 mm FASTack Arthrex anchor was inserted at the base of the proximal phalanx, and then the disengaged ulnar collateral ligament was retentioned. Afterwards, all patients were subjected to a fluoroscopic check with an assessment of the implant stability, and then they underwent adductors aponeurosis and overlying plane suture. At the end of the surgery, each patient was treated with immobilization in a cast and subsequent postoperative RX control.

RESULTS

Twenty-nine patients with UCL lesions of the thumb underwent surgical treatment; 16 (55.17%, of which 11 men and 5 women) were subjected to surgical treatment with mini-anchor repair and 13 (44.83%, of which 9 men and 4 women) instead, undergone surgery with pull out technique.

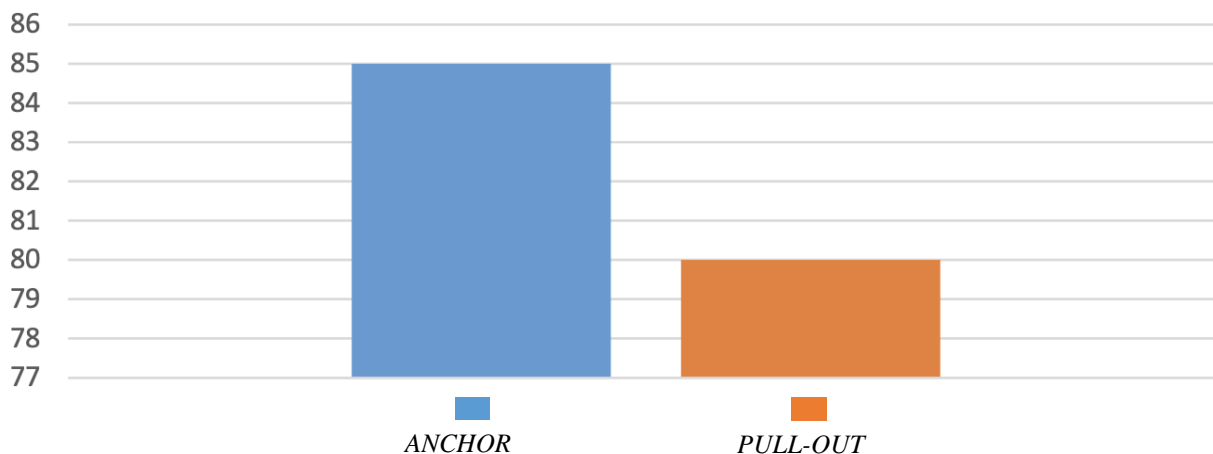
Patients' ages range from a minimum age of 23 to a maximum of 59 years, with an average age of 41.86 years. The average age of women at the time of surgery is 36.78 years, that of men over 44.15 years.

The lesion of the ulnar collateral ligament found among the patients is secondary in 79.31% to an established trauma; in 20.69% of the cases, it was impossible to find an objective cause, neither traumatic nor of other nature. In the sample of traumatized patients, 52.17% reported sports trauma, 43.48% following an accidental fall, and only in one case (4.35%) a car crash.

Range of motion

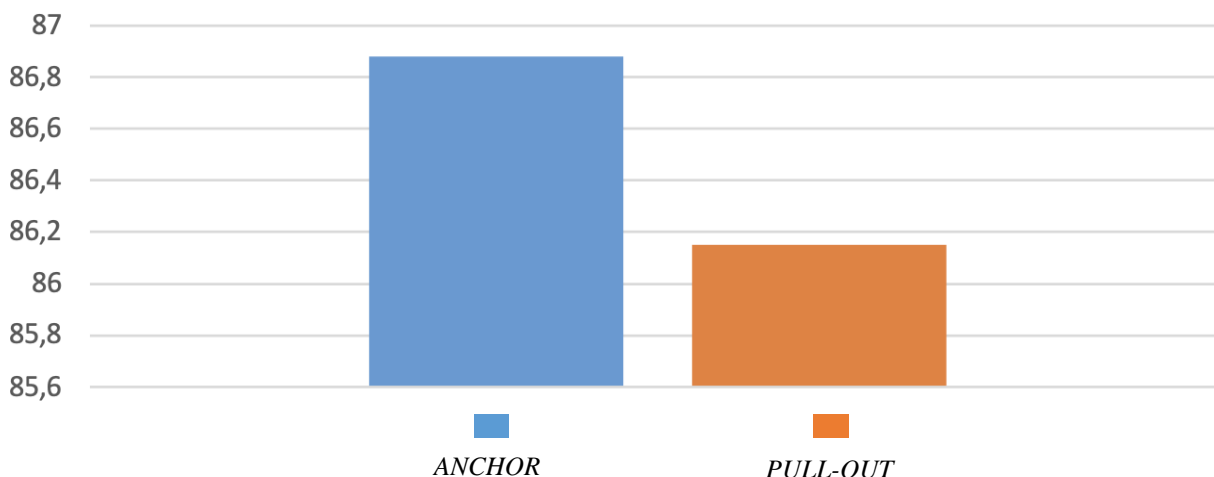
At the six-month follow-up, the range of motion (ROM) was evaluated individually in flexion and extension, from 0° to 90°, of all fingers and the thumb. Patients undergoing surgical treatment with an anchor recovered the range of flexion motion earlier than those treated with a pull-out technique (Table I).

Table I. MCP flexion R.O.M at six month follow-up (85 ± 6.32 vs 80 ± 9.13 , T-value 1.7395. P-value 0.046668).



Regarding the range of motion in extension, a complete recovery was recorded in almost all patients 6 months after surgery; there was no statistically significant difference between the two groups, so the results could be considered comparable (Table II).

Table II. MCP extention R.O.M at six month follow-up ($86,88 \pm 4,79$ vs $86,15 \pm 5,06$, T-value 0.39319. P-value 0.348633).



Grip and pinch strength

The grip strength (expressed in kilogram) was evaluated 6 months after the surgery, both for the mini-anchor treated group (Table III) and for the pull-out treated cohort (Table IV).

Table III. Recovery of Grip and pinch strength in the affected arm vs contralateral healthy side in patient undergone surgical suture anchor at six-month follow-up (41.93 vs 44.42).

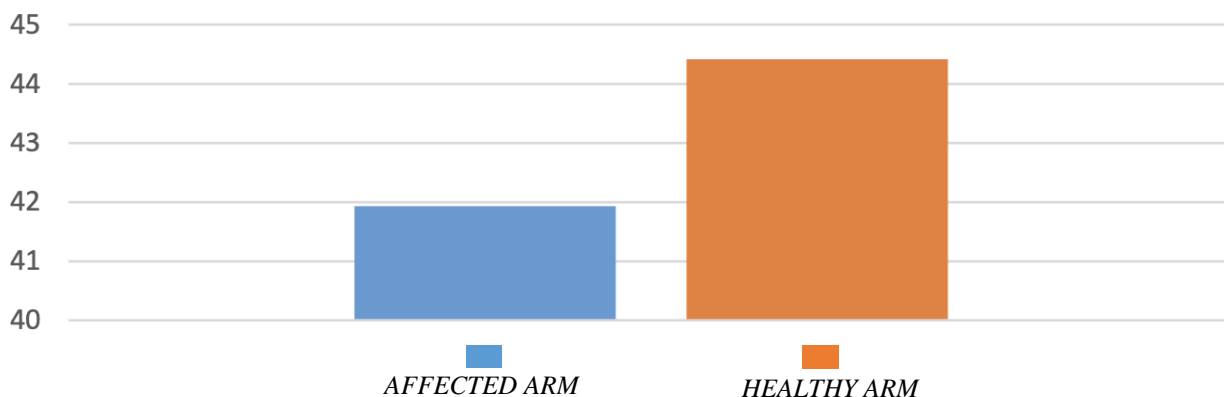
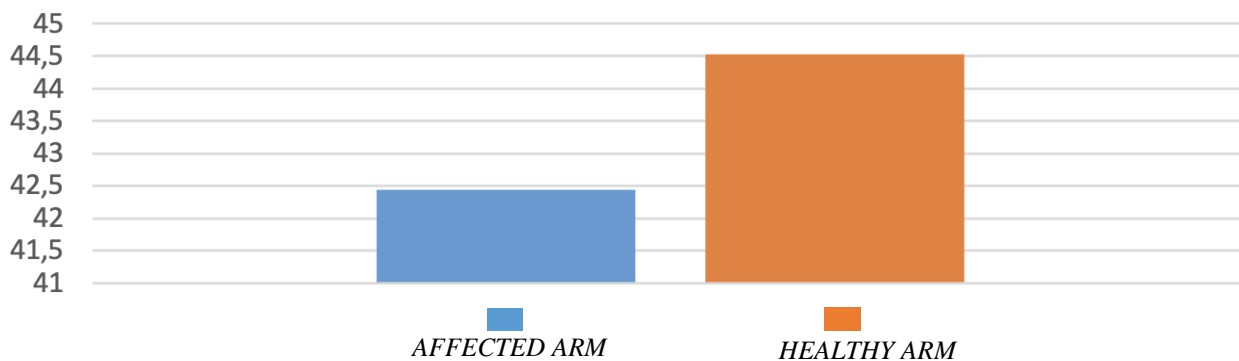


Table IV. Recovery of Grip and pinch strength in the affected arm vs contralateral healthy side in patient undergone surgical transosseus pull-out suture at six month follow up (42.44 vs 44.52).



Due to the significant heterogeneity of data (gender and age particularly), a comparison between the strength of both limbs was preferred. Both groups showed a progressive recovery of strength, equal to 94.4% in patients operated with an anchor and 95.33% in patients with transosseous pull-out. However, no statistically significant differences were found between the two groups. Six months after surgery, neither technique effectively recovered the grip strength and the pinch strength (p-value 0.474862 with $p < 0.05$). All data collected among the patients undergoing the study align with those described in the literature. Regarding the grip strength related only and exclusively to the thumb, the recovery of strength at 6 months in patients who underwent operation with an anchor was 96.4%, while it was 94.96% in patients operated with the pull-out technique (Tables V and VI).

Table V. Recovery of Grip strength in the affected thumb vs contralateral healthy side in patient undergone surgical suture anchor at six-month follow-up (11.79 vs 12.23).

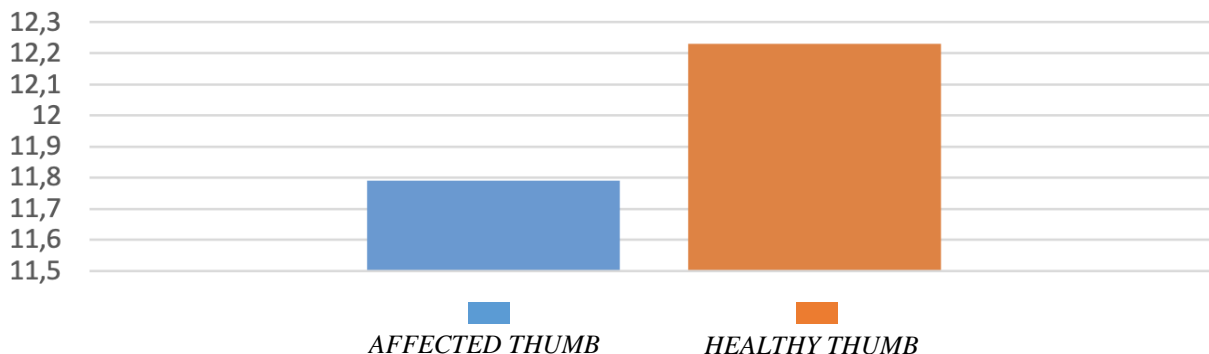
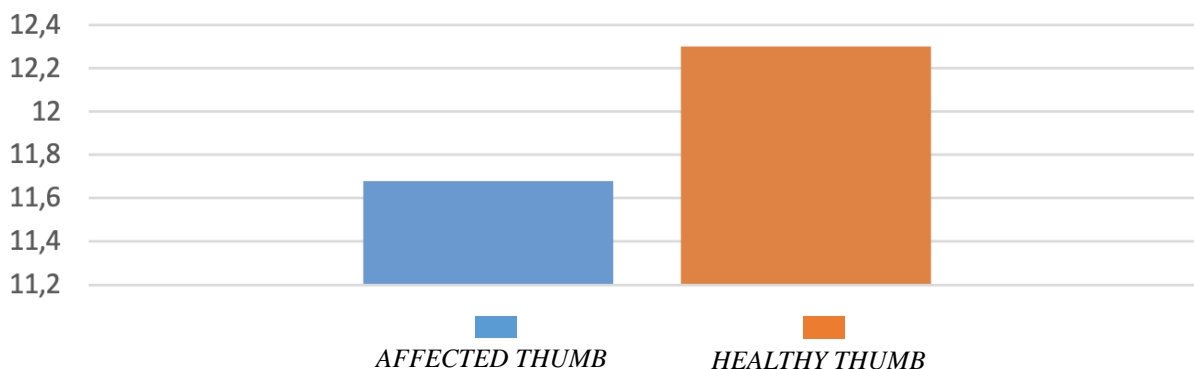


Table VI. Recovery of Grip strength in the affected thumb vs contralateral healthy side in patient undergone surgical transosseus pull-out suture at six month follow up (11.68 vs 12.30).



However, no statistically significant differences were found between the two groups (p-value 0. 212868 with $p < 0.05$).

Stability

Joint stability was assessed by exerting ulnar stress at the metacarpophalangeal joint of the first finger. Data were collected from 10° to 30° (1 patient in both groups). No statistically significant differences were found between the two groups examined.

In addition to the clinical evaluation six months after the surgery, an evaluation questionnaire (Table VII) was administered regarding the patient’s quality of life. The team used the questionnaire for the upper limb DASH (Disability of the Arm, Shoulder and Hand), suitably modified to adapt to the anatomical district considered and the type of surgery performed. The questionnaire is based on a total of 31 items.

Patients expressed numerical evaluation for each item from a minimum value of 1 (no difficulty) to a maximum value of 5 (unable).

The comparison between the two groups did not provide a statistically significant difference at six months. However, the patients who were operated on with anchor showed a higher level of satisfaction (average value 4.05) compared to patients who had undergone surgery with the pull-out technique (mean value 3.85) (Table VII).

Table VII. *Evaluation questionnaire.*

- To unscrew the lid of a tightly closed jar
- Writing
- To turn a key
- To prepare a meal
- To open a heavy door by pushing
- Doing heavy housework (e.g. washing floors or windows)
- Gardening
- Making the bed
- To carry a shopping bag
- To lift a heavy object (over 5 kg)
- To wash or dry your hair
- Using a knife
- Leisure activities requiring little effort (e.g. playing cards, knitting)
- Recreational activities
- How much the hand problem interfered with normal social activities with family, friends, etc.
- How much the hand problem has limited the work or other routine daily activities
- Pain
- Hand pain in any specific activity
- Tingling
- Weakness
- Stiffness
- How difficult it was to sleep due to hand pain
- How less capable it was to feel, less confident or less useful due to hand problem
- Difficulty in using the usual technique to work
- Difficulty in doing normal work due to hand pain
- Difficulty in doing the job well
- Difficulty in devoting the usual amount of time to work
- Any difficulty playing the musical instrument or playing sports
- Any difficulty in playing musical instruments or playing sports because of hand pain?
- Difficult playing the musical instrument or playing sports as well as you would like
- Difficulty in devoting the usual amount of time to the musical instrument or sport

DISCUSSION

The purpose of the study was to compare two surgical techniques for the repair of acute ulnar collateral ligament injury of the thumb. The groups were divided randomly by age and sex. Specifically, the repair of UCL with anchor and the transosseous pull-out have been considered. The parameters that the study focused on at 6 months follow-up were the thumb's range of motion in flexion and extension, the joint's stability, the grip and pinch strength of the hand and of the thumb itself, objectified by the dynamometer.

The technique with anchors has proved more manageable in the execution, with lower ischemia times and no intra-operative and postoperative complications. The pull-out technique has also been shown to be free of adverse events; despite everything, the surgical time with the latter technique lengthens considerably the times of ischemia, however,

without any complication at the six-month follow-up. In scientific literature, only two works have considered the comparison between these two surgical methods (1, 19).

Both works considered parameters similar to our study, such as joint range of movement, grip strength, overall patient satisfaction, costs, and documented ischemia times. The statistically significant differences found in these two studies relate to two parameters: the thumb range of motion in flexion at 6 months of follow-up, which establishes superiority in the short term of the group undergoing surgery with anchor and the time of ischemia, significantly higher in patients undergoing surgery with a pull-out technique. In addition, many adverse events have also been reported and documented in patients undergoing surgery with pull-out (e.g., erythema, infections) (1).

The pull-out technique presents greater difficulty in execution, longer time and more accurate surgical preparation (1, 19); it is usually a surgical procedure that requires more surgical experience.

In the above studies (1, 19) and ours, the presence of the button in the transosseous pull-out suture technique seems less welcome by the patient. Its maintenance in place for a minimum period of 30 days post-surgery has thus adversely affected the beginning of physiotherapy, delaying the healing. This last aspect could determine a statistical significance regarding the best recovery at six months of the thumb range of motion in flexion in patients undergoing treatment with anchor repair.

Partial data at 1-year follow-up (not included in the study because they affect a very small percentage of the patients under study) appear to show the disappearance of the above discrepancies with complete recovery of joint ROM fully comparable to the healthy limb.

CONCLUSION

Both methods are safe and effective for treating acute ulnar collateral ligament injuries of the thumb. However, suture with anchors allows an earlier rehabilitative protocol, which could explain the better range of motion achieved at 6 months postoperatively by the patient treated with anchors, compared with patients undergoing surgery with the pull-out technique. Further conclusions could be drawn from the prosecution of the present study and the addition of new evaluative parameters.

REFERENCES

1. Weiland AJ, Berner SH, Hotchkiss RN, McCormack RR, Jr., Gerwin M. Repair of acute ulnar collateral ligament injuries of the thumb metacarpophalangeal joint with an intraosseous suture anchor. *J Hand Surg Am.* 1997;22(4):585-591. doi:https://doi.org/10.1016/S0363-5023(97)80113-X
2. Stener B. Hyperextension injuries to the metacarpophalangeal joint of the thumb: rupture of ligaments, fracture of sesamoid bones, rupture of flexor pollicis brevis. An anatomical and clinical study. *Acta Chir Scand.* 1963;125(275-293).
3. Arranz Lopez J, Alzaga F, Molina J. Acute ulnar collateral ligament injuries of the thumb metacarpophalangeal joint: an anatomical and clinical study. *Acta Orthop Belg.* 1998;64(4):378-384.
4. Samora JB, Harris JD, Griesser MJ, Ruff ME, Awan HM. Outcomes after injury to the thumb ulnar collateral ligament--a systematic review. *Clin J Sport Med.* 2013;23(4):247-254. doi:https://doi.org/10.1097/JSM.0b013e318289c6ff
5. Fusetti C, Papaloizos M, Meyer H, Borisch N, Della Santa D. The ECRL bone-tendon ligamentoplasty for chronic ulnar instability of the metacarpophalangeal joint of the thumb. *Chir Main.* 2005;24(5):217-221. doi:https://doi.org/10.1016/j.main.2005.08.003
6. Johnson JW, Culp RW. Acute ulnar collateral ligament injury in the athlete. *Hand Clin.* 2009;25(3):437-442. doi:https://doi.org/10.1016/j.hcl.2009.05.014
7. Scarano A, Orsini T, Di Carlo F, Valbonetti L, Lorusso F. Graphene-Doped Poly (Methyl-Methacrylate) (Pmma) Implants: A Micro-CT and Histomorphometrical Study in Rabbits. *Int J Mol Sci.* 2021;22(3):doi:https://doi.org/10.3390/ijms22031441
8. Mogensen BA, Mattsson HS. Post-traumatic instability of the metacarpophalangeal joint of the thumb. *Hand.* 1980;12(1):85-90. doi:https://doi.org/10.1016/s0072-968x(80)80036-2
9. Moberg E, Stener B. Injuries to the ligaments of the thumb and fingers; diagnosis, treatment and prognosis. *Acta Chir Scand.* 1953;106(2-3):166-186.
10. Cooney WP, 3rd, Chao EY. Biomechanical analysis of static forces in the thumb during hand function. *J Bone Joint Surg Am.* 1977;59(1):27-36.
11. Palmer AK, Louis DS. Assessing ulnar instability of the metacarpophalangeal joint of the thumb. *J Hand Surg Am.* 1978;3(6):542-546. doi:https://doi.org/10.1016/s0363-5023(78)80003-3

12. Hergan K, Mittler C, Oser W. Ulnar collateral ligament: differentiation of displaced and nondisplaced tears with US and MR imaging. *Radiology*. 1995;194(1):65-71. doi:<https://doi.org/10.1148/radiology.194.1.7997584>
13. Papandrea RF, Fowler T. Injury at the thumb UCL: is there a Stener lesion? *J Hand Surg Am*. 2008;33(10):1882-1884. doi:<https://doi.org/10.1016/j.jhsa.2008.09.025>
14. Ahn JM, Sartoris DJ, Kang HS, et al. Gamekeeper thumb: comparison of MR arthrography with conventional arthrography and MR imaging in cadavers. *Radiology*. 1998;206(3):737-744. doi:<https://doi.org/10.1148/radiology.206.3.9494494>
15. Landsman JC, Seitz WH, Jr., Froimson AI, Leb RB, Bachner EJ. Splint immobilization of gamekeeper's thumb. *Orthopedics*. 1995;18(12):1161-1165. doi:<https://doi.org/10.3928/0147-7447-19951201-06>
16. Pichora DR, McMurtry RY, Bell MJ. Gamekeepers thumb: a prospective study of functional bracing. *J Hand Surg Am*. 1989;14(3):567-573. doi:[https://doi.org/10.1016/s0363-5023\(89\)80026-7](https://doi.org/10.1016/s0363-5023(89)80026-7)
17. Kuz JE, Husband JB, Tokar N, McPherson SA. Outcome of avulsion fractures of the ulnar base of the proximal phalanx of the thumb treated nonsurgically. *J Hand Surg Am*. 1999;24(2):275-282. doi:<https://doi.org/10.1053/jhsu.1999.0275>
18. Sorene ED, Goodwin DR. Non-operative treatment of displaced avulsion fractures of the ulnar base of the proximal phalanx of the thumb. *Scand J Plast Reconstr Surg Hand Surg*. 2003;37(4):225-227. doi:<https://doi.org/10.1080/02844310310016395>
19. Dinowitz M, Trumble T, Hanel D, Vedder NB, Gilbert M. Failure of cast immobilization for thumb ulnar collateral ligament avulsion fractures. *J Hand Surg Am*. 1997;22(6):1057-1063. doi:[https://doi.org/10.1016/S0363-5023\(97\)80049-4](https://doi.org/10.1016/S0363-5023(97)80049-4)

COMPARISON BETWEEN SUPERPATH APPROACH vs POSTEROLATERAL APPROACH IN PRIMARY TOTAL HIP ARTHROPLASTY: A 6-MONTH FOLLOW-UP

F. Simone^{1*}, G. Vicenti¹, C. Prota², G. Colasuonno¹, M. Trabace¹, B. Moretti¹ and G. Solarino¹

¹Orthopaedics Unit, Department of Basic Medical Science, Neuroscience and Sensory Organs, School of Medicine, University of Bari "Aldo Moro", AOU Consorziale Policlinico, 70124 Bari, Italy.

²Medical student

*Correspondence to:

Filippo Simone MD,
Department of Basic Medical Science
University of Bari "Aldo Moro"
70124 Bari, Italy
e-mail: filmsimo1993991@gmail.com

ABSTRACT

Total Hip Replacement has become one of the most successful orthopaedic procedures, optimizing patients' life quality and postoperative mobility. In the last few years has rapidly grown a demand for novel minimally invasive THA techniques. The supercapsular percutaneously assisted total hip (SuperPath) technique has gradually become more popular in THA surgery in recent years. Purpose of this paper is to compare difference between SuperPath approach and conventional posterolateral approach in total hip arthroplasty. This was a prospective, randomized controlled study, enrolling a total of 120 patients, 60 treated with a SuperPath and 60 with posterolateral approach, treated in our institution from August 2019 to December 2022. General demographic characteristics, intraoperative data and hospitalization time were collected. As primary endpoint, the Harris Hip Score was calculated to assess functional recovery. Pain management, need for transfusion, and hospital stay were evaluated as secondary endpoints. HHS scores showed that these were significantly higher in the SuperPATH group than in the conventional group ($P < 0.05$) at 1 month and 3 months after the intervention, while no significant difference was found at 6 months. Hospitalization time in the SuperPATH group was significantly shorter than in the conventional group ($P < 0.05$). These results suggested that the SuperPATH approach promotes the speed of recovery for hip function and reduces pain in THA patients.

KEY WORDS: *total hip arthroplasty, SuperPath, posterolateral approach, comparison*

INTRODUCTION

Total Hip Replacement has become one of the most successful orthopaedic procedures, optimizing patients' life quality and postoperative mobility (1), especially in case of hip osteoarthritis. Driven by the aging of the world population, the demand for THA is expected to grow exponentially in the next two decades. Kurtz et al noted a 50% increase in the prevalence of THA from 1990 to 2002 and projected a 174% increase, in THA from 208,600 in 2005 to 572,000 in 2030 (2).

There are several surgical approaches that are used in primary THA. Currently, the posterior approach is the most common approach utilized in the world, even if the anterior approach has gained popularity in the last few years,

while direct lateral approach (Hardinge modified) continues to be very used. There are many studies in which these approaches are compared in terms of functional results, pain suffering, recovery, risk of dislocation, but no one is able to provide a firm recommendation on which one is overall superior to the others (3).

These traditional THA approaches, however, frequently have drawbacks, such as significant bleeding and damage, high postoperative complications, and a lengthy recovery time (4). For these reasons, in the last few years has rapidly grown a demand for novel minimally invasive surgery (MIS) in THA. MIS essentially involves the modification of conventional standard approaches with emphasis on reduction of skin incision length and decreased soft-tissue dissection. Nevertheless, they could overcome even other traditional approach problems, such as postoperative pain, blood loss and enhancing postoperative functional results. However, it is necessary to fully understand if their use could be related with a longer operative time, wrong acetabular cup or femoral stem implant, and higher complication rates in general.

The supercapsular percutaneously assisted total hip (SuperPath) technique has gradually become more popular in THA surgery in recent years (5) and consist in a combination of Superior Capsulotomy described by Murphy in 2004 (6) and percutaneously assisted total hip arthroplasty (PATH) described by Penenberg et al. in 2008 (7). Patients using SuperPath have smaller surgical incisions, which could lead to reduced scarring and decreased recovery time (8). The benefit of a minimally invasive technique that spares the iliotibial band and short external rotators, including the piriformis, is achieved by the SuperPATH method. Using the greater trochanter as a marker, the femur is broached in place. In this method, the hip does not have to be dislocated, allowing the piriformis to be preserved using the short external rotators. Comparatively to more conventional procedures, which demand surgical hip dislocation to prepare the femur and carry out the femoral neck cut, this provides protection against dislocations. Additionally, it uses percutaneous equipment to avoid the requirement for angled acetabular reamers and perform standard acetabular preparation and reaming from a more direct angle.

MATERIALS AND METHODS

Patients and grouping

The objective is to evaluate the difference between the SuperPATH approach and the conventional posterolateral approach in total hip arthroplasty in patients admitted to the Orthopedic and Traumatology of Policlinico di Bari and to assess short-term functional outcomes (up to 6 months postoperatively). Visual Analogic Scale (VAS) and Harris Hip Score (HHS) at 1, 3 and 6 months postoperative were considered for functional assessment of outcomes following THA implantation according to these techniques.

This was a prospective, randomized controlled study and performed in accordance with the ethical standards set forth in the 1964 Declaration of Helsinki. All patients involved in the study gave informed consent prior to their inclusion in the study. Patients who were to undergo primary THA for hip osteoarthritis, were enrolled and treated at Policlinico di Bari between August 2019 and December 2022. Inclusion criteria were primary hip osteoarthritis, age between 40 and 81 years, body mass index (BMI) between 20 and 29.9, and chronic history (for at least 4 months) of hip joint pain.

Exclusion criteria were inflammatory hip disease or acetabular dysplasia, infection, coagulopathy, previous hip surgery, history of deep vein thrombosis or pulmonary embolism, rheumatoid arthritis, pregnancy, and patients who were unable to understand and complete the procedure due to cognitive dysfunction or language barrier. Between August 2019 and December 2022, seventy patients with hip osteoarthritis were evaluated for eligibility for the present study. Five patients had previous hip surgery, three patients participated in another study, one lived in another country, and one died at the follow-up. Therefore, they were excluded from the study. Subsequently, 60 patients were included in two groups, 1) the SuperPATH group and 2) the postero-lateral group.

General demographic characteristics including age; sex; Body Mass Index (BMI); side of surgery; American Society of Anesthesiologists (ASA) score surgical time; intraoperative blood loss; length of hospital stay; preoperative hemoglobin; transfusion requirement; Visual Analogic Scale (VAS) and Harris Hip Score (HSS) were collected for each patient. Intraoperative blood loss was measured using total body volume (the formula of Nadler et al. (8) multiplied by the change in preoperative and postoperative hematocrit levels on day 1 and the addition of any volume of intraoperative blood transfusion if administered, as described by Sehat et al. (9) and previously used in the literature). Criteria for allogeneic blood transfusion were a postoperative hemoglobin level less than ≤ 8 g/dL or a postoperative hemoglobin level between 8 and 10 g/dL with clinical signs of hemodynamic instability. Pain was quantified using the VAS scale with scores ranging from 0 (no pain) to 10 (worst pain imaginable), collecting data at first, second, third day and at one month, 3 months and 6 months after surgery. Hip function was assessed using HHS. It consists of subscales for pain severity (1 item, 0-44 points), function (7 items, 0-47 points), absence of deformity (1 item, 0-4 points), and range of motion (2 items, 0 - 5 points). Scores ranged from 0 (worst disability) to 100 (least disability) (10). For HHS, data were recorded at the

following times: T0 (before surgical procedure); T1 (one month after surgery); T2 (three months after surgery); T3 (six months after surgery).

Mini invasive Super Path approach - Surgical technique

Before surgery, standardized anteroposterior pelvic X-ray and hip joint of the operated leg was performed. According to a standardized protocol, patients received antibiotic prophylaxis with cefazolin 2 g. Patients were operated under spinal anesthesia by a single experienced hip surgeon (GV) familiar with the posterolateral approach, performing a minimum of 130 THA procedures per year. Osteotomy location and femoral neck length were predicted. An appropriate type of prosthesis was selected based on preoperative planning. The patient was positioned in standard lateral decubitus. After standard aseptic preparation and draping of the operative site, a skin incision was made from the tip of the greater trochanter to the fascia of the great gluteus with a length of 5 to 8 cm and in line with the femoral axis.

The great gluteus was carefully divided and then, a Cobb's elevator was placed under the muscle. Next, Hohmann's spreader was placed in the space between the gluteus medius and the gluteus minimus to protect the gluteus medius. The hip joint was externally rotated. A Cobb's elevator was placed between the piriformis tendon and the gluteus minimus and then also replaced with a blunt Hohmann retractor. The capsule was then incised along the path of the skin incision. The trochanteric fossa was marked with electrocautery to ensure hemostasis. The acetabular rim was separated from the joint capsule, and the incision was extended 1 cm to expose the pyriform fossa, the tip of the greater trochanter, and the anterior femoral neck. The operated leg was rotated to a neutral position to expose the saddle of the femoral neck. An entry reamer was used to introduce the femoral canal. Then, a metaphyseal reamer was used to expand the incision.

Preparation of the medullary cavity with intramedullary broaching was performed. Then, to remove the handle, the femoral neck was cut using a narrow oscillating saw blade along the top of the intramedullary broach. The femoral head was removed. Retractors were placed by the acetabular margin to retract the capsule. Soft tissues in the acetabulum and labrum were removed. A cannula was inserted through a guided 1-cm skin incision device near the main incision. An acetabular reamer of appropriate size was inserted into the acetabulum from the main incision, the reamer holder passed through the cannula tube. After multiple reaming of the acetabulum, the appropriately sized cementless acetabular cup (MicroPort Orthopedics Inc., Arlington, TN, USA) was implanted. The highly cross-linked polyethylene liner was inserted and locked using an impactor through the cannula. Appropriately sized femoral head, modular neck, and stem components were tested.

Range of motion, leg length, and joint stability were evaluated. After removing the trial components, the uncemented modular femoral stem prosthesis and femoral head (MicroPort Orthopedics Inc., Arlington, TN, USA) were implanted. Finally, the capsule and gluteal fascia and skin incision were closed layer by layer (11). According to the principles of prevention of postoperative orthopedic venous thromboembolism as in knee replacement patients were routinely treated with low molecular weight calcium heparin (4000 IU, once daily) as an anticoagulant. Subsequently, the same rehabilitation program was used for all patients, consisting of full load and active mobility exercises on the day of surgery (Fig. 1).

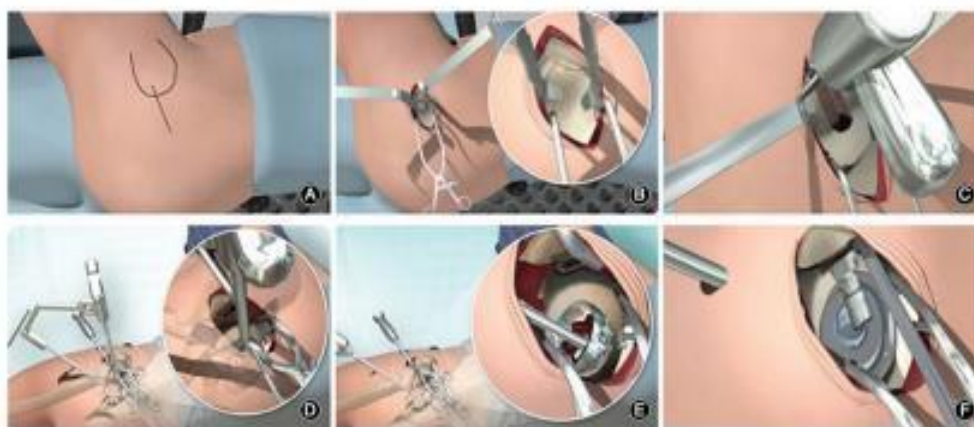


Fig. 1. Surgical steps of a THA with mini-invasive Super Path approach: a) surgical incision; b) articular capsule exposition; c) femoral neck osteotomy; d) percutaneous acetabular approach; e) acetabular reaming; f) prosthesis implant.

Postero lateral approach - Surgical technique

The patient is placed in lateral decubitus, and skin disinfection is performed, and then the surgical field is isolated with sterile drapes and covered with a transparent adhesive sheet; instrument connections are made, and a silk point is left as a repere for the length of the limb. The curvilinear incision is about 15 cm long and begins at 8 cm proximal to the greater trochanter, continues passing posterior to it, in line with the great gluteus, and once traversed in full, continues distally along the femoral diaphysis. The Fascia lata is dissected and passed along the lateral margin of the femur, exposing the vastus lateralis muscle; it continues in a proximal direction exposing the great gluteus muscle, dissected bluntly.

Pay attention to the superior and inferior gluteal arteries, and ligation should be done if necessary. The fibers of the great gluteus and the deep fascia of the thigh are spread apart, and the hip is rotated inward to expose the piriformis, internal obturator, twin, external obturator, and quadratus femoris muscles, and the sciatic nerve, whose common trunk is below the piriformis muscle, is moved away from the operative field. Near the quadratus femoris muscle, attention should be paid to the medial circumflex artery: if it bleeds, cauterization or ligation should be performed. Sutures are applied to the tendons of the piriformis and internal obturator, just before their insertion on the greater trochanter, and the femoral insertion of these muscles is detached, preserving the quadratus if possible. The dissected muscles are then reflected to cover and protect the nerve. This provides access to the posterior part of the joint capsule, which can be incised longitudinally or in a "T" shape. In this approach, the prosthetic design was identical with that seen with the Super path approach (MicroPort Orthopedics Inc., Arlington, TN, USA), with uncemented femoral stem, uncemented acetabular cup and highly cross-linked polyethylene liner.

Data measurement

As the primary endpoint, the Harris Hip Score was calculated to assess functional recovery. Pain management, need for transfusion, and hospital stay were evaluated as secondary endpoints. A prospective randomized controlled single-blind clinical trial was conducted.

Data were collected and analyzed. Continuous data were expressed as mean±SD. The chi-square test was used to compare materials and count rates. Comparison between two groups was performed using unpaired Student t-test. Paired t-test was used to compare values before and after treatment in one group. For all tests, a p-value less than 0.05 was considered statistically significant.

RESULTS

Sixty patients treated with THA were considered with 30 cases in the SuperPATH group and 30 cases in the conventional postero-lateral group. The mean age of patients in the SuperPATH group was 68.23±12.77 while in the conventional postero-lateral group was 66.46±11.00.

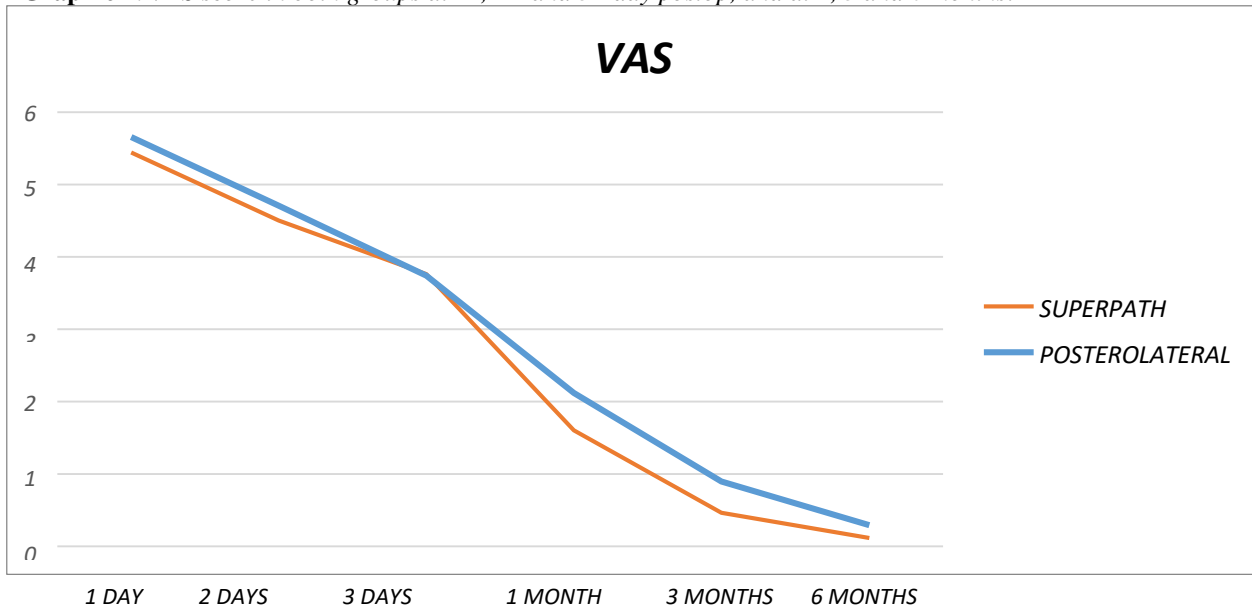
No significant difference was found in age, sex, BMI and other pathological types between the two groups. To compare the difference between the two groups, intraoperative indices including surgical time, mean blood loss and hospitalization time were analyzed. As shown in Table I, the average surgical time was significantly longer in the SuperPATH group than in the conventional group. Hospitalization time in the SuperPATH group was significantly shorter than in the conventional group (P<0.05).

Table I. Comparison between super path and posterolateral group for general demographic characteristics and intraoperative values.

Variables	Super Path group	Postero lateral group	P Value
Age (years)	68.23±12.77	66.46±11	0.425
BMC (Kg/m ²)	24.59±3.28	24.78±3.13	0.816
Surgical time (minutes)	99.73±12.04	73.16±15.48	0.182
Blood loss (mg/dL)	2.95±1.18	2.6±1.13	0.152
Hospitalization time (days)	6.2±1.54	7.6±3.2	<0.001

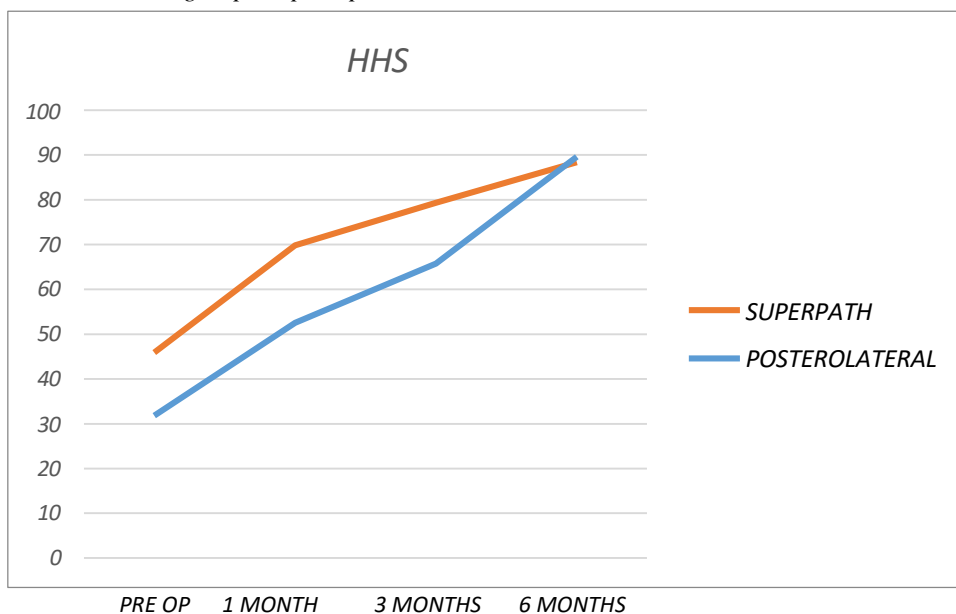
To compare postoperative recovery for hip function, HHS was assessed at 1 month, 3 months, and 6 months after surgery. After surgery, VAS scores decreased gradually and significantly, while Harris hip scores increased markedly and gradually compared with values before surgery (all $P < 0.05$). Analysis and evaluation of the VAS scores showed that they were significantly lower at 3 days after surgery with gradual decrease in score at 1 month and 3 months after surgery (Graphic 1).

Graphic 1. VAS score in both groups at 1st, 2nd and 3rd day postop, and at 1, 3 and 6 months.



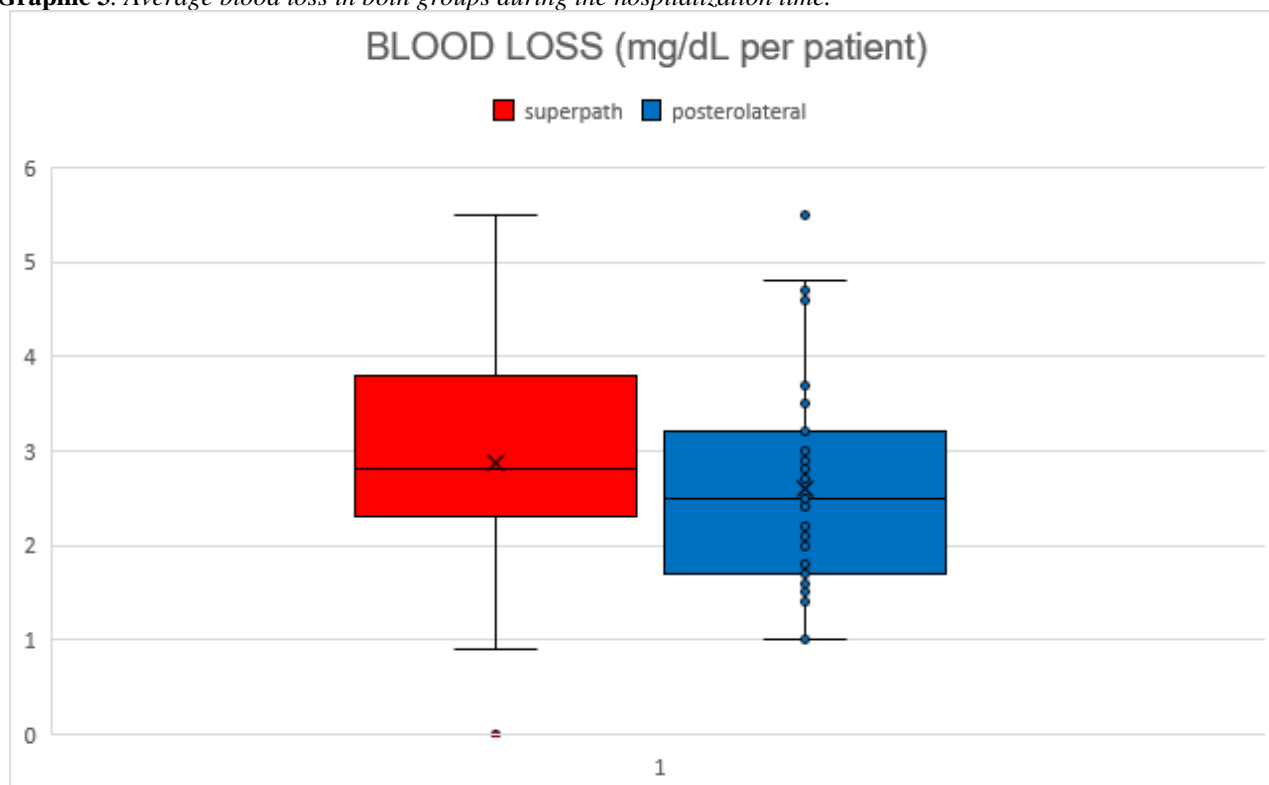
In contrast, the analysis of HHS scores showed that these were significantly higher in the SuperPATH group than in the conventional group ($P < 0.05$) at 1 month and 3 months after the intervention, while no significant difference was found at 6 months (Graphic 2).

Graphic 2. HHS score in both groups at pre-op, 1, 3 and 6 months.



On the contrary, blood loss was slightly higher in Super path group ($P=0,6585$) (Graphic 3).

Graphic 3. Average blood loss in both groups during the hospitalization time.



These results suggested that the SuperPATH approach promotes the speed of recovery for hip function and reduces pain in THA patients.

DISCUSSION

Currently, total hip arthroplasty is still the main treatment method for patients with ischemic necrosis of the femoral head, femoral neck fracture and coxarthrosis, especially for elderly patients.

However, postoperative THA recovery is still a clinical challenge (12). In recent years, the development of the minimally invasive SuperPATH approach has been gradually adopted in THA (8, 13). In this study, we demonstrated that the minimally invasive SuperPATH approach causes less intraoperative injury and is better for patients' postoperative recovery than the conventional posterolateral approach. The minimally invasive SuperPATH approach is a recently developed surgical method in THA. Several studies have already reported its efficacy and safety.

In Australian research, the authors showed that although complications existed in patients with the SuperPATH approach, dislocations were rare, and most patients could recover activity within 4 weeks (14).

In another research, good postoperative efficacy was found in 150 patients with SuperPATH approach in THA with only two subluxations, one wound dehiscence and one femoral diaphyseal fracture after surgery (12). In this study, it was also found that the SuperPATH approach in THA had good efficacy, with better speed of recovery of hip function, pain, and gait condition.

For conventional posterolateral approach in THA, there are already many related studies, however, only very few studies have reported the difference between SuperPATH approach and conventional posterolateral approach in THA. Rasuli et al. compared the surgical time, transfusion rates and average length of stay and found that the surgical time was significantly longer in SuperPATH patients, could be due to the different surgical group and experience compared with the reference (15).

In a recent study in 2020, Meng et al found that SuperPATH approach patients had shorter incision length, longer operative time, and higher blood loss and better hip function (16). Another study showed that early hip function and pain status recovered more quickly in patients with SuperPATH approach (17).

In the present study, it was observed that the SuperPATH approach facilitated recovery of hip function and pain, and better recovery of gait condition was found in patients with the SuperPATH approach. However, further studies are needed to confirm the results.

The Visual Analog Scale (VAS) was collected as a parameter of early pain relief. Early postoperative pain relief and rehabilitation are two of the potential benefits cited for immediate postoperative walking ability following a new minimally invasive approach. Several studies on the minimally invasive procedure for THA have reported less intraoperative blood loss, reduced pain, and improved rehabilitation (18).

Most patients enrolled, reported a reduction in pain that allowed them to walk as early as the first postoperative day. Functional rehabilitation was initiated and walking with supports was performed for all patients in the groups analyzed from the first postoperative day. In addition, a surprisingly high decrease in VAS was shown at 1 and 3 months postoperatively, VAS values at 6 months follow-up were extremely low and stable. Limitations of this study include lack of randomization, short-term follow-up, and lack of radiographic outcomes such as anteversion and abduction of the acetabular cup. Our study has several strengths.

This was performed in a single center, a single experienced surgeon performed all surgeries using one type of anesthesia, implant, pain program and rehabilitation. In the future, a larger sample will be collected to confirm the findings of this study with the updated scoring methods.

The present study was able to suggest that the SuperPATH approach in THA provides better efficacy in postoperative recovery and better pain tolerance in the immediate postoperative period. These results could provide further clinical evidence for the application of SuperPATH in THA.

REFERENCES

1. Learmonth ID, Young C, Rorabeck C. The operation of the century: total hip replacement. *Lancet*. 2007;370(9597):1508-1519. doi:[https://doi.org/10.1016/S0140-6736\(07\)60457-7](https://doi.org/10.1016/S0140-6736(07)60457-7)
2. Kurtz S, Ong K, Lau E, Mowat F, Halpern M. Projections of primary and revision hip and knee arthroplasty in the United States from 2005 to 2030. *J Bone Joint Surg Am*. 2007;89(4):780-785. doi:<https://doi.org/10.2106/JBJS.F.00222>
3. Higgins BT, Barlow DR, Heagerty NE, Lin TJ. Anterior vs. posterior approach for total hip arthroplasty, a systematic review and meta-analysis. *J Arthroplasty*. 2015;30(3):419-434. doi:<https://doi.org/10.1016/j.arth.2014.10.020>
4. Nelson SJ, Webb ML, Lukaszewicz AM, Varthi AG, Samuel AM, Grauer JN. Is Outpatient Total Hip Arthroplasty Safe? *J Arthroplasty*. 2017;32(5):1439-1442. doi:<https://doi.org/10.1016/j.arth.2016.11.053>
5. Gofton W, Chow J, Olsen KD, Fitch DA. Thirty-day readmission rate and discharge status following total hip arthroplasty using the supercapsular percutaneously-assisted total hip surgical technique. *Int Orthop*. 2015;39(5):847-851. doi:<https://doi.org/10.1007/s00264-014-2587-4>
6. Murphy SB, Tannast M. [Conventional vs minimally invasive total hip arthroplasty. A prospective study of rehabilitation and complications]. *Orthopade*. 2006;35(7):761-764, 766-768. doi:<https://doi.org/10.1007/s00132-006-0969-z>
7. Penenberg BL, Bolling WS, Riley M. Percutaneously assisted total hip arthroplasty (PATH): a preliminary report. *J Bone Joint Surg Am*. 2008;90 Suppl 4(209-220). doi:<https://doi.org/10.2106/JBJS.H.00673>
8. Cardenas-Nylander C, Bellotti V, Astarita E, Moya Gomez E, Fernandez MR. Innovative approach in total hip arthroplasty: supercapsular percutaneously-assisted. *Hip Int*. 2016;26 Suppl 1(34-37). doi:<https://doi.org/10.5301/hipint.5000409>
9. Sehat KR, Evans RL, Newman JH. Hidden blood loss following hip and knee arthroplasty. Correct management of blood loss should take hidden loss into account. *J Bone Joint Surg Br*. 2004;86(4):561-565.
10. Garcia-Rey E, Sirianni R, Garcia-Cimbrelo E, Sedel L. Total hip arthroplasty after acetabular fracture: does initial treatment make any difference to the outcome? A 5- to 23-year follow-up with clinical and radiological analysis. *Hip Int*. 2020;30(3):339-346. doi:<https://doi.org/10.1177/1120700019836413>
11. Bodrogi AW, Sciortino R, Fitch DA, Gofton W. Use of the supercapsular percutaneously assisted total hip approach for femoral neck fractures: surgical technique and case series. *J Orthop Surg Res*. 2016;11(1):113. doi:<https://doi.org/10.1186/s13018-016-0446-2>
12. Qurashi S, Chinnappa J, Aktas S, Dabboussi AM, Rahman MB. Overnight joint replacement surgery: a pilot Australian study. *ANZ J Surg*. 2022;92(10):2683-2687. doi:<https://doi.org/10.1111/ans.17977>
13. Quitmann H. Supercapsular percutaneously assisted (SuperPath) approach in total hip arthroplasty : Surgical technique and preliminary results. *Oper Orthop Traumatol*. 2019;31(6):536-546. doi:<https://doi.org/10.1007/s00064-019-0597-5>
14. Qurashi S, Chinnappa J, Lord SJ, Nazha A, Gordon J, Chow J. Driving After Microinvasive Total Hip Arthroplasty. *J Arthroplasty*. 2017;32(5):1525-1529. doi:<https://doi.org/10.1016/j.arth.2016.11.052>

15. Rasuli KJ, Gofton W. Percutaneously assisted total hip (PATH) and Supercapsular percutaneously assisted total hip (SuperPATH) arthroplasty: learning curves and early outcomes. *Ann Transl Med.* 2015;3(13):179. doi:<https://doi.org/10.3978/j.issn.2305-5839.2015.08.02>
16. Meng W, Huang Z, Wang H, et al. Supercapsular percutaneously-assisted total hip (SuperPath) versus posterolateral total hip arthroplasty in bilateral osteonecrosis of the femoral head: a pilot clinical trial. *BMC Musculoskelet Disord.* 2019;21(1):2. doi:<https://doi.org/10.1186/s12891-019-3023-0>
17. Wang XD, Lan H, Hu ZX, et al. SuperPATH Minimally Invasive Approach to Total Hip Arthroplasty of Femoral Neck Fractures in the Elderly: Preliminary Clinical Results. *Orthop Surg.* 2020;12(1):74-85. doi:<https://doi.org/10.1111/os.12584>
18. Migliorini F, Biagini M, Rath B, Meisen N, Tingart M, Eschweiler J. Total hip arthroplasty: minimally invasive surgery or not? Meta-analysis of clinical trials. *Int Orthop.* 2019;43(7):1573-1582. doi:<https://doi.org/10.1007/s00264-018-4124-3>

A RARE CASE OF SCALP ANGIOSARCOMA IN A PATIENT WITH SUPERIOR SAGITTAL SINUS MENINGIOMA

L.G.M. Di Somma¹, A. Mattioli¹, D. Aiudi¹, G. Goteri², N. Nersesian² and M. Dobran^{1*}

¹Department of Neurosurgery, Università Politecnica delle Marche, Ospedali Riuniti di Ancona, Italy;

²Division of Pathological Anatomy, Department of Biomedical Sciences and Public Health, Polytechnic University of Marche di Ancona, Italy

*Correspondence to:

Mauro Dobran, MD
Department of Neurosurgery,
Università Politecnica delle Marche,
Via Conca 71,
60020, Ancona, Italy
e-mail: m.dobran@staff.univpm.it

ABSTRACT

Cutaneous angiosarcoma (CAS) is a rare but highly aggressive sarcoma of mesenchymal origin with a high mortality rate. The most affected sites of CAS are the scalp and facial skin. The 85-year-old patient, in follow-up for posterior parasagittal meningioma for several years, developed a single violaceous and ulcerated scalp lesion. The CT cerebral angio revealed, beyond the well-known meningioma, an area of bone rarefaction associated with ulcerated tissue infiltrating the skin and subcutaneous layers. After surgical biopsy, the histological examination documented a scalp angiosarcoma. The oncological treatment was not possible, given the age. The patient was referred to the plastic surgeon and underwent serial medication. The patient made a good functional recovery but died six months later due to a pulmonary embolism. This paper discusses the correlation between the scalp's angiosarcoma disease and the presence of the parasagittal meningioma.

KEYWORDS: *scalp angiosarcoma, sagittal sinus meningioma, head and neck tumor*

INTRODUCTION

Angiosarcomas of the head and neck represent about 15% of all head and neck sarcomas and 1% of all soft tissue sarcomas, most commonly arising on the scalp. Angiosarcomas originate from blood or lymphatic vessels and show a propensity for insidious local infiltration, for which they are considered aggressive tumors that recur both locally and distantly, with a risk of spreading through draining lymphatics. Given the rarity of this disease, there is limited evidence for its pathogenesis, primarily derived from case series. Angiosarcomas' aggressive behaviour causes estimated survival rates at 5 and 10 years are 34% and 14%, respectively.

There is considerable literature evidence supporting the hypothesis of the collateral veins pathway and vascular rearrangement forming in the presence of a superior sagittal sinus neoplasm. In this rare case, the authors suggest a cause/effect relationship between the superior sagittal sinus (SSS) meningioma with the superficial vessel remodeling and the scalp angiosarcoma.

The rarity of this malignant tumor and its association with a neoplasm of the intracranial district make this case even more striking, as far as it has been reported. Furthermore, it may represent food for thought for studying angiosarcomas' biological and histological behaviour.

CASE PRESENTATION

An 85-year-old man was clinically and radiologically followed up since 2009 for a right-sided parietal parasagittal extra-axial lesion, likely a meningioma (Fig. 1).

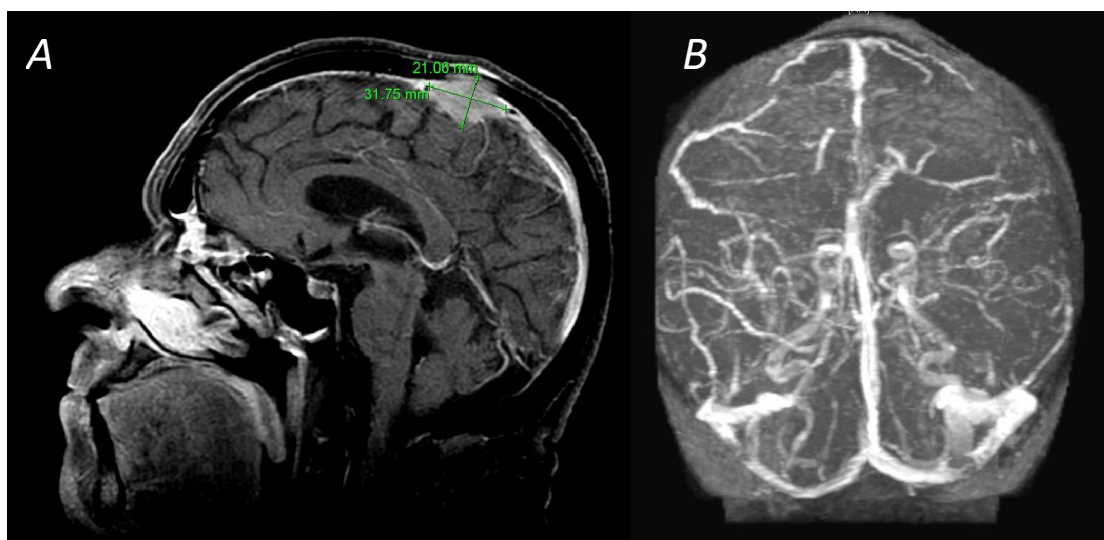


Fig. 1. Enhanced MRI showing the superior sagittal sinus neoformation and angio-MRI highlighting the blood flow interruption in correspondence of the lesion.

Because of the small dimensions and its slow growth over the years, a conservative conduct was adopted, even though a progressive and eventually complete sagittal sinus obliteration was observed after 3 years of diagnosis. Moreover, the neurological examination showed no disturbances. After an 11-year follow-up, cutaneous bleeding ulceration appeared on the left frontal area of the scalp (Fig. 2).

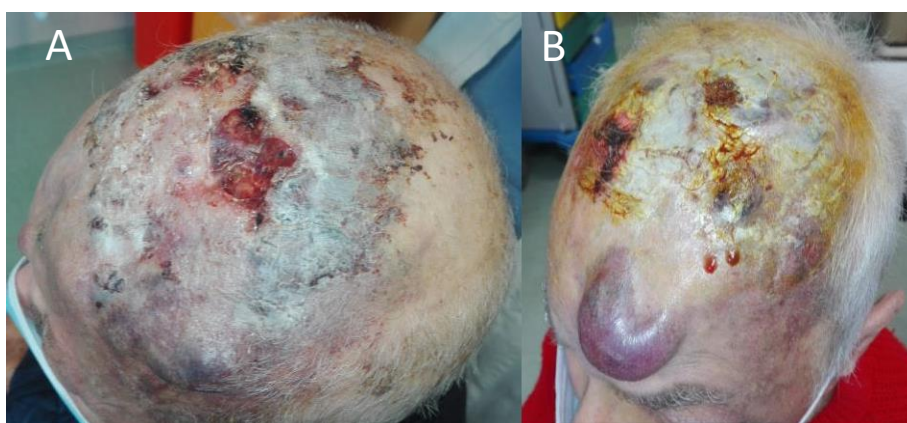


Fig. 2. Ulcerated bleeding scalp lesion.

Since he was under anticoagulant therapy for atrial fibrillation, anticoagulant therapy was suspended to gain better control of the bleeding and therapy with sodium heparin started. A new head CT scan with 1 mm 3D bone reconstructions revealed a considerable osteorarefaction area in correspondence with the known meningioma associated with a soft epicranial tissue infiltration (Fig. 3).

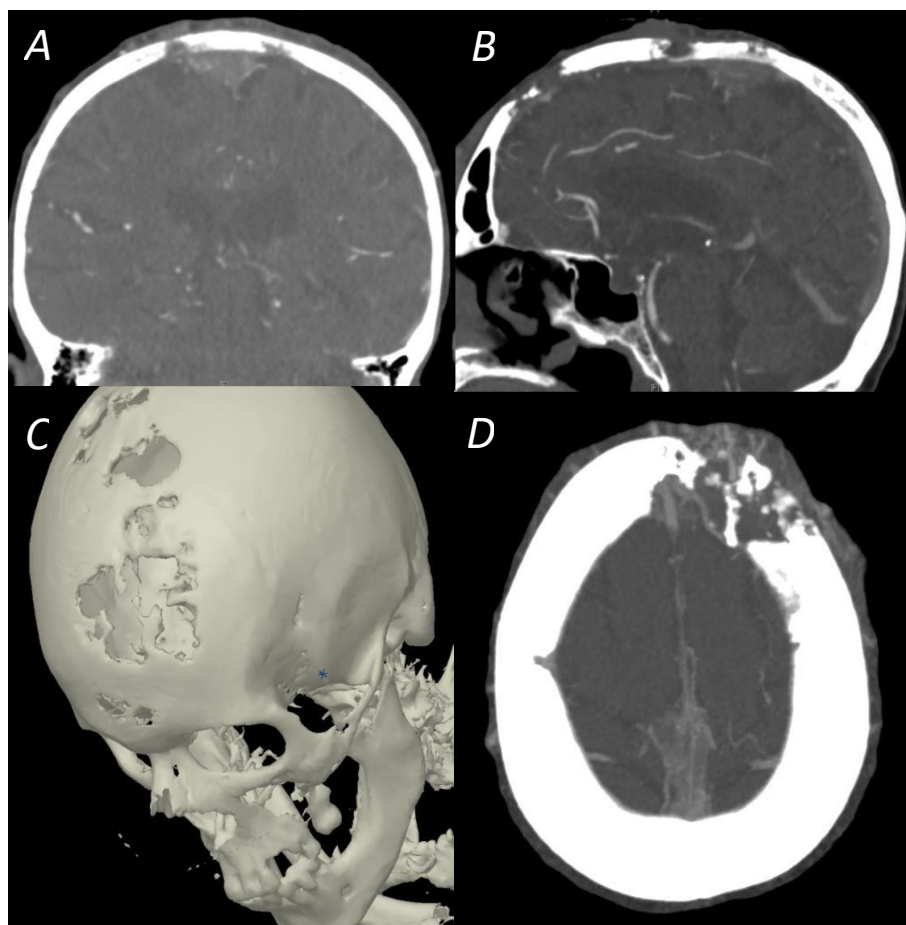


Fig. 3. CT scan with bone windowing shows bony resorption areas.

Considering the patient's global clinical conditions and comorbidities, no surgical indications were given, and the patient was referred to the plastic surgeon and underwent serial medications. A biopsy of the ulcerated tissue was performed, and the histological examination documented a scalp angiosarcoma. The tumor was composed of spindle cell proliferation with the formation of vascular solid areas, with positive immunohistochemical tests for CD34 and ERG negative for HHV8 (Fig 4).

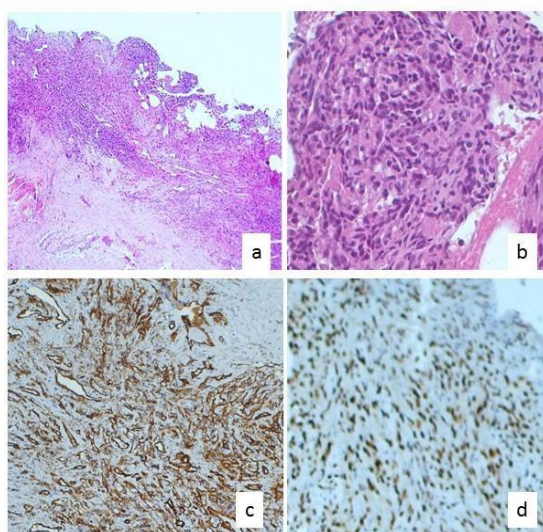


Fig. 4. Tumor composed by spindle cell proliferation with formation vascular solid areas, with positive immunohistochemical tests for CD34 and ERG negative for HHV8.

Radiotherapy was indicated to control the lesion size, but the poor patient's general conditions did not allow the treatment. The patient's overall survival was 6 months from the diagnosis, during which the patient experienced a good quality of life. In the last ten days, his clinical conditions suddenly became critical, causing a pulmonary embolism with rapid exits.

DISCUSSION

In literature, malignant tumors occurring on the scalp are reported as 1.4%-2% of all skin cancers, generally involving middle-aged and elderly individuals, and the differential diagnosis includes mainly basal cell and squamous cell carcinoma, malignant melanoma, and, most rarely, angiosarcoma.

Our study aims to find a correlation between the formation of the scalp collateral veins and their potential contribution to angiosarcoma's pathogenesis. When in the presence of a neoplasm infiltrating the superior sagittal sinus, a collateral venous circulation generates (to supply the cerebral territories otherwise lacking a venous drain and to bypass the obstruction site). The haemodynamic changes produce a global decrease of the oxygen partial pressure in the venous circulation to establish a hypoxic micro-environment that may represent the starting point of a tumoral progression pathway. Maeda et al. reported that hypoxia enhanced angiosarcoma cells' proliferation, migration, and invasion ability (1). These findings suggested that the hypoxic tumor environment worsened the immune escape of angiosarcoma. Moreover, hypoxia increases angiopoietin-2 production, which results in abnormal angiogenesis in the presence of VEGF-A and vascular imbalance (2-4). Based on these experimental data using both clinical samples and cultured angiosarcoma cells, they enlightened the clinical importance of hypoxia in angiosarcoma.

Collateral scalp vein formation in the presence of a superior sagittal sinus neoplasm is a well-known phenomenon widely reported in the literature (5). Waga et al. (6) observed an abnormal filling of scalp veins in carotid angiograms in the following conditions: a) arteriovenous malformations (AVM) of the scalp; b) malignant tumors involving the scalp and skull; c) shunt blood into the dural venous sinus causing the pressure in the sinus to be increased (intracranial AVM and others); d) SSS occlusion with parasagittal meningiomas and venous sinus thrombosis (7, 8).

In scalp collateral veins, the pO_2 value is lower because of the venous engorgement produced by the small calibre vessels of the superficial scalp veins (temporal superficial vein, occipital vein, posterior auricular vein with final drain in the external jugular vein).

When the invasion leads to SSS stenosis or occlusion, venous collaterals are established via three known pathways: 1) collaterals connect the two ends of the occluded segment of the SSS; 2) collaterals bypass the occluded segment of the SSS but connect with a superficial venous system; 3) collateral bypass the occluded segment of the SSS but connect with a deep venous system.

Wollschaeger et al. (9) examined the rush of blood through dural infiltrating lesions (scalp basal cell carcinoma and para-falcine meningioma) with a selective external carotid angiography. They suggested that the relative stasis of the contrast material within the dural vessels could be explained by the growing resistance and encumbered redundancy of capillaries within the lesion, whose peripheral vascular resistance resulted in decreased. Therefore, primarily dural lesion such a meningioma may determine prolongation and stasis of dural circulation.

Waga et al. reported 3 cases of parasagittal meningiomas occluding the SSS supplied by the scalp collateral veins (6). The phlebogram of the internal carotid artery showed that veins placed anteriorly and posteriorly to the obstruction site drained mainly in a dilated vein in the posterior frontal region, descending in the pre-auricular region and finally in the retro-mandibular vein. The dilated scalp vein was a superficial temporal vein, receiving blood through emissary veins from the patent portion of the SSS. Even seen with the naked eye during surgery, they were markedly dilated and descended from the biparietal bony prominences down to the pre-auricular regions. The author describes an interesting case of a patient previously diagnosed of occipital region sarcoma, subsequently undergone surgery for a voluminous angioblastic meningioma of the occipital region infiltrating and occluding the SSS on its posterior third. The phlebograms showed several scalp veins connected with the SSS via emissary veins, all joined together and became a single vein, the superficial temporal vein, draining in the external jugular veins through the retro-mandibular vein.

In our case the scalp venous collateral circulation developed in presence of the SSS obstruction with relative blood flow stasis and hypoxia may have triggered the oncogenesis of the angiosarcoma. Our hypothesis should be investigated with an eventual confirmation by further biomolecular and oncological studies.

REFERENCES

1. Maeda-Otsuka S, Kajihara I, Tasaki Y, et al. Hypoxia accelerates the progression of angiosarcoma through the regulation of angiosarcoma cells and tumor microenvironment. *J Dermatol Sci*. 2019;93(2):123-132. doi:<https://doi.org/10.1016/j.jdermsci.2019.01.005>
2. Potente M, Gerhardt H, Carmeliet P. Basic and therapeutic aspects of angiogenesis. *Cell*. 2011;146(6):873-887. doi:<https://doi.org/10.1016/j.cell.2011.08.039>
3. Hegen A, Koidl S, Weindel K, Marme D, Augustin HG, Fiedler U. Expression of angiopoietin-2 in endothelial cells is controlled by positive and negative regulatory promoter elements. *Arterioscler Thromb Vasc Biol*. 2004;24(10):1803-1809. doi:<https://doi.org/10.1161/01.ATV.0000140819.81839.0e>
4. Maisonpierre PC, Suri C, Jones PF, et al. Angiopoietin-2, a natural antagonist for Tie2 that disrupts in vivo angiogenesis. *Science*. 1997;277(5322):55-60. doi:<https://doi.org/10.1126/science.277.5322.55>
5. Yin T, Zhang H, Wang W, Zhang L, Wang S. Falcine Sinus and Parafalcine Collateral Veins in Meningiomas Invading the Superior Sagittal Sinus. *World Neurosurg*. 2019;132(e434-e442). doi:<https://doi.org/10.1016/j.wneu.2019.08.120>
6. Waga S, Handa H. Scalp veins as collateral pathway with parasagittal meningiomas occluding the superior sagittal sinus. *Neuroradiology*. 1976;11(4):199-204. doi:<https://doi.org/10.1007/BF00346079>
7. Ray BS, Dunbar HS, Dotter CT. Dural sinus venography as an aid to diagnosis in intracranial disease. *J Neurosurg*. 1951;8(1):23-37. doi:<https://doi.org/10.3171/jns.1951.8.1.0023>
8. Lerner MA. The angiographic evaluation of the calvarial impressions and channels, and the clinical significance of the parasagittal sinusoidal cerebral veins. *Clin Radiol*. 1969;20(2):157-165. doi:[https://doi.org/10.1016/s0009-9260\(69\)80164-9](https://doi.org/10.1016/s0009-9260(69)80164-9)
9. Wollschlaeger PB, Wollschlaeger G, Toalson LD. Prolongation and stasis of the dural circulation. *Radiology*. 1970;94(1):19-23. doi:<https://doi.org/10.1148/10.1148/94.1.19>

Evaluation Study

TREATMENT OF RHIZARTRHOSIS WITH OXYGEN-OZONE THERAPY: OUR EXPERIENCE

M. Bonetti¹, G. Bragaglio², G. Guarino², I. Marchina², G.M. Ottaviani³, M. Moretti² and G. Tabaracci⁴

¹ Department of Neuroradiology, Istituto Clinico Città di Brescia, Brescia, Italy;

² Oberdan Specialistic Clinic, Brescia, Italy;

³ Emergency and Urgency Department, Spedali Civili di Brescia, Brescia, Italy;

⁴ San Rocco Specialistic Clinic, Montichiari, Brescia, Italy

*Correspondence to:

Matteo Bonetti, MD

Department of Neuroradiology,

Istituto Clinico Città di Brescia,

Via Gualla, 15,

25128 Brescia, Italy

e-mail: dottorbonetti@gmail.com

ABSTRACT

In recent years, the number of reports on the use of oxygen-ozone therapy for treating acute and chronic inflammatory joint disease has been constantly increasing. In this study, we report our experience in the treatment of rhizarthrosis. From March 2018 to February 2019, 27 patients (21 females and 6 males aged 58 to 79 years, mean age 67.8 years) were enrolled. They were affected by rhizarthrosis. The diagnosis was confirmed by clinical examination and radiographic findings from standard metacarpal trapezius joint radiograms. Of the 27 treated patients, the clinical result was excellent in 16 (59%), in 5 it was satisfactory (19%), while in the remaining 6 no clinical benefit was obtained (22%). Although our series is currently limited to only 27 patients, we believe oxygen-ozone therapy in the treatment of metacarpal trapezius rhizarthrosis represents a valid therapeutic option instead of the use of drugs such as NSAIDs and/or steroids, especially in the first phase of the disease.

KEYWORDS: *rhizarthrosis, thumb, osteoarthritis, trapeziometacarpal, joint*

INTRODUCTION

Rhizarthrosis is a degenerative-arthritis process that affects the joint of the base of the thumb (1, 2). The endurance of pain and the significant deficit of strength between thumb and forefinger can interfere with daily tasks such as – for example – turning a key, opening a car door, picking up a book, threading a thread through the loop of a needle; objects may fall from the grip of hands and night resting may be prevented. All these factors can cause a lack of autonomy, decreasing the overall quality of life (3, 4). Rhizarthrosis most frequently affects one side, and women over 40 are more likely to be affected by this pathology (1-4).

Conservative treatment involves administering anti-inflammatory drugs and braces that temporarily immobilize the joint or intra-articular infiltrations with cortisone. From a therapeutic point of view, using a specific handheld device may be useful to keep the joint locked, at least during the night. Simple analgesics such as paracetamol and, in the most painful phases, non-steroidal anti-inflammatory drugs can also be useful (5-17).

Received: 29 March 2023
Accepted: 02 May 2023

Copyright © by LAB srl 2023

This publication and/or article is for individual use only and may not be further reproduced without written permission from the copyright holder. Unauthorized reproduction may result in financial and other penalties. Disclosure: All authors report no conflicts of interest relevant to this article.

There are also some reports on the effectiveness of local infiltrative therapy with hyaluronic acid (18-20). In case of failure, surgery is performed. The surgery that currently provides the most significant therapeutic success is the so-called biological arthroplasty (21, 22).

In light of the recent results reported in the literature on the use of oxygen-ozone therapy to treat acute and chronic inflammatory pathology of small and large joints (23-32), we treated 27 patients suffering from arthrosis (Fig. 1).

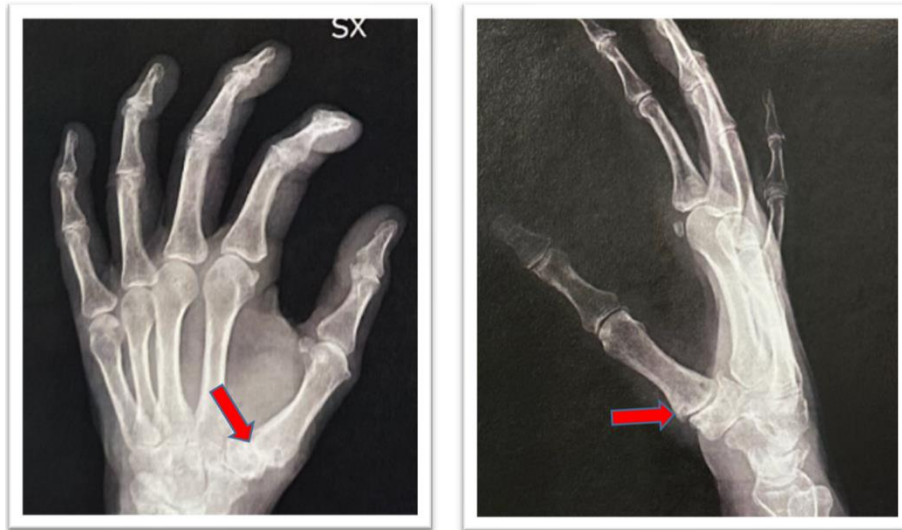

Fig. 1. (A-B): radiographic diagnosis of rhizarthrosis (arrows). **A**): oblique projection and **B**): Kapandji projection for the evaluation of the joints of base of the thumb.

MATERIALS AND METHODS

From March 2018 to February 2019, 27 patients with a diagnosis of rhizarthrosis confirmed both by clinical examination and by radiographic findings with standard radiograms of the hand (Fig. 1) were enrolled. Specifically, 21 females and 6 males aged between 58 and 79 (mean age 67.8 years). All treatments were carried out using needles 25 G 5/8 Terumo orange colour code (Fig. 2).

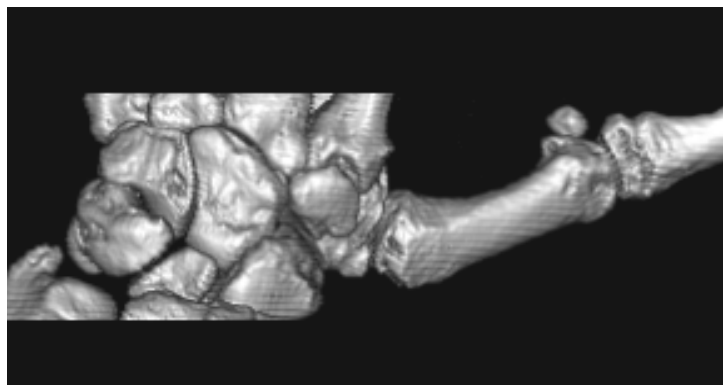


Fig. 2. 3D CT reconstruction of the metacarpal trapezium joint: rhizarthrosis.

After signing an informed consent, all patients underwent a local infiltration with oxygen-ozone at a concentration of 20 micrograms/ml. The first treatment was delivered using the CT guide to allow perfect access to the joint. Local anaesthesia was performed with ethyl chloride spray, and then, again using the CT guide, the needle of 25 G was inserted in the joint (Fig. 3).

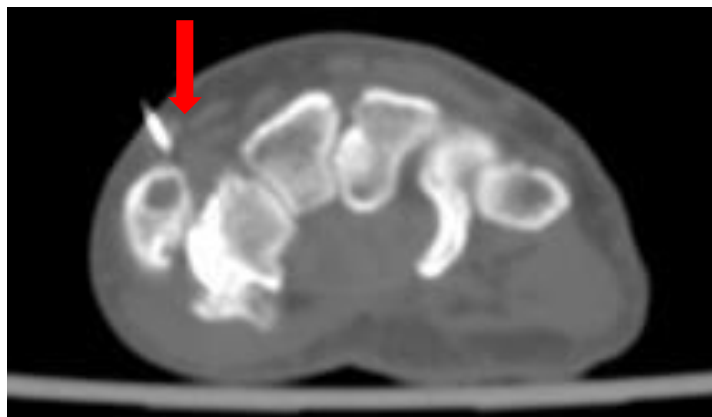


Fig. 3. Preliminary CT scan: checking the positioning of the 25G needle (arrow).

Once the entry point had been correctly identified, it was marked with a demographic pencil and kept constant for subsequent treatments. A 5 ml syringe in polyethylene was then filled with the gaseous mixture at a 20 $\mu\text{g/ml}$ concentration. The gaseous mixture was then injected, generally using a variable volume from 3 cc to 5 cc of the $\text{O}_2\text{-O}_3$ gaseous mixture. All materials used must be sterile and single-use. After the infiltration, other CT scans were performed to document the correct distribution of the gaseous mixture. (Fig 4).

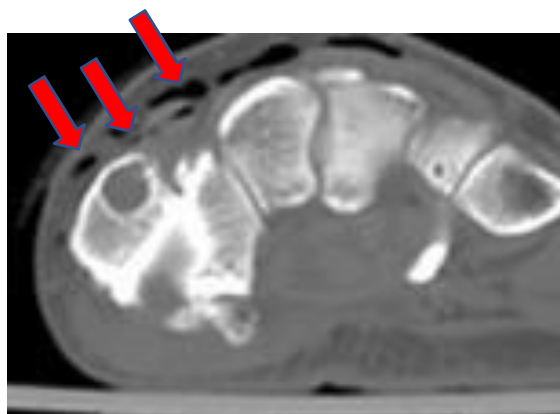

Fig. 4. TC control of the distribution of the gaseous mixture (arrows).

An average of 6 to 10 infiltrations of the metacarpal trapezium joint every two weeks were performed depending on the severity of the case treated. In particular, in 6 patients, we performed six injections, in 12 eight infiltrations, and in the remaining 9 ten applications. Having to treat an extremely sensitive region, local anaesthesia with ethyl chloride spray was always performed. Infiltration was always well tolerated by patients.

RESULTS

All patients included in the study were clinically evaluated one month after the end of the therapy. During the treatment period, any anti-inflammatory therapy was stopped. Instead, patients continued to use the brace. Therefore, only 8 out of 27 patients continued to take advantage of the brace.

Among 27 treated patients, there were excellent, satisfactory and poor results in 16 (59%), 5 (19%) and 6 (22%) subjects, respectively. Clinical results were evaluated one month after the end of treatment. Excellent results were those with almost complete disappearance of painful symptoms; satisfactory results were those where patients reported only a partial remission of painful symptoms; poor results were those with no clinical benefit. These last were referred to orthopaedics for a further therapeutic decision.

DISCUSSION

In rhizarthrosis, the arthrosis process causes the cartilage that lines the two bones in contact (trapezius and first metacarpal bone) to become thinner; this process causes further friction, wear and pain. It is challenging to translate the intensity of pain reported by the patient in an objective evaluation of the joint condition. In fact, significantly compromised clinical pictures at radiographic control are often associated with a very low impact on the patient's activity, while, in other cases, early stages can be extremely troublesome and cause severe functional deficits. The main symptom is pain, which appears when the patient performs simple gripping and gripping movements with the thumb (1-4).

Pain can also appear spontaneously with the change of weather, especially in the presence of humidity. Pain is also awakened by direct pressure on the joint at the base of the thumb or by grabbing the thumb and pushing it towards the wrist. Over time, the reduction of the force expressed during gripping becomes more and more marked, and pain appears while carrying out light manual activities more and more.

The characteristic of rhizarthrosis is also the appearance in the initial stages of swelling at the base of the thumb, followed by progressive displacement of the base outwards. no consensus has emerged in the literature regarding a single effective protocol for conservative treatment, and in the literature, there are few works compared to what is proposed for the surgical techniques (1-23).

The therapy involves keeping the joint at rest through braces and treatment with non-steroidal anti-inflammatory drugs (NSAIDs), generally at full dosage for an adequate period. Intra-articular infiltrative therapy with corticosteroids is also possible. Sometimes, physical therapy is associated (ultrasound, iontophoresis, etc.). Rarely is there an indication of surgical treatment utilizing arthroplasty (4-23).

In light of our experience in oxygen-ozone therapy treatments in various musculoskeletal districts, we used this type of treatment for analgesic purposes also in rhizarthrosis. The mechanisms of action of the oxygen-ozone gas mixture are well-known and widely documented in the literature (23-32). The rationale for intra-articular oxygen-ozone infiltration is based on relieving inflammation with subsequent analgesic action. The oxygen-ozone gas mixture injected normalizes the level of cytokines and prostaglandins, increases superoxide dismutase, minimizes reactive oxidant species and improves local circulation with a eutrophic effect.

CONCLUSIONS

Although the reported case series is based on evaluating only 27 patients, we believe oxygen-ozone therapy in treating metacarpal trapezius rizarthrosis is a valid therapeutic option, especially in the first phase of the disease. It can be used instead of other drugs, such as NSAIDs and/or steroids. The good results obtained in our series are related to some of the main activities of oxygen-ozone therapy: the intra and trans-tissue oxygenation with consequent improvement of both hypoxia and ozone's anti-inflammatory, analgesic and eutrophic activities.

In conclusion, oxygen-ozone therapy can be considered an excellent therapeutic approach for patients afflicted with rizarthrosis.

REFERENCES

1. Saheb RLC, Vaz BADS, Soeira TP, Shimaoka FJ, Herrero CFPDS, Mazzer N. Surgical treatment for rhizarthrosis: a systematic review of the last 10 years. *Acta Ortopédica Brasileira*. 2022;30(1). doi:<https://doi.org/10.1590/1413-785220223001e246704>
2. Chevalier X, Maheu E. [Rhizarthrosis]. *La Revue Du Praticien*. 2012;62(5):639.
3. Verrijdt G, De Landtsheer A, Mellen A, Godderis L. Rhizarthrosis in banknote processing workers: a retrospective cohort study. *Occupational Medicine*. 2017;67(8):615-620. doi:<https://doi.org/10.1093/occmed/kqx144>
4. Aita MA, Alves RS, Longuino LF, Ferreira CHV, Ikeuti DH, Rodrigues LMR. Measurement of quality of life among patient undergoing arthroplasty of the thumb to treat CMC arthritis. *Revista Brasileira de Ortopedia (English Edition)*. 2016;51(4):431-436. doi:<https://doi.org/10.1016/j.rboe.2016.06.003>
5. Roux CH, Euller-Ziegler L. Injections for treatment of carpometacarpal osteoarthritis (rhizarthrosis): What is the evidence? *Joint Bone Spine*. 2016;83(2):125-126. doi:<https://doi.org/10.1016/j.jbspin.2015.04.012>
6. Szalay G, Scheufens T, Alt V, Boecker W, Schnettler R. Die operative Versorgung der therapierefraktären Rhizarthrose mittels Trapezektomie und Suspension des ersten Strahls mittels Mini TightRope®. *Handchirurgie Mikrochirurgie Plastische Chirurgie*. 2014;46(03):179-185. doi:<https://doi.org/10.1055/s-0034-1368715>
7. Dreiser RL, Gersberg M, Thomas F, Courcier S. [Ibuprofen 800 mg in the treatment of arthrosis of the fingers or rhizarthrosis]. *Revue Du Rhumatisme (Ed Francaise: 1993)*. 1993;60(11):836-841.

8. J Jurča, M Nĕmejc, Havlas. Surgical Treatment for Advanced Rhizarthrosis. Comparison of Results of the Burton-Pellegrini Technique and Trapeziometacarpal Joint Arthroplasty. *Acta Chirurgiae Orthopaedicae Et Traumatologiae Cechoslovaca*. 2016;83(1):27-31. doi:<https://doi.org/10.55095/achot2016/004>
9. Russo S, Bernasconi A, Busco G, Sadile F. Treatment of the trapeziometacarpal osteoarthritis by arthroplasty with a pyrocarbon implant. *International Orthopaedics*. 2015;40(7):1465-1471. doi:<https://doi.org/10.1007/s00264-015-3016-z>
10. Fuchs S, Mönikes R, Wohlmeiner A, Heyse T. Intra-articular hyaluronic acid compared with corticoid injections for the treatment of rhizarthrosis. *Osteoarthritis and Cartilage*. 2006;14(1):82-88. doi:<https://doi.org/10.1016/j.joca.2005.07.016>
11. Bohr S, Rennekampff HO, Pallua N. Cell-Enriched Lipoaspirate Arthroplasty: A Novel Approach to First Carpometacarpal Joint Arthritis. *Hand Surgery*. 2015;20(03):479-481. doi:<https://doi.org/10.1142/s0218810415720259>
12. Ingegnoli F, Soldi A, Meroni P. Power Doppler Sonography and Clinical Monitoring for Hyaluronic Acid Treatment of Rhizarthrosis: A Pilot Study. *Journal of Hand and Microsurgery*. 2016;03(02):51-54. doi:<https://doi.org/10.1007/s12593-011-0037-8>
13. Jaminet P, Kraus A, Manoli T, Werdin F, Schaller HE, Nektarios Sinis. Accidental median nerve injury during trapezium resection and ligament reconstruction for primary rhizarthrosis. *Microsurgery*. 2010;30(6):502-504. doi:<https://doi.org/10.1002/micr.20768>
14. Gwendoline De Fleurian. Étude d'un cas de rhizarthrose parmi les pêcheurs de poulpes en Méditerranée. *La Presse Médicale*. 2010;39(3):398-402. doi:<https://doi.org/10.1016/j.lpm.2009.11.009>
15. Karalezli N, Ogun TC, Kartal S, Saracgil SN, Yel M, Tuncay I. The pain associated with intraarticular hyaluronic acid injections for trapeziometacarpal osteoarthritis. *Clinical Rheumatology*. 2006;26(4):569-571. doi:<https://doi.org/10.1007/s10067-006-0354-7>
16. Valentino M, Rapisarda V. [Rhizarthrosis of the thumb in ironing workers]. *La Medicina Del Lavoro*. 2002;93(2):80-86.
17. Arnaud Dupeyron, Ehrler S, Marie-Eve Isner-Horobeti. Rhizarthrose et orthèse. Revue de la littérature. *Ann Readapt Med Phys*. 2001;44(3):123-131. doi:[https://doi.org/10.1016/s0168-6054\(01\)00074-5](https://doi.org/10.1016/s0168-6054(01)00074-5)
18. Monfort J, Rotés-Sala D, Segalés N, et al. Comparative efficacy of intra-articular hyaluronic acid and corticoid injections in osteoarthritis of the first carpometacarpal joint: Results of a 6-month single-masked randomized study. *Joint Bone Spine*. 2015;82(2):116-121. doi:<https://doi.org/10.1016/j.jbspin.2014.08.008>
19. Cormier G, Le Goff B, Denis A, et al. Corticosteroids injections versus corticosteroids with hyaluronic acid injections in rhizarthrosis: the randomised multicentre RHIZ'ART trial study protocol. *BMJ Open*. 2019;9(1):e022553. doi:<https://doi.org/10.1136/bmjopen-2018-022553>
20. Fuchs S, Erbe T, Fischer HL, Tibesku CO. Intraarticular Hyaluronic Acid versus Glucocorticoid Injections for Nonradicular Pain in the Lumbar Spine. *Journal of Vascular and Interventional Radiology*. 2005;16(11):1493-1498. doi:<https://doi.org/10.1097/01.rvi.0000175334.60638.3f>
21. Martínez-Martínez F, García-Hortelano S, García-Paños JP, Moreno-Fernández JM, Martín-Ferrero MÁ. Estudio clínico comparativo de 2 técnicas quirúrgicas de rizartrosis del pulgar. *Revista Española de Cirugía Ortopédica y Traumatología*. 2016;60(1):59-66. doi:<https://doi.org/10.1016/j.recot.2015.05.005>
22. Luther C. Handchirurgie [Hand surgery. Surgery in rhizarthrosis: prospective comparison]. *Unfallchirurg*. 2013;116(10):868-869. doi:<https://doi.org/10.1007/s00113-013-2510-2>
23. Giombini A, Menotti F, Di Cesare A, et al. Comparison between intrarticular injection of hyaluronic acid, oxygen ozone, and the combination of both in the treatment of knee osteoarthritis. *Journal of Biological Regulators and Homeostatic Agents*. 2016;30(2):621-625.
24. Muto M, Giurazza F, Silva RP, Guarnieri G. Rational approach, technique and selection criteria treating lumbar disk herniations by oxygen-ozone therapy. *Interventional Neuroradiology*. 2016;22(6):736-740. doi:<https://doi.org/10.1177/1591019916659266>
25. Murphy KJ, Elias GJB, Steppan J, et al. Percutaneous Treatment of Herniated Lumbar Discs with Ozone: Investigation of the Mechanisms of Action. *Journal of Vascular and Interventional Radiology*. 2016;27(8):1242-1250.e3. doi:<https://doi.org/10.1016/j.jvir.2016.04.012>
26. Bonetti M, Zambello A, Leonardi M, Princiotta C. Herniated disks unchanged over time: Size reduced after oxygen-ozone therapy. *Interventional Neuroradiology*. 2016;22(4):466-472. doi:<https://doi.org/10.1177/1591019916637356>
27. Chen H, Yu B, Lu C, Lin Q. The effect of intra-articular injection of different concentrations of ozone on the level of TNF- α , TNF-R1, and TNF-R2 in rats with rheumatoid arthritis. *Rheumatology International*. 2012;33(5):1223-1227. doi:<https://doi.org/10.1007/s00296-012-2529-7>
28. Yu B, Chen H, Lu C, Lin Q, Wang B, Qin C. [Effect of intra-articular ozone injection on serum and synovial TNF- α , TNFR I, and TNFR II contents in rats with rheumatoid arthritis]. *Nan Fang Yi Ke Da Xue Xue Bao*. 2011;31(6):1055-1058.
29. Bonetti M, Fontana A, Martinelli F, C.F. Andreula. Oxygen-Ozone Therapy for Degenerative Spine Disease in the Elderly: A Prospective Study. *Acta neurochirurgica*. 2010;108:137-142. doi:https://doi.org/10.1007/978-3-211-99370-5_21
30. Bonetti M, Fontana A, Cotticelli B, Volta GD, Guindani M, Leonardi M. Intraforaminal O(2)-O(3) versus periradicular steroidal infiltrations in lower back pain: randomized controlled study. *AJNR American journal of neuroradiology*. 2005;26(5):996-1000.
31. Bonetti M, Fontana A, Albertini F. CT-guided oxygen-ozone treatment for first degree spondylolisthesis and spondylolysis. *Springer eBooks*. 2005;92:87-92. doi:https://doi.org/10.1007/3-211-27458-8_19

-
32. Perri M, Grattacaso G, Di Tunno V, et al. MRI DWI/ADC signal predicts shrinkage of lumbar disc herniation after O2–O3 discolysis. *The Neuroradiology Journal*. 2015;28(2):198-204. doi:<https://doi.org/10.1177/1971400915576658>

Case Report

PALMITOYLETHANOLAMIDE M/UM REPRESENTS AN INNOVATIVE NUTRITIONAL APPROACH IN THE MANAGEMENT OF POST-OPERATIVE BONE PAIN: PRELIMINARY RESULTS

F. Riefoli, A. Carlet, M. D'Aprile, S. Manto, L. Scaramuzzi and G. Solarino

University of Study of Bari, Aldo Moro, Orthopedic Unit, Department of Translational and Neuroscience, Bari, Italy

Correspondence to:

Flavia Riefoli, MD
Orthopedic and Trauma Unit,
Department Of Basic Medical Sciences,
Neuroscience And Sense Organs,
School Of Medicine,
University Of Bari "Aldo Moro",
Aou Consorziiale "Policlinico",
Piazza Giulio Cesare 11,
70100 Bari, Italy
e-mail: flaviaok91@gmail.com

ABSTRACT

Distal radius fractures are among the most common skeletal injuries of the wrist. Although the surgical treatment with a volar plate allows rapid and complete functional recovery, most patients experience significant pain when performing movements in the post-operative period. Two clinical cases of patients undergoing reduction and osteosynthesis surgery with volar-locking plate after wrist fracture and treated with micronized (PEAm) and ultramicronized PEA (PEAum) (300 mg + 600 mg) twice daily for 30 days. Pain and functional recovery were assessed 1, 7, 14, 21 and 30 days are here reported after surgery and, subsequently, 30 days after the end of treatment by the NRS scale and DASH questionnaire, respectively. Pain and functional recovery significantly improved in both patients during the treatment. Further improvement was detected at the follow-up 30 days after therapy. No patient reported adverse effects related to PEAum treatment. The use of PEAum may represent an appropriate approach to promote the recovery of patients with post-operative pain, thanks to its ability to alleviate painful symptoms and improve functional recovery.

KEYWORDS: *micronized and ultramicronized PEA, wrist fracture, surgery, pain, functional recovery*

INTRODUCTION

Distal radius fractures are among the most common skeletal injuries of the wrist: they account for about 44% of all hand and forearm fractures and represent about 20% of all fractures (1). In the last decade, surgical techniques and related implants have advanced considerably. Among them, the volar plate is widely used in patients with unstable distal radius fractures, as it provides secure fixation, early post-operative mobility, and rapid recovery of wrist function (2). During post-operative rehabilitation, particularly in the immediate post-operative period, most patients experience significant pain when performing both active and passive movements (3). Surgical trauma is characterized by stiffness and suffering of bone's sensitive nerve fibers (4-6). Peripheral nerve sensitivity is regulated by mast cells in the bone whose hyperactivation, caused by surgical trauma, results in neuroinflammation associated with bone oedema and post-traumatic pain (7). Evidence on the role of mast cells in the development of bone pain suggests that therapies able to

Received: 10 May 2023
Accepted: 02 June 2023

Copyright © by LAB srl 2023

This publication and/or article is for individual use only and may not be further reproduced without written permission from the copyright holder. Unauthorized reproduction may result in financial and other penalties. Disclosure: All authors report no conflicts of interest relevant to this article.

modulate mast cell activation may represent an innovative approach. In this perspective, a possibility could be represented by Palmitoylethanolamide (PEA): an endogenous molecule belonging to the N-acylethanolamine family, which is produced “on-demand” in order to restore tissue homeostasis and which exerts its action thanks to the ALIA (“Autacoid Local Injury Antagonism”) mechanism, mediating neuroprotective, anti-inflammatory and analgesic effects through mast cell control (8).

This article describes the cases of two patients with wrist fractures who underwent volar plate surgery and were subsequently treated with PEA in its micronized and ultra-micronized form, increasing its bioavailability and biological efficacy.

MATERIALS AND METHODS

We analyzed two patients with wrist fractures who underwent surgery with reduction and fixation using a volar plate and treated with micronized (PEAm) and ultra-micronized (PEAum) PEA (Normast ® MPS, Food for Special Medical Purpose, Epitech Group SpA, Saccolongo, Padua) 300mg + 600mg, 2/daily for 30 days (2 sachets/die for the first 20 days, followed by oral tablets for the remaining 10 days).

The fracture was classified according to the AO classification: type A represents extra-articular fracture, type B partial-articular, and type C complete articular fracture.

Evaluations were performed on day 1 after surgery (T0), 7 (T1), 21 (T3) and 30 (T4) days after surgery. A subsequent follow-up was performed 30 days after the end of treatment (T5).

The parameters considered were:

- pain intensity assessed by Numeric Rating Scale (NRS), an 11-point scale where 0 represents “no pain” and 10 “the most intense pain imaginable” (9), performed at all time points;
- functional recovery through the Disabilities of the Arm, Shoulder and Hand (DASH) questionnaire, administered at T0, T3, T4 and T5. The questionnaire is divided into 3 modules: symptom/disability module consisting of 30 questions investigating aspects of daily life; occupational module and sports/recreational activities module (optional). Additional items are used for workers and individuals whose occupation or sports or recreational activity requires a high level of physical performance. Each question has 5 possible answers, from 1 (no difficulty) to 5 (unable to perform a specific activity). The sum of the individual scores results in an overall score, which is converted into a scale from 0 to 100 (100 indicates severe disability) (10).
- The safety of the treatment was monitored by collecting observed and patient-reported adverse events. Written informed consent for the data’s publication was obtained for the Declaration of Helsinki and Good Clinical Practice (GCP).

RESULTS

Case 1

A 47-year-old man with a 2R3B fracture underwent surgery for reduction and fixation with a volar plate (Fig. 1). The patient had no comorbidities or other bone related diseases and was not taking concomitant medications and other bone-related diseases. On the first day after surgery, the patient presented a pain score of 7/10 on the NRS scale.

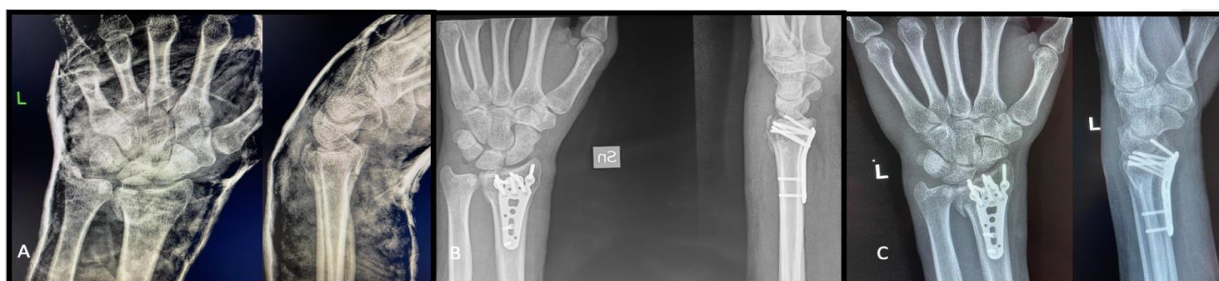


Fig. 1. Pre-operative (A); Post-operative (B); 1 month follow-up (C).

At subsequent assessments on days 7, 14 and 21 after surgery, the patient reported continuous progress in the perception of pain, which decreased to 2 points on the NRS scale after 30 days of treatment (T4), resulting clinically insignificant. This intensity was maintained at the post-treatment follow-up (Table I).

Table I. Pain and functional recovery over time.

Observation times	NRS	DASH Symptom/Disability Module
T0 – 1 st day after surgery	7	100
T1- 7 th day after surgery	6	
T2 - 14 th day after surgery	4	
T3 – 21 st day after surgery	4	49.2
T4 - 30 th day after surgery (end of treatment)	2	20.8
T5 – 30 days after end of treatment	2	9.2

The assessment of the main form of the DASH questionnaire concerning symptoms and disability showed, on the first day after surgery, total disability in performing daily activities. Twenty-one days after surgery, the questionnaire score decreased, with a further reduction at T4. At the last follow-up (T5), the patient reported a further improvement in disability (Table I). The patient completed the planned treatment with PEAm/um without taking analgesics and/or anti-inflammatories during the weeks following surgery and without reporting any side effects.

Case 2

A 58-year-old woman with a 2R3B fracture underwent surgery for reduction and fixation with a volar plate (Fig 2). The patient had no comorbidities or bone-related diseases.

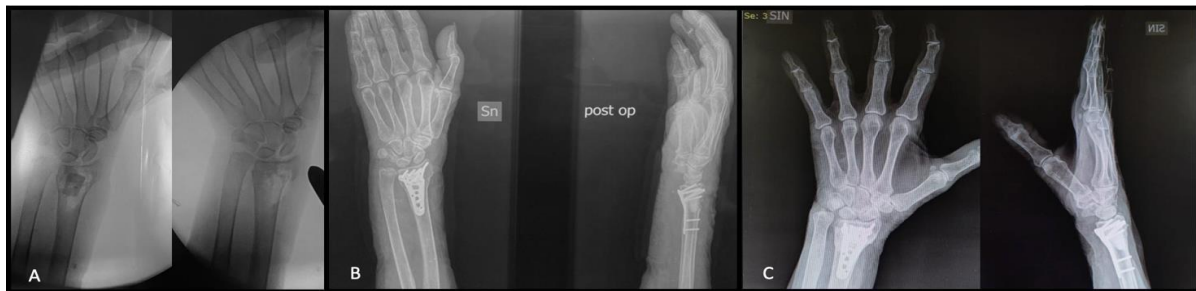

Fig. 2. Pre-operative (A); Post-operative (B); 1-month follow-up (C).

At T0, the patient presented severe pain, with an NRS score of 7/10, also reported 7 and 14 days after surgery. Twenty-one days after surgery, the patient reported an improvement in pain intensity with an NRS score of 5, which was maintained until T4. 30 days after surgery and after the end of treatment, the patient reported no more pain.

The assessment of functional recovery, carried out by filling out the main and occupational forms of the DASH questionnaire, showed a significant improvement in performing daily and occupational activities over time. Thirty days after the end of treatment, the DASH score was further reduced significantly regarding symptoms and the ability to perform various activities, including occupational ones (Table II). During the 30 days of treatment, the patient took no analgesics or anti-inflammatory drugs and reported no adverse effects.

Table II. Pain and functional recovery over time.

Observation times	NRS	DASH Symptom/Disability Module	DASH Occupational Module
T0 – 1 st day after surgery	7	83.3	93.98
T1- 7 th day after surgery	7		
T2 - 14 th day after surgery	7		
T3 – 21 st day after surgery	5	62.5	87.5
T4 - 30 th day after surgery (end of treatment)	5	39.2	62.5
T5 – 30 days after end of treatment	0	5.0	0.0

DISCUSSION

PEA’s anti-inflammatory, analgesic and neuroprotective effects have been confirmed in models of chronic inflammation and chronic and neuropathic pain: PEA was effective in preserving peripheral nerve morphology, reducing

mast cell activation and producing pro-inflammatory mediators at the site of injury; this confirms the direct intervention of PEA in the inflammatory process and pain response (11, 12).

During the treatment period with micronized/ultra-micronized PEA, both patients' post-surgical pain intensity and functional wrist recovery improved significantly. The first patient experienced almost complete pain relief at the follow-up, while the second reported a complete symptom resolution. In addition, the improvement of daily functions, observed in both patients through the Symptom/Disability Module of DASH and the Occupational Module for patient 2, was higher than the "Minimal Clinically Important Difference" reported by both the DASH website (15 points) and the literature data (10.83 points) (13, 14) at each assessment compared to the previous one.

The management of pain and the restoration of wrist function demonstrate the efficacy of this approach, which is supported by the clinically significant improvement achieved already after 21 days of treatment and at each evaluation time compared to the previous one, as well as by the further reduction of both the evaluated parameters 30 days after the end of treatment. In order to confirm these results, a larger, controlled, randomized, double-blind versus placebo study is planned.

CONCLUSIONS

Patients reported benefits after using a combination of PEAm/um in reducing pain and functional wrist recovery following a surgically treated fracture, encouraging its use as an effective, safe and well-tolerated alternative to manage post-operative bone pain.

ACKNOWLEDGEMENTS

We thank Epitech Group SpA (Saccolongo, Padua) for supplying the Food for Special Medical Purpose.

REFERENCES

1. Yao H, Zhang W, Xu W, Liu K, Xu Y. A new method to predict the outcome of the volar locked plate treatment for distal radius fracture. *BMC Musculoskelet Disord.* 2019;20(1):538. doi:https://doi.org/10.1186/s12891-019-2931-3
2. Solarino G, Vicenti G, Abate A, et al. Volar locking plate vs epibloc system for distal radius fractures in the elderly. *Injury.* 2016;47 Suppl 4(S84-S90). doi:https://doi.org/10.1016/j.injury.2016.07.056
3. Luo P, Lou J, Yang S. Pain Management during Rehabilitation after Distal Radius Fracture Stabilised with Volar Locking Plate: A Prospective Cohort Study. *Biomed Res Int.* 2018;2018(5786089). doi:https://doi.org/10.1155/2018/5786089
4. Zhao Y, Zhang H, Li N, Li J, Zhang L. Chronic Pain after Bone Fracture: Current Insights into Molecular Mechanisms and Therapeutic Strategies. *Brain Sci.* 2022;12(8):doi:https://doi.org/10.3390/brainsci12081056
5. Molfetta L, Saviola G, Fornasari D, Grossi PA, Corcione A, Frediani B. Osteoarticular pain: therapeutic approach by paradigms. *Eur Rev Med Pharmacol Sci.* 2022;26(11):4054-4068. doi:https://doi.org/10.26355/eurrev_202206_28975
6. Urso G. Le rigidità articolari: riabilitazione. *Riv Chir Mano.* 2001;38(2):170-179.
7. Ragipoglu D, Dudeck A, Haffner-Luntzer M, et al. The Role of Mast Cells in Bone Metabolism and Bone Disorders. *Front Immunol.* 2020;11(163). doi:https://doi.org/10.3389/fimmu.2020.00163
8. Petrosino S, Di Marzo V. The pharmacology of palmitoylethanolamide and first data on the therapeutic efficacy of some of its new formulations. *Br J Pharmacol.* 2017;174(11):1349-1365. doi:https://doi.org/10.1111/bph.13580
9. Haefeli M, Elfering A. Pain assessment. *Eur Spine J.* 2006;15 Suppl 1(Suppl1):S17-24. doi:https://doi.org/10.1007/s00586-005-1044-x
10. Padua R, Padua L, Ceccarelli E, et al. Italian version of the disability of the Arm, Shoulder and Hand (DASH) questionnaire. Cross-cultural adaptation and validation. *J Hand Surg Br.* 2003;28(2):179-186. doi:https://doi.org/10.1016/s0266-7681(02)00303-0
11. Paladini A, Fusco M, Cenacchi T, Schievano C, Piroli A, Varrassi G. Palmitoylethanolamide, a Special Food for Medical Purposes, in the Treatment of Chronic Pain: A Pooled Data Meta-analysis. *Pain Physician.* 2016;19(2):11-24.
12. Scarano A, Degidi M, Iezzi G, et al. Maxillary sinus augmentation with different biomaterials: a comparative histologic and histomorphometric study in man. *Implant Dent.* 2006;15(2):197-207. doi:https://doi.org/10.1097/01.id.0000220120.54308.f3
13. Franchignoni F, Vercelli S, Giordano A, Sartorio F, Bravini E, Ferriero G. Minimal clinically important difference of the disabilities of the arm, shoulder and hand outcome measure (DASH) and its shortened version (QuickDASH). *J Orthop Sports Phys Ther.* 2014;44(1):30-39. doi:https://doi.org/10.2519/jospt.2014.4893
14. Gummesson C, Atroshi I, Ekdahl C. The disabilities of the arm, shoulder and hand (DASH) outcome questionnaire: longitudinal construct validity and measuring self-rated health change after surgery. *BMC Musculoskelet Disord.* 2003;4(11). doi:https://doi.org/10.1186/1471-2474-4-11